

## ATTP 4-46.1 (FM 4-20.65)

---

---

# Processes to Support the Identification of Deceased Personnel

---

---

September 2011

**DISTRIBUTION RESTRICTION:** Distribution authorized to DOD components (DOD contractors only on a case-by-case basis) in accordance with the foreign disclosure authority, TRADOC Reg. 350-70. This determination was made on 12 April 2005. Contractor and other requests for this document must be referred to Commander, ATTN: ATSM-MA, U.S. Army Quartermaster Center and School, Fort Lee, VA 23801-1601.

**DESTRUCTION NOTICE:** Destroy by any method that must prevent disclosure of contents or reconstruction of the document.

---

---

## Headquarters, Department of the Army

---

---

**This publication is available at  
Army Knowledge Online ([www.us.army.mil](http://www.us.army.mil))  
and the General Dennis J. Reimer  
Training and Doctrine Digital Library at  
([www.train.army.mil](http://www.train.army.mil))**

Army Tactics, Techniques, and Procedures  
 No. 4-46.1 (FM 4-20.65)

Headquarters  
 Department of the Army  
 Washington, D.C., 20 September 2011

# Processes to Support the Identification of Deceased Personnel

## Contents

		Page
	<b>PREFACE .....</b>	<b>viii</b>
	<b>ACKNOWLEDGEMENTS.....</b>	<b>ix</b>
<b>Chapter 1</b>	<b>THE IDENTIFICATION PROCESS AND MORTUARY PROTOCOLS.....</b>	<b>1-1</b>
	Background .....	1-1
	Responsibilities.....	1-1
	Examining and Recording Data.....	1-1
	Identifying Media .....	1-2
<b>Chapter 2</b>	<b>BASIC GROSS HUMAN ANATOMY .....</b>	<b>2-1</b>
	Objective.....	2-1
	Glossary of Anatomical Terminology.....	2-1
	Major Internal Organs.....	2-3
<b>Chapter 3</b>	<b>ANTEMORTEM AND PERIMORTEM TRAUMA.....</b>	<b>3-1</b>
	Objective.....	3-1
	Wounds and Injuries.....	3-1
	Asphyxia .....	3-18
	Drowning .....	3-19

---

**Distribution Restriction:** Distribution authorized to DOD components (DOD contractors only on a case-by-case basis) in accordance with the foreign disclosure authority, TRADOC Reg. 350-70. This determination was made on 12 April 2005. Contractor and other requests for this document must be referred to Commander, ATTN: ATSM-MA, U.S. Army Quartermaster Center and School, Fort Lee, VA 23801-1601.

**DESTRUCTION NOTICE:** Destroy by any method that must prevent disclosure of contents or reconstruction of the document.

**\*This publication supersedes FM 4-20.65, 27 July 2005.**

**Contents**

---

<b>Chapter 4</b>	<b>HUMAN OSTEOLOGY .....</b>	<b>4-1</b>
	Objective .....	4-1
	Glossary of Osteological Terminology .....	4-1
	Adult Human Skeleton .....	4-4
	Adult Postcranial Skeleton .....	4-9
	Fetal and Immature Skeleton .....	4-22
<b>Chapter 5</b>	<b>DENTAL ANATOMY AND MORPHOLOGY .....</b>	<b>5-1</b>
	Objective .....	5-1
	Glossary of Odontological and Anatomical Terminology .....	5-1
	Tooth Surfaces .....	5-3
	Teeth Classification .....	5-4
	Universal Numbering System .....	5-5
	Deciduous Dentition .....	5-6
	Permanent Dentition .....	5-7
	Dental Caries .....	5-10
	Dental Restorations .....	5-11
	Dental Anomalies .....	5-13
<b>Chapter 6</b>	<b>BASIC MEDICOLEGAL DEATH INVESTIGATION .....</b>	<b>6-1</b>
	Objective .....	6-1
	Medicolegal Death Investigation During Combat .....	6-1
	Introduction .....	6-2
	Role of the Medicolegal Death Investigator .....	6-3
<b>Chapter 7</b>	<b>EXAMINATION OF FLESHED REMAINS .....</b>	<b>7-1</b>
	Objective .....	7-1
	Scope of the Autopsy .....	7-1
	Forensic Autopsy Procedures .....	7-2
<b>Chapter 8</b>	<b>PRIMARY IDENTIFICATION OF REMAINS .....</b>	<b>8-1</b>
	Objective .....	8-1
	Dental Identification .....	8-1
	Fingerprints .....	8-5
	Fingerprinting Procedures .....	8-8
	Footprinting .....	8-18
	Deoxyribonucleic Acid (DNA) .....	8-18
<b>Chapter 9</b>	<b>EXAMINATION OF SKELETAL REMAINS .....</b>	<b>9-1</b>
	Objective .....	9-1
	Forensic Anthropology .....	9-1
	Basic Laboratory Techniques .....	9-2
	Estimation of Skeletal Age .....	9-2
	Determination of Adult Sex .....	9-9
	Determination of Race .....	9-12
	Estimation of Stature .....	9-13
	Individualization .....	9-15
	Video Superimposition and Facial Reconstruction .....	9-16
<b>Appendix A</b>	<b>PREPARATION OF DD FORM 890 .....</b>	<b>A-1</b>
<b>Appendix B</b>	<b>PREPARATION OF DA FORM 4137 .....</b>	<b>B-1</b>

<b>Appendix C</b>	<b>EVIDENCE COLLECTION AND PACKAGING GUIDE .....</b>	<b>C-1</b>
	<b>GLOSSARY .....</b>	<b>Glossary-1</b>
	<b>REFERENCES .....</b>	<b>References-1</b>
	<b>INDEX.....</b>	<b>Index-1</b>

## Figures

Figure 2-1. Anatomical Position .....	2-1
Figure 2-2. Anatomical Planes .....	2-2
Figure 2-3 Directional Terms .....	2-3
Figure 2-4. The Brain, Gross, Lateral View .....	2-4
Figure 2-5. The Brain, Gross, Superior View .....	2-4
Figure 2-6. Diagram of the Lobes of the Brain .....	2-4
Figure 2-7. The Lungs, Gross, Lateral View .....	2-5
Figure 2-8. The Heart, Diagram of Exterior Structures .....	2-6
Figure 2-9. The Heart, Gross, Anterior.....	2-6
Figure 2-10. The Heart, Gross, Posterior.....	2-6
Figure 2-11. The Liver, Gross, Superior View.....	2-7
Figure 2-12. The Gallbladder, Gross.....	2-8
Figure 2-13. Upper Abdominal Viscera, Gross, Anterior View.....	2-8
Figure 2-14. The Pancreas, Gross.....	2-9
Figure 2-15. The Spleen, Anterior Border, Gross .....	2-9
Figure 2-16. The Kidneys, Cross Section, Gross, with Abdominal Aorta .....	2-10
Figure 2-17. The Urinary Tract, Gross, Kidneys, Ureters, and Bladder.....	2-10
Figure 2-18. The Esophagus and Stomach, Gross.....	2-11
Figure 2-19. The Large and Small Intestines, Gross .....	2-13
Figure 2-20. The Appendix, Gross .....	2-13
Figure 3-1. Cross Section of the Structures of the Skin.....	3-1
Figure 3-2. First Degree Burn.....	3-2
Figure 3-3. Second Degree Burn .....	3-2
Figure 3-4. Third Degree Burn .....	3-3
Figure 3-5. Fourth Degree Burn .....	3-3
Figure 3-6. Rule of Nines .....	3-4
Figure 3-7. Friction Abrasion, the Abdomen .....	3-5
Figure 3-8. Pattern Abrasion on Lower Leg that Matches a Screw-type Bolt and Washer Attached to the License Plate of a Car.....	3-6
Figure 3-9. Contusion.....	3-6
Figure 3-10. Laceration .....	3-7
Figure 3-11. Tapping Fracture, Femur .....	3-8
Figure 3-12. Crush Fracture, Calf (Tibia and Fibula) .....	3-8
Figure 3-13. Angulation Fracture.....	3-9

**Contents**

---

Figure 3-14. Rotational Fracture .....	3-9
Figure 3-15. Compression Fracture .....	3-9
Figure 3-16. Depression Fractures .....	3-10
Figure 3-17. Circular Fracture .....	3-11
Figure 3-18. Stellate Fracture .....	3-11
Figure 3-19. Stab Wound to Skin Tissue .....	3-12
Figure 3-20. Incised Wound .....	3-13
Figure 3-21. Hesitation Marks to the Wrist .....	3-13
Figure 3-22. Chop Wound .....	3-14
Figure 3-23. Stellate Gunshot Entrance Wound .....	3-15
Figure 3-24. Contact Gunshot Wound (Left) and the Muzzle of the Weapon (Right) .....	3-15
Figure 3-25. Near Contact Gunshot Wound .....	3-16
Figure 3-26. Intermediate Gunshot Wound .....	3-16
Figure 3-27. Distant Gunshot Wound, Entrance .....	3-17
Figure 3-28. Exit Wounds to Skin Tissue .....	3-17
Figure 3-29. Gunshot Entrance Wound .....	3-18
Figure 3-30. Gunshot Exit Wound .....	3-18
Figure 4-1. Diaphysis and Epiphyses of the Right Humerus .....	4-2
Figure 4-2. Fontanelles .....	4-3
Figure 4-3. The Human Skeleton .....	4-5
Figure 4-4. The Skull, Frontal View .....	4-6
Figure 4-5. The Skull, Right Lateral View .....	4-6
Figure 4-6. The Cranium, Superior View .....	4-6
Figure 4-7. The Cranium, Inferior View .....	4-7
Figure 4-8. The Hyoid Bone .....	4-9
Figure 4-9. The Vertebral Column .....	4-9
Figure 4-10. The Atlas, C1, Superior View .....	4-10
Figure 4-11. The Axis, C2, Superior View .....	4-10
Figure 4-12. The Seventh Cervical Vertebra, Superior View .....	4-10
Figure 4-13. Typical Cervical Vertebra, Superior View .....	4-11
Figure 4-14. Typical Thoracic Vertebra, Lateral View .....	4-11
Figure 4-15. Typical Thoracic Vertebra, Superior View .....	4-11
Figure 4-16. Typical Lumbar Vertebra, Lateral View .....	4-11
Figure 4-17. Typical Lumbar Vertebra, Superior View .....	4-11
Figure 4-18. The Sternum, Anterior View .....	4-12
Figure 4-19. A Typical Rib (Left) .....	4-13
Figure 4-20. The First Right Rib, Superior View .....	4-13
Figure 4-21. The Left Scapula, Anterior Surface .....	4-14
Figure 4-22. The Left Scapula, Posterior Surface .....	4-14
Figure 4-23. The Left Clavicle .....	4-14
Figure 4-24. The Right Humerus, Anterior View .....	4-15

Figure 4-25. The Right Humerus, Posterior View .....	4-15
Figure 4-26. The Right Radius, Anterior View.....	4-16
Figure 4-27. The Right Radius, Posterior View.....	4-16
Figure 4-28. The Right Ulna, Lateral View .....	4-16
Figure 4-29. The Right Ulna, Anterior View .....	4-17
Figure 4-30. The Left Hand, Dorsal View.....	4-17
Figure 4-31. The Sacrum, Ventral View .....	4-18
Figure 4-32. The Sacrum and Coccyx, Dorsal View .....	4-18
Figure 4-33. The Right Os Coxa Lateral View .....	4-19
Figure 4-34. The Left Os Coxa, Medial View .....	4-19
Figure 4-35. The Left Femur, Anterior View.....	4-20
Figure 4-36. The Right Femur, Posterior View.....	4-20
Figure 4-37. The Right Patella, Ventral View .....	4-20
Figure 4-38. The Right Patella, Dorsal View .....	4-20
Figure 4-39. The Right Tibia, Posterior View .....	4-21
Figure 4-40. The Right Tibia, Anterior View .....	4-21
Figure 4-41. The Right Fibula, Dorsal View .....	4-21
Figure 4-42. The Right Fibula, Medial View .....	4-21
Figure 4-43. The Right Foot, Dorsal View.....	4-22
Figure 4-44. The Fetal Skeleton.....	4-23
Figure 4-45. From Left to Right: Fetal Femur Diaphysis; Juvenile Femur with Appearance of Epiphyses; Adolescent Femur; Subadult Femur; Subadult Femur; Adult Femur .....	4-23
Figure 5-1. Tooth Anatomy.....	5-3
Figure 5-2. Tooth Surfaces.....	5-4
Figure 5-3. Classification of Deciduous Dentition .....	5-5
Figure 5-4. Classification of the Permanent Dentition (Maxillary) .....	5-5
Figure 5-5. Maxillary Permanent Dentition .....	5-6
Figure 5-6. Mandibular Permanent Dentition .....	5-6
Figure 5-7. Deciduous Dentition.....	5-6
Figure 5-8. Maxillary Right Central Incisor .....	5-7
Figure 5-9. Maxillary Right Lateral Incisor.....	5-7
Figure 5-10. Maxillary Left Canine/Cuspid .....	5-8
Figure 5-11. Maxillary Left First Premolar/Bicuspid .....	5-8
Figure 5-12. Maxillary Left Second Premolar/Bicuspid .....	5-8
Figure 5-13. Mandibular Right First Molar.....	5-9
Figure 5-14. Mandibular Left Second Molar .....	5-9
Figure 5-15. Mandibular Right Third Molar .....	5-10
Figure 6-1. Floor Plan Method.....	6-7
Figure 6-2. Exploded/Cross-projection Method.....	6-8
Figure 6-3. Triangulation Method .....	6-8
Figure 7-1. The Life Cycle of the Blowfly.....	7-7

**Contents**

---

Figure 8-1. Periapical Radiograph .....	8-3
Figure 8-2. Bitewing Radiographs .....	8-3
Figure 8-3. Panoramic Radiograph.....	8-3
Figure 8-4. Cross Section of Friction Ridge Skin.....	8-6
Figure 8-5. Plain Arch Pattern.....	8-6
Figure 8-6. Tented Arch Patterns, Type With an Angle.....	8-7
Figure 8-7. Tented Arch Patterns, Type With an Upthrust .....	8-7
Figure 8-8. Tented Arch Patterns, Type Resembling the Loop .....	8-7
Figure 8-9. Loop Pattern .....	8-7
Figure 8-10. Plain Whorl .. .....	8-8
Figure 8-11. Central Pocket Loop Whorl .....	8-8
Figure 8-12. Double Loop Whorl.....	8-8
Figure 8-13. Accidental Whorl.....	8-8
Figure 8-14. Fingerprint Identification Kit.....	8-9
Figure 8-15a. Folding and Placing DD Form 894 in Tabletop Cardholder .....	8-11
Figure 8-15b. Information Block.....	8-11
Figure 8-15c. Positioning in Cardholder .....	8-12
Figure 8-16a. Inking Finger.....	8-12
Figure 8-16b. Printing Rolled Impression .....	8-12
Figure 8-17. Using the Shovel-type Cardholder .....	8-12
Figure 8-18. Folding and Placing Fingerprint Chart in Shovel-type Cardholder, Step 1 .....	8-13
Figure 8-19. Folding and Placing Fingerprint Chart in Shovel-type Cardholder, Steps 2 and 3.....	8-13
Figure 8-20. Folding and Placing Fingerprint Chart in Shovel-type Cardholder, Step 4 .....	8-13
Figure 8-21. Injecting Finger With Tissue Builder.....	8-14
Figure 8-22. Making Deep Cut at Second Joint to Straighten Finger.....	8-15
Figure 8-23. Removing Pattern Area From First Joint.....	8-16
Figure 8-24. The Double Helix .....	8-20
Figure 8-25. Eligible Donors of mtDNA Samples.....	8-21
Figure 9-1. Phase 0 .....	9-7
Figure 9-2. Phase 1 .....	9-7
Figure 9-3. Phase 4 .....	9-8
Figure 9-4. Phase 6 .....	9-8
Figure 9-5. Phase 8 .....	9-8
Figure 9-6. Pelvic Elements .....	9-9
Figure 9-7. Female Pelvis .....	9-10
Figure 9-8. Male Pelvis .....	9-10
Figure 9-9. Male Pelvic Traits, Female Pelvis Traits .....	9-10
Figure 9-10. Basic Male and Female Cranial Morphology .....	9-11
Figure 9-11. Male Cranial Morphology .....	9-11
Figure 9-12. Female Cranial Morphology .....	9-11
Figure 9-13. Measuring the Maximum Diameter of the Femur Head .....	9-12



Figure 9-14. Cranial Landmarks.....	9-13
Figure 9-15. Measuring the Femur on the Osteometric Board .....	9-14
Figure A-1. DD Form 890 .....	A-2
Figure B-1. DA Form 4137 (Front) .....	B-2
Figure B-2. DA Form 4137 (Back).....	B-3
Figure C-1. Seal the Package With Evidence Tape.....	C-1
Figure C-2. Druggist's Fold .....	C-4

## Tables

Table 9-1. Estimation of Immature Remains From Epiphyseal Union .....	9-5
Table 9-2. Aging Rules Related to the Suchey-Brooks Pubic Age Determination System .....	9-7
Table 9-3. Male and Female Pelvic Traits.....	9-10
Table 9-4. Basic Male and Female Cranial Morphology .....	9-11
Table 9-5. Sex Estimation Using the Humerus and Femur.....	9-12
Table 9-6. Race Characteristics of the Skull .....	9-13
Table 9-7. Equations to Estimate Living Stature (cm) for Individuals Between 18 and 30 Years With Standard Errors From the Long Bones .....	9-14

## Preface

The mortuary affairs specialist (MOS 92M) performs or supervises duties relating to deceased personnel to include recovery, collection, evacuation, establishment of tentative identification, and temporary burial. They also inventory, safeguard, and evacuate personal effects of deceased personnel.

This FM addresses the basic procedures and methodologies used in processing human remains to support the final identification of deceased military and civilian personnel. It pertains to all remains processed through U.S. Army facilities during peacetime and wartime, both past and present.

Because of the complexity of the subject matter, procedures for identifying remains cannot be prescribed or standardized. The classification of remains—recent, decomposed, semiskeletal, or skeletal—will dictate the procedures that will be employed. However, this manual details standard identification procedures used by forensic experts to arrive at a final identification for remains processed regardless of classification.

This FM begins with discussions of basic gross human anatomy, antemortem and perimortem trauma, human osteology, and dental anatomy and morphology. These chapters provide the mortuary affairs specialist with the basic knowledge to proficiently assist human identification specialists (such as the forensic pathologist, medical examiner, forensic odontologist, and forensic anthropologist). The mortuary affairs specialist will not perform any task associated with the identification of human remains unless directed by and under the direct supervision of the forensic specialist.

Chapter 6 is a response to the AFMES policy that treats each battlefield fatality as a forensic MDI. This chapter provides the mortuary affairs specialist with the knowledge of medical, legal, and scientific standards to ensure that all crucial forensic evidence is preserved and documented in compliance with MDI standards during the 92M mission of search, recovery, evacuation, and tentative identification of remains.

Because the mortuary affairs specialist frequently plays a supporting role to the medical profession both in CONUS and OCONUS, this FM ends with discussions on the procedures used by human identification experts (forensic pathologist, medical examiner, forensic odontologist, fingerprints expert, DNA expert, and forensic anthropologist) to identify human remains.

The scope and depth of this FM will make it useful to every mortuary affairs specialist, regardless of location. This manual enables the reader to become conversant in the basic procedures and methodologies used by identification specialists in identifying deceased military and civilian personnel.

This publication applies to the Active Army, the Army National Guard (ARNG)/Army National Guard of the United States (ARNGUS), and the United States Army Reserve (USAR) unless otherwise stated.

The proponent of this publication is the United States Army Training and Doctrine Command (TRADOC). Send comments and recommendations on DA Form 2028 (Recommended Changes to Publications and Blank Forms) directly to—

Commander  
U.S. Army Quartermaster Center and School  
ATTN: ATSM-MA  
Fort Lee, Virginia 23801-1601

## Acknowledgements

The copyright owners listed below have granted permission to reproduce their material.

The following figures are courtesy of Dr. Wesley Norman: Figure 2-2.

The following figures are courtesy of Ms. Jeananda Col: Figure 2-6 and Figure 5-1.

The following figure is courtesy of Patrick J. Lynch, M.S.: Figure 2-8.

The following figure is courtesy of Kelly J. Roberts: Figure 3-1.

The following figures are courtesy of Dr. Edward Klatt: Figure 3-19 and Figure 3-23.

The following figures are courtesy of Daniel Maidman: Figure 4-4 and Figure 4-5.

The following figures are courtesy of Dr. Andrew M. Sklar: Figure 8-1, Figure 8-2, and Figure 8-3.

**This page intentionally left blank.**

## Chapter 1

# THE IDENTIFICATION PROCESS AND MORTUARY PROTOCOLS

## BACKGROUND

1-1. The process of identifying a deceased person begins when remains are recovered. Information from witnesses, the decedent's unit, and recovery personnel is documented by the mortuary affairs specialist. This information accompanies the remains to either the CONUS or OCONUS mortuary where it becomes part of the decedent's case file.

## RESPONSIBILITIES

1-2. The mortuary affairs specialist must ensure that all accompanying documentation is accurate and complete.

1-3. The CMAOC (U.S. Army Human Resources Command, under the general staff supervision of the United States Army Adjutant General Directorate) has Army staff responsibility for the care and disposition of remains.

1-4. The deputy chief of staff of logistics (G-4) is responsible for the search, recovery, evacuation, tentative identification, processing, and/or temporary interment of remains in theaters of operations.

1-5. The commander, United States Army Human Resources Command, exercises staff supervision and administers phases of the Army Mortuary Affairs Program. (Specific responsibilities are outlined in AR 638-2, paragraph 1-4d.)

1-6. The responsibilities of commanders of major Army commands and major subordinate commands, casualty area commanders, adjutant generals, directors of logistics in commands located outside the United States, and heads of other organizations with responsibilities for the care and disposition of remains and personal effects are found in AR 638-2, paragraph 1-4e-j.

1-7. U.S. Code, Title 10—Armed Forces, Subtitle A, Part II, Chapter 75, Subchapter 1, Section 1471 (forensic pathology investigations) defines the authority of the Armed Forces Medical Examiner to conduct a forensic pathology investigation to determine the cause or manner of death of a deceased individual. The investigation may include an autopsy of the decedent's remains.

1-8. Department of Defense Directive 5154.24, "Armed Forces Institute of Pathology (AFIP)," defines the mission, organization, management, responsibilities, functions, relationships, and authorities of the AFIP. A significant portion of this directive provides authority for the AFIP, through the Office of the Armed Forces Medical Examiner, to conduct autopsies and to identify military dead.

## EXAMINATING AND RECORDING DATA

1-9. Personnel engaged in processing operations must carefully examine and record exactly all identification data associated with a remains. They must also preserve all identifying media. These tasks are vital to final identification. Any item received with remains that may furnish information that will lead to or confirm identification is completely described and recorded on DD Form 890 (Record of Identification Processing – Effects and Personal Data) (refer to appendix A).

**Chapter 1**

---

**INDIVIDUAL CLOTHING AND EQUIPMENT**

1-10. All items of individual clothing and equipment are carefully examined for clues that may be used in the identification process.

1-11. All markings on clothing are examined visually. Clothing may be examined under an alternate light source (a nonlaser based forensic light system) for evidence that is faint or not readily visible. Alternate light sources have been used successfully for locating and photographing latent fingerprints, body fluids, and other trace evidence (such as fibers, hair, gunshot residue, bone, and ink).

1-12. Official identification attached to the remains—such as DD Form 1380 (U.S. Field Medical Card)—is examined. Any discrepancies in information are entered on processing records. Identification tags are imprinted in the space provided on DD Form 890. The identification tag is attached to the remains in such a manner that will not forensically compromise the remains. The DD Form 1380 is attached to the case papers.

1-13. Military equipment is examined for identification numbers assigned to the equipment. A complete description of the equipment and the numbers assigned to the items are recorded. During this process, leave equipment on the remains in its original position. Remove only those items of equipment which are dangerous—such as weapons, ammunition, and explosives. All other items will accompany the remains.

1-14. Military records are carefully examined. The name, grade, social security number, and/or other data pertinent to the deceased are recorded.

1-15. All weapons and ammunition will be withdrawn and turned in to supply channels.

1-16. Organizational clothing will not be removed in the field.

**PERSONAL EFFECTS**

1-17. Procedures for disposing of personal effects of deceased and missing personnel are found in AR 638-2 and DA Pamphlet 638-2.

**IDENTIFYING MEDIA**

1-18. Certain categories of identifying media are acceptable to mortuary affairs personnel for the initial association of remains with specific fatalities. These media are not, however, considered conclusive for final identification.

**SINGLE-ITEM MEDIA**

1-19. DD Form 1380 from around the neck, in the pockets, or elsewhere on the deceased.

1-20. An identification bracelet found on the wrist.

1-21. An official identification card found on the deceased (for example, the CAC).

---

*Note.* Visual recognition of remains must be done with extreme deliberation and care. The identification must be based upon a close and direct examination of the remains by a person or persons who knew the decedent well (roommate, squad leader, close friend). The certification of this examination is recorded on DD Form 565 (Statement of Recognition of Deceased).

---

## COLLECTIVE MEDIA

1-22. When facts concerning the date, location, and unit of assignment of the deceased agree with a known casualty record, the facts, combined with one or more of the following means of identification, are used as the basis for the presumptive association of a remains with a fatality:

- Motor vehicle operator's permit.
- Personal papers and letters, such as credit cards, a marriage certificate, a will, money orders, and unofficial identification cards.
- Engraved jewelry.
- Information obtained from local officials and residents.

## INCONCLUSIVE MEDIA

1-23. Media other than that listed under single-item media and collective media above are insufficient for presumptive identification.

1-24. However, all records applicable to the deceased must bear the BTB identity, and information recorded on the records must support the BTB identity of the remains.

## CHAIN OF CUSTODY

1-25. When remains are received, in-processing personnel verify the information, sign the receipt, and enter the information in a facility/mortuary register. Each remains is assigned a processing number and tagged accordingly. An embossed or hand printed identification tag is attached to the human remains pouch containing the remains. All items (personal effects, identifying media) associated with the remains are properly tagged and recorded. Proper documentation of remains and items is essential to maintain chain of custody. Chain of custody provides a record of individuals who had original custody (possession) of the remains and items, to whom the remains and items were transferred, the date(s) of transfer(s), and where the remains and items were secured. Chain of custody provides accountability and ensures the integrity of the remains and items. (Appendix B provides instructions for completing DA Form 4137 [Evidence/Property Custody Document].)

- Examine clothing (refer to paragraphs 1-11 through 1-17) and record data on DD Form 890.
- Examine remains for identifying media and record data on DD Form 890.
- Examine remains for scars, tattoos, or other identifying marks/characteristics. Record data on DD Form 890.
- Photograph the remains. Photographs include, but are not limited to—
  - Scars, tattoos, bone malformations, healed fractures, abnormal tooth formations, and wounds.
  - Full face and profile views of current remains.
  - Fingerprints.
  - Personal effects bearing identification data.
  - Results of findings under the alternate light source.

1-26. Chart dental remains on a dental chart only when directed by and under the direct supervision of a medical examiner. Use the dental chart provided by the medical examiner. Ensure that the chart is complete, accurate, and detailed. Record defects and restorations, wear, alignment, dentures, and bridges.

1-27. Chart skeletal remains on a skeletal chart only when directed by and under the direct supervision of the medical examiner. In this instance use the chart directed by the medical examiner. The remains are laid out in anatomical order. Record missing skeletal elements or portions of elements. Record type and location of fractures, deformities, and trauma. In recording skull fractures, it should be noted that three views of the skull are typically illustrated. Therefore, skull fractures affecting more than one view of the skull should be recorded to present a clear picture of the extent of injury. For example, a fracture radiating

**Chapter 1**

---

from the left parietal bone across the frontal bone and ending in the right parietal bone must be shown on all three views of the skull.

1-28. Complete an anatomical chart only when directed by and under the direct supervision of the medical examiner. In this instance use the chart directed by the medical examiner. The condition of the remains is indicated in the space provided on the form. An accurate description is recorded of all identifying media, such as tattoos, scars, birthmarks, deformities, wounds, healed fractures, and injuries to include the exact location of these features on the remains. Photograph any distinctive characteristics.

1-29. Record fingerprints on the fingerprint chart only when directed by and under the direct supervision of the medical examiner. In this instance use the chart directed by the medical examiner. All remains are fingerprinted, if possible, regardless of other identifying media present. Record impressions of all digits that will give a legible print.

1-30. Request that the director, CMAOC, provide medical and dental records of deceased personnel.

1-31. Ensure that all information on DD Form 890 and dental, skeletal, and anatomical charts is accurate to aid in identifying the deceased.

1-32. All available supporting documents must accompany remains to the processing facility. Examples of supporting documents most frequently used include, but are not limited to, DD Form 1380; DD Form 565; DA Form 2773 (Statement of Identification); DD Form 890; SF 600 (Medical Record – Chronological Record of Medical Care); and dental, skeletal, anatomical, and fingerprint charts. Any additional pertinent supporting documents may also accompany remains.

1-33. Submit documentation to proper authorities for approval and signatures as required.

1-34. Ensure that the chain of custody is signed when remains and personal effects are transferred at time of disposition.



## Chapter 2

# BASIC GROSS HUMAN ANATOMY

### OBJECTIVE

2-1. To provide the mortuary affairs Soldier with a basic knowledge of human anatomy to assist identification specialists with autopsies of fleshed remains.

### GLOSSARY OF ANATOMICAL TERMINOLOGY

2-2. Anatomists and anthropologists use standardized anatomical terminology to describe the human body and facilitate unambiguous communication among practitioners and researchers.

### ANATOMY

2-3. Anatomy is the study of the structure of the body and the relationship of its parts to each other. The term "anatomy" has a Greek origin that means "to cut up" or "to dissect."

- Gross anatomy. Gross anatomy deals with the naked-eye appearance of tissues and organs.
- Histology/microscopic histology. Histology is the branch of anatomy/biology that deals with the minute structure of tissues, including the study of cells and organs.

### ANATOMICAL POSITION

2-4. All descriptions of the human body are based on the assumption that the person is upright and facing forward with the hands at the sides and the face, feet, and palms directed forward and the thumbs pointed away from the body (figure 2-1). The long bones are not crossed. The various parts of the body are then described in relation to imaginary planes. Understanding these planes will facilitate learning terms related to the position of structures relative to each other.

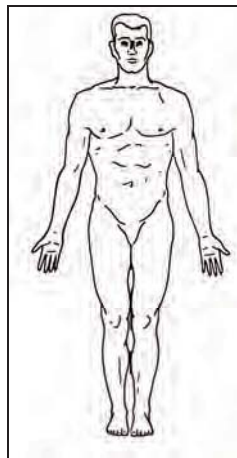


Figure 2-1. Anatomical Position

**Chapter 2****ANATOMICAL PLANES**

2-5. Coronal (or frontal). This plane divides the body into symmetrical anterior (front) and posterior (back) halves. The coronal plane is perpendicular to the sagittal plane (see figure 2-2.)

2-6. Sagittal (or median). This plane separates the body into symmetrical right and left halves.

2-7. Horizontal (or transverse). This plane divides the body into superior (upper) and inferior (lower) parts. Unlike the coronal and sagittal planes, this plane can pass through the body at any height.

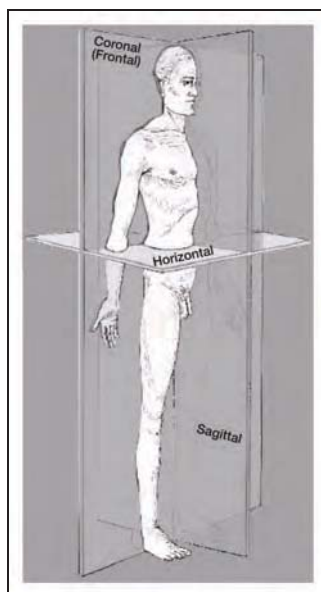


Figure 2-2. Anatomical Planes<sup>1</sup>

**APPENDICULAR SKELETON**

2-8. The appendicular skeleton includes the bones of the arms, legs, shoulder girdle, and pelvic girdle.

**AXIAL SKELETON**

2-9. The axial skeleton includes the bones of the head, vertebrae, ribs, and sternum.

**TERMS OF DIRECTION OR RELATION FOR THE BODY AND THE SKELETON**

2-10. See figure 2-3 for the following directional terms:

- Superior. Toward the head. Reference point is the horizontal plane.
- Inferior. Away from the head. Reference point is the horizontal plane.
- Anterior (or ventral). Toward the front of the body. Reference point is the coronal plane.
- Posterior (or dorsal). Toward the back of the body. Reference point is the coronal plane.
- Medial. Toward the midline. Reference point is the sagittal plane.
- Lateral. Away from the midline. Reference point is the sagittal plane.

<sup>1</sup> Dr. Wesley Norman

- Proximal. Nearest the axial skeleton or closer to the origin of a structure, near the trunk or head. A term usually used for the limb bones. For example, the head of the humerus is the proximal end.
- Distal. Farthest from the axial skeleton or further away from the origin of a structure. A term usually used for the limb bones. For example, the distal humerus articulates with the (proximal) ulna and radius.
- Palmar. The palm side of the hand, also known as volar.
- Plantar. The sole of the foot, also known as volar.
- Dorsal. The back side of the body, also known as posterior. The term “dorsal” also refers to the top of the foot and the back of the hand.
- Endocranial. The inner surface of the cranial vault.
- Ectocranial. The outer surface of the cranial vault.
- Supine. Lying on the back with the face up.
- Prone. Lying on anterior surface of the body (stomach) with face down.

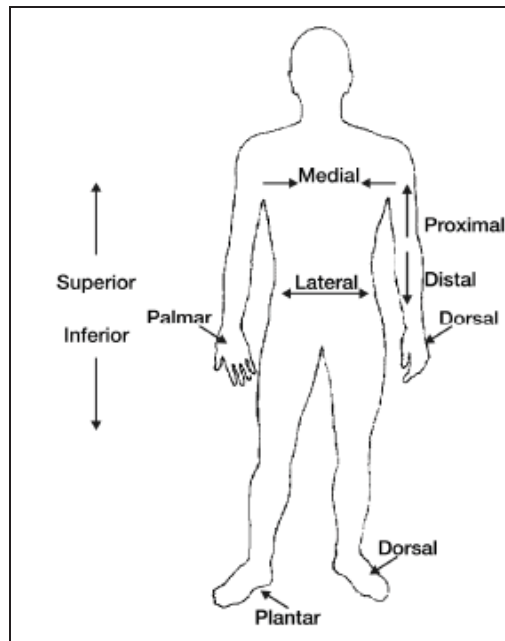


Figure 2-3. Directional Terms

## MAJOR INTERNAL ORGANS

### THE BRAIN

2-11. The brain (figure 2-4 and figure 2-5) and the spinal cord make up the central nervous system. From the outside, the brain appears as three distinct but connected parts—the cerebrum, the cerebellum, and the medulla oblongata (the brain stem).

## Chapter 2

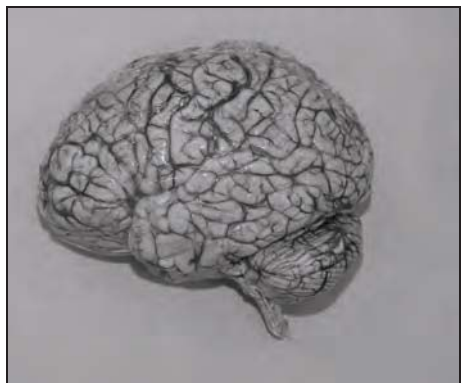


Figure 2-4. The Brain, Gross, Lateral View

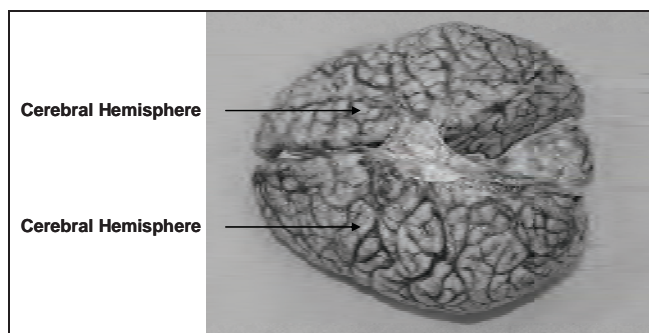
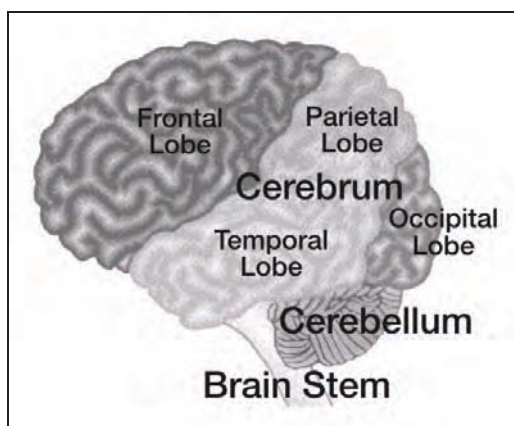


Figure 2-5. The Brain, Gross, Superior View

2-12. The cerebrum (figure 2-6) is the largest part of the brain and consists of two cerebral hemispheres. The hemispheres are divided by a deep split (fissure). Each hemisphere is large and basically a mirror image of the other. They extend from the frontal bone to the occipital bone. The surface of each hemisphere, the cortex, is composed of gray matter. The cerebral cortex is made of outward folds (gyri) separated by fissures/inward folds (sulci).

2-13. The sulci subdivide each hemisphere into lobes. The lobes correspond to the bone of the cranium under which they lay—the frontal lobe, the parietal lobes, the temporal lobes, and the occipital lobe.

Figure 2-6. Diagram of the Lobes of the Brain<sup>2</sup>

2-14. The cerebellum (figure 2-6) is located at the base of the skull, beneath the occipital lobes. Like the cerebrum, the surface layer is composed of gray matter (cortex). The cerebellum has a central portion (vermis) and two side portions (hemispheres).

2-15. The medulla oblongata (figure 2-4 and figure 2-6) is conical in shape and is the lowest portion of the brain stem. It connects the brain and the spinal cord. The medulla oblongata has a central core, also known as the spinal bulb, which gradually becomes the spinal cord exiting the skull through the foramen magnum in the occipital bone.

<sup>2</sup> Enchanted Learning, Ms. Jeananda Col

2-16. Three protective membranes—meninges—surround the brain. The outermost membrane, the dura mater, is the toughest and thickest. Below the dura mater is a middle membrane, the arachnoid layer. The pia mater, the innermost membrane, consists mainly of small blood vessels and closely follows the contours of the surface of the brain.

## **THE LUNGS**

2-17. The two lungs—one on each side of the sternum—are soft, spongy, and elastic (figure 2-7). They are protected by the ribs. The external surface is smooth and is covered with a thin membrane (visceral pleura). Each lung is conical in shape and consists of an apex, a base, three borders, and two surfaces.



**Figure 2-7. The Lungs, Gross, Lateral View**

2-18. The apex (superior surface) is blunt and broad and projects upward about 1 inch above the clavicle. The base (inferior surface) is broad, concave, and rests on the surface of the diaphragm. Each lung has an anterior, inferior, and posterior border. The anterior surface (the costal surface) corresponds to the chest wall and is convex. The posterior surface (mediastinal) is concave.

2-19. The right lung is slightly larger than the left lung. The right lung is divided into three lobes: the superior, middle, and inferior lobes. The left lung is divided into two lobes: the upper and lower lobes.

## **THE HEART**

2-20. The average adult heart (figure 2-8, figure 2-9, and figure 2-10) is a fist-sized muscular organ that weighs between 7 and 15 ounces. The heart is pyramidal in shape with an apex that is directed downward and forward. The base of the heart is the posterior surface. The heart is located in the middle of the chest between the lungs—behind and slightly left of the sternum. It is surrounded by a fluid sac called the pericardium.

## Chapter 2

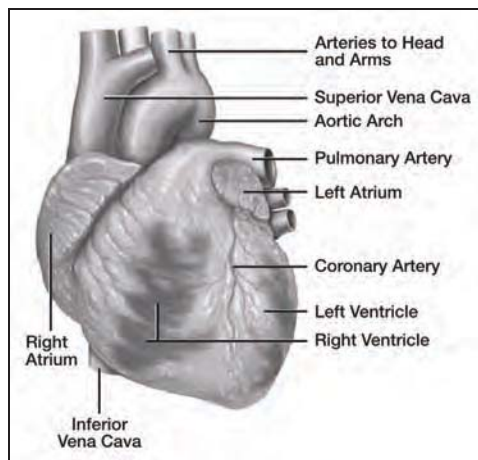
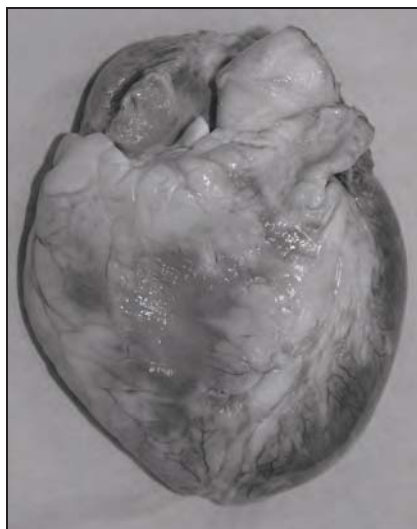
Figure 2-8. The Heart, Diagram of Exterior Structures<sup>3</sup>

Figure 2-9. The Heart, Gross, Anterior

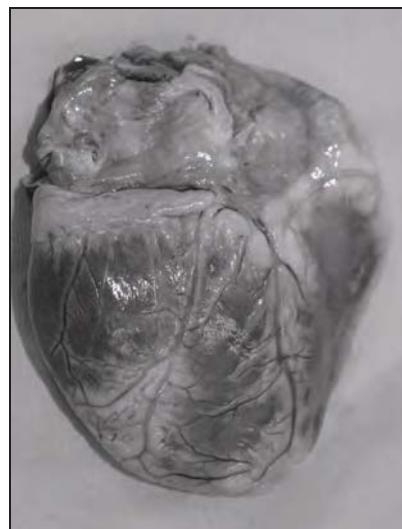

Figure 2-10. The Heart, Gross, Posterior

2-21. The heart is primarily a shell, a hollow muscular organ, with four chambers inside that fill with blood. The two upper chambers are called the left and right atria. The two lower chambers are called the left and right ventricles. The right side and left side of the heart each house one atrium and ventricle. The atria form the curved top of the heart. The ventricles meet at the bottom of the heart to form a pointed base.

2-22. The superior border of the heart connects to a few large blood vessels. The largest blood vessel is an artery—the aorta—which carries oxygen-rich blood away from the heart to the rest of the body. The

<sup>3</sup> Patrick J. Lynch, M.S.

pulmonary artery carries oxygen-poor blood from the right ventricle to the lungs to pick up oxygen. The two largest veins that carry oxygen-poor blood from the body to the heart are the superior vena cava and the inferior vena cava. The superior vena cava is located near the top of the heart. The inferior vena cava is located beneath the superior vena cava.

## **THE LIVER**

2-23. The liver (figure 2-11) is the largest gland in the body. It is located in the upper right-hand portion of the abdominal cavity, beneath the diaphragm and on top of the stomach, right kidney, and intestines. The greater part of the liver is situated under cover of the ribs. It is cone shaped, dark reddish brown, smooth and firm to the touch, and weighs about 3 pounds.



**Figure 2-11. The Liver, Gross, Superior View**

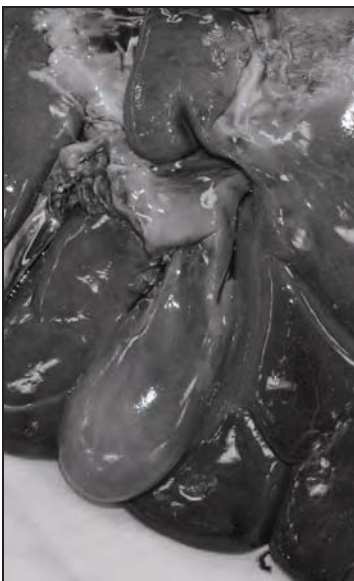2-24. The liver consists of two main lobes, a right and a left lobe. Each lobe is made up of thousands of lobules that are connected to small ducts that, in turn, connect with larger ducts to ultimately form the hepatic duct. The hepatic duct transports the bile produced by the liver cells to the gallbladder and the first part of the small intestine.

2-25. Many vital functions have been identified with the liver. Some of these include the production of certain proteins, cholesterol, and immune factors; conversion of excess glucose; filtration of the blood to remove bacteria and other foreign particles; regulation of blood clotting; regulation of most chemical levels in the blood; and the production and secretion of bile. Bile is the greenish-yellow fluid (consisting of waste products, cholesterol, and bile salts) that performs two primary functions—to carry away waste and to break down fats during digestion.

2-26. At any given moment, the liver holds about one pint (13 percent) of the body's blood supply. All the blood leaving the stomach and intestines passes through the liver.

## **THE GALLBLADDER**

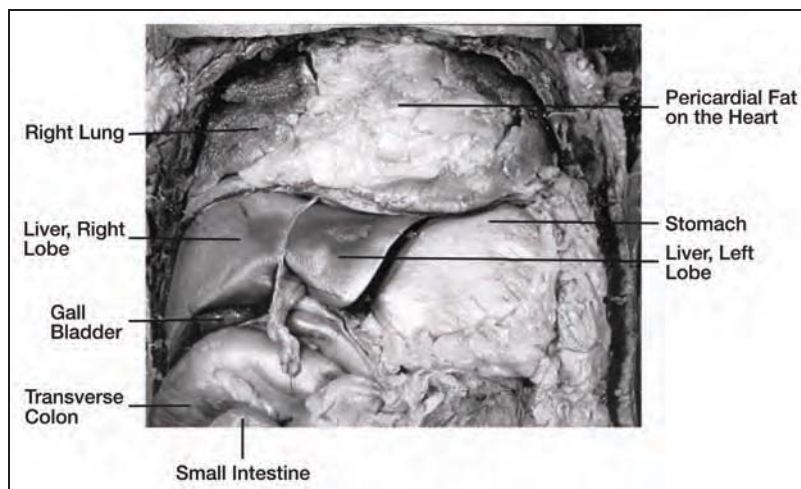
2-27. The gallbladder (figure 2-12) is a pear-shaped, bluish-greenish sac hanging from the underside of the right portion of the liver. It is about 3- to 4-inches long and about 1-inch wide.

**Chapter 2**

**Figure 2-12. The Gallbladder, Gross**

2-28. The gallbladder is divided into the fundus, body, and neck. The fundus is a broad extremity that is directed downward and projects beyond the anterior border of the liver. The body and neck are directed upward. The neck is continuous with the cystic duct.

2-29. The gallbladder stores bile produced by the liver until a person eats. At this time, bile is discharged from the gallbladder via the cystic duct into the duodenum (the first part of the small intestine) where it begins to dissolve the fat in ingested food.



**Figure 2-13. Upper Abdominal Viscera, Gross, Anterior View**

## **THE PANCREAS**

2-30. The pancreas (figure 2-14) is a soft, elongated, tapered organ located between the stomach and spine. It is made up of glandular tissue and a system of ducts. The pancreas is light tan or pinkish in color,



between 5 and 6 inches in length, and approximately  $\frac{1}{2}$ - to 1-inch thick. The pancreas is divided into a head, neck, body, and tail.

- The disc-shaped head is on the right extremity of the organ and lies within the curve of the duodenum (the first part of the small intestine). The head is the widest part of the organ.
- The neck is a thin constricted section that connects the head to the body.
- The body is the middle part of the organ between the neck and tail. It runs upward and to the left across the midline.
- The tail (left extremity) is the thin tip of the organ that is in contact with the spleen.



**Figure 2-14. The Pancreas, Gross**

2-31. Because the pancreas is composed of two types of tissues, exocrine tissue and endocrine tissue, it has two different functions. The exocrine tissues secrete digestive enzymes, which help break down carbohydrates, fats, proteins, and acids in the duodenum. The endocrine tissues secrete hormones, including insulin, into the bloodstream. The hormones maintain proper glucose (sugar) levels.

### **The Spleen**

2-32. The spleen (figure 2-15) is a fist-sized organ, reddish to dark purplish in color. It is oblong, flattened, soft, and highly vascular. The spleen is located in the upper left part of the abdomen. It lies between the stomach and the diaphragm and is in contact with the left kidney.



**Figure 2-15. The Spleen, Anterior Border, Gross**

2-33. The spleen is part of the lymphatic and immune system. The spleen helps control the amount of blood and blood cells that circulate through the body. It also removes damaged cells and bacteria from the blood.

**Chapter 2**

---

**THE KIDNEYS**

2-34. The two bean-shaped kidneys (figure 2-16), each about the size of an adult fist, are reddish-brown to purplish-brown in color. Each kidney is about 4-inches high, 2-inches wide, 1- to 2-inches thick, and weighs between 5 and 6 ounces. The lateral borders are convex and the medial borders are concave. They are located at the back of the abdominal cavity, just below the ribs, toward the middle of the back. There is one kidney on each side of the spinal column.

2-35. The kidneys function to remove liquid waste from the blood in the form of urine—

- To keep a stable balance of salts, water, and other substances in the blood.
- To regulate blood pressure.
- To produce a hormone that aids in forming red blood cells.

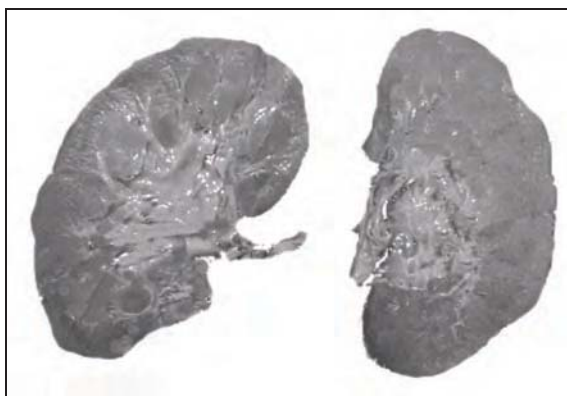


Figure 2-16. The Kidneys, Cross Section, Gross, with Abdominal Aorta

**THE URINARY BLADDER**

2-36. The urinary bladder (figure 2-17) is a hollow balloon-shaped muscular organ. It is located in the lower abdomen immediately behind the pubic bones.



Figure 2-17. The Urinary Tract, Gross, Kidneys, Ureters, and Bladder

2-37. The empty urinary bladder is pyramidal in shape with an apex, a neck, a base, one superior surface, and two inferolateral surfaces. The shape and size of the bladder are the same in both sexes. The empty bladder is no larger than a tennis ball.

2-38. The apex of the urinary bladder is situated behind the upper margin of the pubic symphysis. The base (posterior surface) is triangular. The two ureters are the long narrow tubes that carry the urine from the kidneys to the bladder. The urethra is the canal, located in the neck of the bladder that discharges the urine.

2-39. The urinary bladder is a rather simple organ. It has two main functions—storage of urine and voiding of urine. The amount of urine the bladder can store is about the same in men and women but varies markedly between individuals. An average bladder holds about 2 cups of urine.

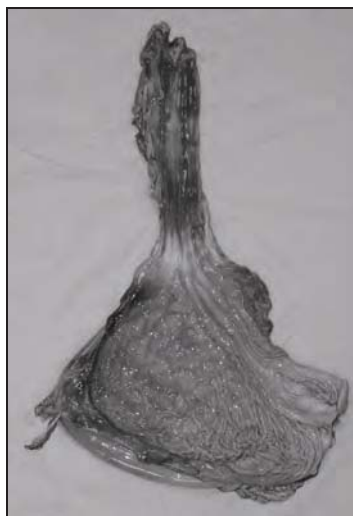## THE ESOPHAGUS

2-40. The esophagus is a long flexible muscular tube that connects the pharynx (throat) and the stomach (figure 2-18). It lies between the trachea (windpipe) and the spine. The length varies from person to person, but generally it is between 10- and 12-inches long.

2-41. The esophagus is made up of several muscle layers that contract in waves to push chewed food and saliva from the mouth into the stomach. The lower esophageal sphincter is a valve at the junction of the esophagus and stomach. It stays closed most of the time but relaxes as chewed food approaches, allowing the food to pass into the stomach. The sphincter functions to prevent food and acid from backing up into the esophagus.

## THE STOMACH

2-42. The stomach (figure 2-18) is a J-shaped hollow, muscular organ in the upper part of the abdomen. Much of the stomach lies under the cover of the lower ribs. Variations in size and shape depend on the volume of its contents, the position of the body, the stage of digestion, and the condition of the adjacent intestines. When empty or almost empty, the stomach contracts to form folds (rugae).



**Figure 2-18. The Esophagus and Stomach, Gross**

2-43. For descriptive purposes, the stomach is divided into three major regions—the fundus (upper), the body (middle), and the antrum (lower). The fundus is a dome-shaped, upward projection. The body extends from the cardiac orifice to the lower portion of the lesser curvature. The antrum forms the lower portion of the stomach. The pylorus is the most distal and tubular part of the stomach.

2-44. As the stomach descends to the right quadrant, the upper smaller angulation is the lesser curvature. The lower longer angulation is the greater curvature.

**Chapter 2**

---

2-45. The stomach has three main functions—to store food, to process food, and to transport food. It stores food immediately after swallowing. It mixes the food with gastric juice (which provides partial digestion) to produce a semifluid substance called chyme. Lastly, the stomach controls the rate of delivery of the chyme to the small intestine for efficient digestion and absorption.

**THE SMALL INTESTINE**

2-46. The small intestine (figure 2-19) is between 18- and 23-feet long. It is the longest section of the digestive tube and is located in the central and lower abdominal cavity below the stomach. The small intestine is a folded muscular tube comprised of three regions that form a passage from the pylorus to the large intestine. These sections are the duodenum, the jejunum, and the ileum.

2-47. The duodenum is a short (about 10 inches) C-shaped section that joins the stomach to the jejunum. It is the shortest, widest, and most fixed portion of the small intestine. The duodenum is important because it receives the openings of the bile and pancreatic ducts.

2-48. The jejunum and the ileum are difficult to distinguish from one another. Both are attached to the posterior abdominal wall by mesentery (a folding membrane). There are some distinctive features, but the change from one section to the other is gradual.

- The jejunum is about 8 feet long. The ileum is about 12 feet long.
- The jejunum lies in the upper part of the peritoneal cavity. The ileum is in the lower part of the cavity and the pelvis.
- The ileum joins the large intestine.

2-49. The small intestine's primary function is digestion and absorption of the products of digestion. Approximately 99 percent of digestion takes place in the small intestine. It is here that the final stages of digestion occur and many nutrients are absorbed by the small intestine.

**THE LARGE INTESTINE**

2-50. The large intestine (figure 2-19) is the portion of the digestive tube between the ileum and the anus. It is about 5 to 6 feet long and forms an arch that surrounds the small intestine. It differs from the small intestine in its greater diameter, its more fixed position, and the presence of many small sacs.

2-51. The large intestine has three sections—the cecum, colon, and rectum.

- The cecum is the relatively large closed pouch in which the large intestine begins. It is about 2- to 3-inches long. It receives undigested food from the small intestine.
- The colon is the longest segment of the large intestine. Here much of the water and salt is extracted from the undigested waste products and returned to the circulation transforming the liquid mass to more solid feces. As it winds through the abdominal cavity, various portions are assigned names corresponding to their relative position.
  - As the large intestine moves upward into the upper right portion of the abdomen just below the liver, it is called the ascending colon.
  - When it curves at the liver and runs across the abdomen, it is referred to as the transverse colon.
  - As it curves down toward the rectum on the left side of the abdomen it is called the descending colon.
- The rectum forms the last 5 to 8 inches of the large intestine. It terminates in the anal canal.

2-52. The large intestine's main function is absorbing water and electrolytes from food residue passing through the intestines. The large intestine also stores undigested material until it is eliminated as feces.

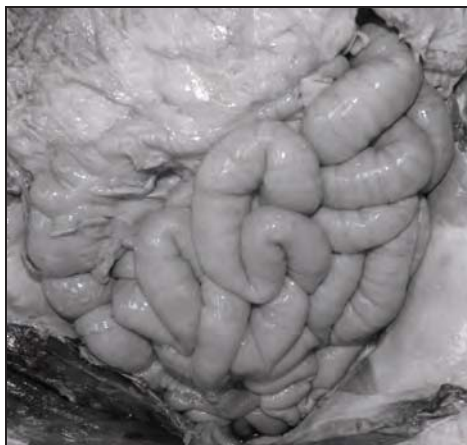


Figure 2-19. The Large and Small Intestines, Gross

## THE APPENDIX

2-53. The appendix (figure 2-20) contains a large amount of lymphoid tissue. It is a worm-shaped hollow tube that varies in length from 3 to 5 inches. The base is attached to the cecum where the small intestine meets the cecum. The tip is free with a considerable range of motion and may be found in a variety of positions.



Figure 2-20. The Appendix, Gross

2-54. The appendix is believed to be a remnant of an organ from human evolutionary past. As such, it may be unnecessary in modern human anatomy.

**This page intentionally left blank.**

## Chapter 3

# ANTEMORTEM AND PERIMORTEM TRAUMA

### OBJECTIVE

3-1. To provide the mortuary affairs specialist with a basic knowledge of wounds and injuries to fleshed and skeletonized remains to enable them to assist identification experts with autopsies and skeletal and anatomical charts.

### WOUNDS AND INJURIES

3-2. Injuries frequently do not occur in isolation. Any one individual can, and often will, display a combination of different wound types and injuries. A wound is defined as any break in the skin or an organ caused by violence, physical injury, or surgical intervention. An injury is defined as any physical damage caused by violence, accident, or fracture, and so forth.

### BURNS

3-3. Burns to skin tissue can occur from contact with a variety of sources—such as heat, fire, extreme cold, electricity, hot liquids, radiation, and chemicals. Regardless of the source of the burn, all soft tissue burns can be classified as either a first, second, third, or fourth degree burn. Figure 3-1 is a diagram of a cross section of the two main layers of the skin. The epidermis is the outermost layer of the skin and covers the dermis. The dermis is the active part of the skin containing the hair, muscles, blood supply, sebaceous glands (glands that secrete sebum, an oily material composed primarily of fat), and nerve receptors.

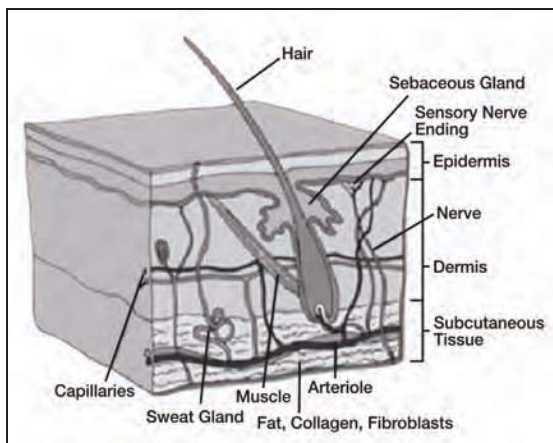


Figure 3-1. Cross Section of the Structures of the Skin<sup>4</sup>

<sup>4</sup> Kelly J. Roberts.

**Chapter 3**

---

**First Degree Burns**

3-4. First degree burns (figure 3-2) are superficial burns, affecting the outer layer of skin (epidermis). The skin appears red or pink in color and may be mildly swollen. The epidermis is intact and there is no blistering. First degree burns can be due to prolonged exposure to low-intensity heat or light. There is usually peeling of the superficial skin cells. Sunburn is the most common kind of first degree burn.




Figure 3-2. First Degree Burn

**Second Degree Burns**

3-5. Second degree burns (figure 3-3) cause damage to the epidermis and part of the dermis. The skin will appear swollen and moist with blisters. Blisters are the distinguishing characteristic of second degree burns. Second degree burns are subdivided into superficial and deep. Severe sunburn or scalding with hot water will produce a second degree burn.

- Superficial second degree burns involve only the most superficial dermis. Blistering is present and there may be sloughing of the overlying skin. Superficial second degree burns heal without scarring.
- Deep second degree burns involve more of the epidermis and dermis. There is destruction of the superficial underlying tissues. It may appear as a blister or a wound with a white or deep red base. There may or may not be blistering. Deep second degree burns can cause permanent scarring.

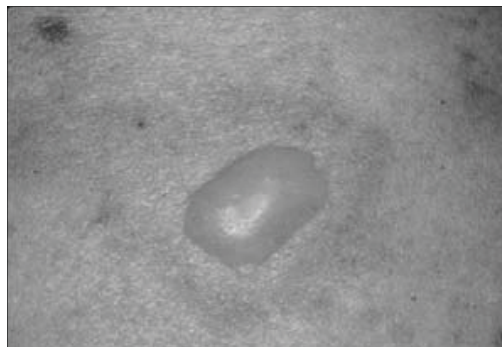


Figure 3-3. Second Degree Burn

**Third Degree Burns**

3-6. Third degree burns (figure 3-4) destroy the epidermis and dermis, extend to the subcutaneous layers, and destroy skin tissue and structures. They may also destroy fat cells, nerve tissue, muscles, and even



bone. Because third degree burns destroy nerve endings, they are often “painless.” There are no blisters. The lesions may look pearly-white and waxy or may appear dark brown or blackened with a leathery appearance due to charring. Third degree burns cause dense scarring.




Figure 3-4. Third Degree Burn

### Fourth Degree Burns

3-7. The term “fourth degree burn” is usually seen in an autopsy report. In fourth degree burns, the injuries extend deeper than the skin. There is destruction of the epidermis and dermis—down to and past the subcutaneous tissue. The nerves are burnt, so there is little associated pain. These burns injure and expose muscle, bone, and tendons. Extensive fourth degree burns are, for the most part, not compatible with survival. If there is survival, then amputation of extremities is typically required.

3-8. Fourth degree burns (figure 3-5) will create severe disfigurement of the remains and frequently cause problems in identification. If the facial structures are mutilated and fingerprints are unobtainable, a dental or DNA identification can be attempted.



Figure 3-5. Fourth Degree Burn

### Pugilistic Posture

3-9. The pugilistic attitude/posture is a basic postmortem change often observed in burn cases. (The word “pugilist” is defined as a fighter especially a professional boxer.) Heat can cause the muscles of the extremities to contract. The arms in particular will take on an altered appearance in which they are drawn up with wrists curled, imitating a boxer’s stance. The muscular contractions, resulting in the pugilistic

**Chapter 3**

posture, can cause fractures of the long bones and cranial vault. Caution should be used in these instances as such fractures may be mistaken for antemortem violence on the body, particularly blunt force trauma.

**Rules of Nines**

3-10. In living individuals, the extent of burn is indicated by the “rule of nines.” Figure 3-6 demonstrates this principle. The total body surface is designated as 100 percent. The extremities, head, and torso are divided as follows; the head is 9 percent, each arm is 9 percent, the front of the torso is 18 percent, the back is 18 percent, each leg is 18 percent and the groin is 1 percent.

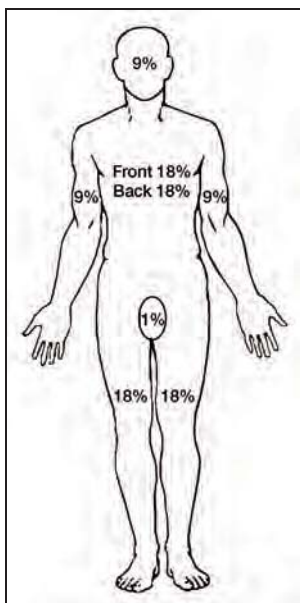


Figure 3-6. Rule of Nines

**BLUNT FORCE INJURY**

3-11. Blunt force injury/trauma is the result of applying force to a body with a blunt instrument. This can occur in a number of ways. The body may be stationary and the blunt force may be mobile (standing individual struck by a stone). The body may be in motion and the blunt force is stationary (individual falling and striking concrete pavement). The body and the blunt force may both be mobile (two individuals in a fight). Blunt injury/trauma includes beatings, kicking, blows from blunt instruments, falls, motor vehicle accidents, and others. The severity, extent, and appearance of injuries due to blunt force trauma depend upon—

- The amount of force delivered to the body.
- The amount of time it takes to deliver.
- The area of the body struck.
- The amount (extent) of body surface over which the force is delivered.
- The type of weapon.

---

*Note.* Blunt force injuries may be present on either the external surface of body or internal organs or both.

---

3-12. The more force that is used to deliver a blow, the greater the extent/severity of the trauma.

3-13. The amount of time it takes to deliver the blow will affect the extent of the injury. Any increase in the period of time over which a blow is delivered will decrease the amount of energy (force) delivered by the blow. (The slower a blow is delivered, the less severe the injury.) Conversely, any decrease in the period of time over which a blow is delivered will increase the amount of force delivered by the blow. (The faster a blow is delivered, the more severe the injury.)

3-14. Different regions of the body will respond differently to blunt force injuries. For example, a wound inflicted from a blow delivered to the head (rounded portion of the body) will be more severe than a wound inflicted by a blow to the back (flat portion of the body).

3-15. The amount of the body surface the injury is inflicted upon also affects the severity of the wound. When a blow is inflicted over a large area, such as the back, the wound will be less severe than a blow to the head because there is a larger area of contact and the force is dissipated over a broader area.

3-16. The type of weapon delivering the blow will affect the severity of the wound inflicted. Clearly, a hammer or a metal rod can inflict more damage than a flat board.

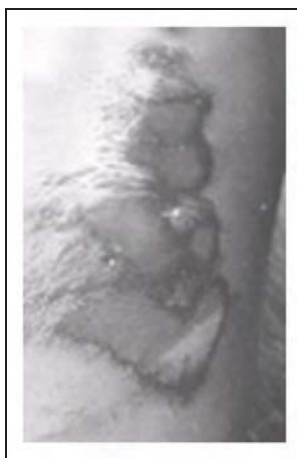3-17. In some cases a modifying factor can affect the injury. A modifying factor is anything that interferes or changes the original application of force, such as the weapon striking an intermediate target or the body moving against the weapon.

## **BLUNT FORCE CATEGORIES**

3-18. There are four categories of blunt force injuries—abrasions, contusions, lacerations to the skin, and fractures of the skeletal system. It is possible that one injury will display a combination of injuries.

### **Abrasions**

3-19. Abrasions (figure 3-7) are superficial injuries produced by excessive friction of the skin against some object. These injuries are seen when an object, with an irregular or rough surface, has struck the skin or where a person has fallen onto a rough surface. There is partial loss of the epidermis. Abrasions include common scrapes, grazes, brush abrasions (burns), scratches, impact abrasions, and patterned abrasions.



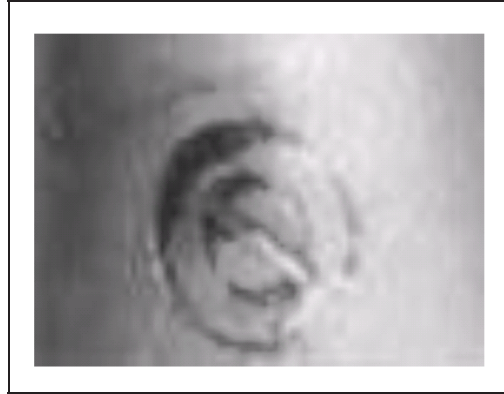**Figure 3-7. Friction Abrasion, the Abdomen**

3-20. Antemortem abrasions are reddish brown in color. Abrasions can be produced postmortem. These are brownish-yellow in color, are translucent, and have a parchment-like appearance with little or no bleeding.

3-21. Abrasions will indicate to the forensic pathologist an area on the body where a blunt force or blunt instrument has impacted the body. There may be a pattern to the abrasions from the striking object that may suggest the type of weapon used. Abrasions can retain much of the surface characteristics of the object that caused the injury. For example, there may be a patterned abrasion (figure 3-8) caused by a vehicle

**Chapter 3**

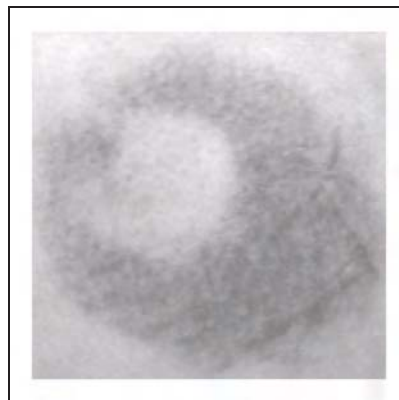
involved in a “hit-and-run” accident, such as that made by a radiator grill or bumper. Tire tread imprints on an individual involved in a hit-and-run are another example of an abrasion that was caused by “stamping” an object against the skin. Belt buckles, ropes, fingers, sticks, pipes, and steering wheels can all leave distinctive abrasion patterns on skin.



**Figure 3-8. Pattern Abrasion on Lower Leg that Matches a Screw-type Bolt and Washer Attached to the License Plate of a Car**

**Contusion**

3-22. A contusion (figure 3-9) is an injury caused by an injury/blow in which the skin is not broken. The striking force will cause the blood vessels beneath the skin to break resulting in a bruise. The localized collection of blood in the area of the contusion is called a hematoma. Contusions can be present on both skin and internal organs. Contusions, like abrasions, can be patterned depending on the object that struck the skin.



**Figure 3-9. Contusion**

3-23. Contusions (bruises) change color over time as they heal. Immediately the bruise will appear purple, dark blue, or red. During the course of healing, it will change to violet, green, and then yellow and brown. The color yellow indicates about 18 hours or more of healing. Other color changes are not predictive. In 13 to 18 days the skin will return to normal.

3-24. Like abrasions, contusions indicate a blunt force to a particular area. However, a contusion will be larger than the weapon/object that produced it because the blood has seeped into the surrounding tissues after rupture of the blood vessels. Thus, a contusion will not always indicate the exact point of trauma. Because a bruise is larger than the object that produced it, it is not possible to correlate the exact size of the object to the size of the bruise. For example, in a linear bruise, such as when an individual is struck with a board or pipe, one can measure the width of the bruise to **estimate** the width of the weapon.

## Laceration

3-25. A laceration (figure 3-10) is the tearing of the skin following crushing or shearing forces. These injuries are caused by forcible contact with a blunt object, falls, or impact with vehicles. The tissue is torn and the edges are irregular. Often incomplete tearing of the tissue occurs and blood vessels and/or nerves can be seen extending from one edge of the laceration to the other. This condition is called “bridging.” The edges usually show some degree of contusion or abrasion. Bridging of tissue is the factor differentiating a laceration from an incised wound. There can be lacerations of both the skin and internal organs.

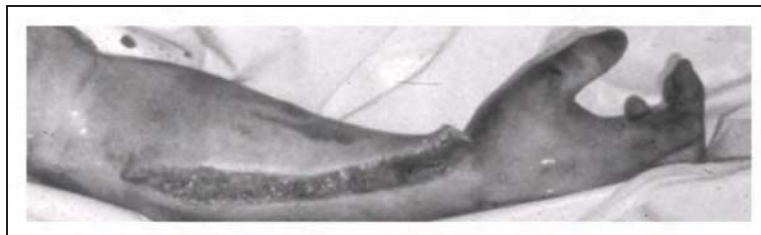

Figure 3-10. Laceration

3-26. Examination of lacerations may determine the nature of the object/weapon used, the amount of force applied, and the direction of the force. Foreign substances may have been deposited in the wound by the object/weapon or the surface that caused the laceration. Foreign substances may provide for trace elemental analysis as an aid in crime reconstruction.

3-27. There may not, however, be an exact correspondence between the shape of the weapon/object and the shape of the laceration. Generally long, thin objects (such as pipes and pool cues) tend to produce linear lacerations. A blunt object with a round edge (such as a ball peen hammer) will produce a stellate (star-shaped) laceration. A blunt object with an edge (such as a typical hammer) will produce a crescent-shaped laceration. Objects with flat surfaces tend to produce irregular, ragged, or Y-shaped lacerations.

## Fracture

3-28. A fracture is a break in the bone. The most common designations of fractures are simple (closed), compound (open), and greenstick. In a simple fracture, the skin is not broken. In a compound fracture, the bone has broken through the skin and is exposed on the surface. A greenstick fracture is an incomplete break of a long bone. One side of the bone is bent inward and the other side is broken outward. Greenstick fractures are common in children, rare in adults. Bone fractures are produced by either direct or indirect trauma.

## Direct Fractures

3-29. Direct fractures are caused by direct application of force to the fracture site. The force (object) may strike a slow or nonmoving body or a moving body may strike a slow or nonmoving object. Direct fractures are divided into tapping (focal), crush, and penetrating fractures.

- **Tapping (focal) fractures** (figure 3-11) result from a small force to a small area, such as a blow from a kick or a stick. The fracture is usually transverse. There is very little soft tissue damage—although a small area of tissue may be split or bruised. If the blow is to an area where two bones are adjacent to each other (such as the forearm or the calf), usually only one bone will be fractured.

## Chapter 3

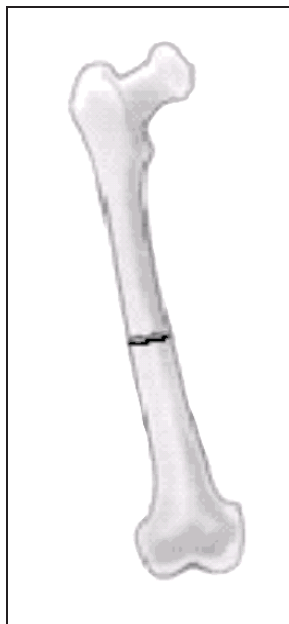


Figure 3-11. Tapping Fracture, Femur




Figure 3-12. Crush Fracture, Calf (Tibia and Fibula)

- A **crush fracture** (figure 3-12) is the result of a large force over a large area. There is extensive soft tissue damage, and there are multiple breaks with splintering or fragmentation of the bone. A crush fracture is, in reality, a massive comminuted fracture. When the trauma is to an area where two bones are adjacent to each other (such as the forearm or calf) both bones fracture at the same level.
- A **penetrating fracture** is the result of a large force upon a small area. The bone is crushed and/or splintered. In reality, penetrating fractures are typically gunshot wounds.

*Indirect Fractures*

3-30. Indirect fractures are produced by a force acting at a distance from the fracture site. Indirect fractures are classified as traction/tension, angulation, rotational, and compression fractures. There are also combinations of the above resulting in angulation and compression fractures and angulation, rotation, and compression fractures.

- In **tension (traction) fractures** the bone is pulled apart by traction. The shaft of a long bone is not likely to be pulled apart. The fracture typically occurs at a joint. The joint is forcefully flexed while the muscles are contracting. In pure tension, the damage is to joints and ligaments. The bone may not be involved. When the bone is fractured, common sites are the patella, the olecranon process of the ulna, and the medial malleolus of the tibia. The fracture line is transverse.
- In **angulation fractures** (figure 3-13) the bone bends until it snaps. There is usually a transverse fracture on one side of the bone with splintering of the bone on the other side. The fragments lie at an angle to each other.

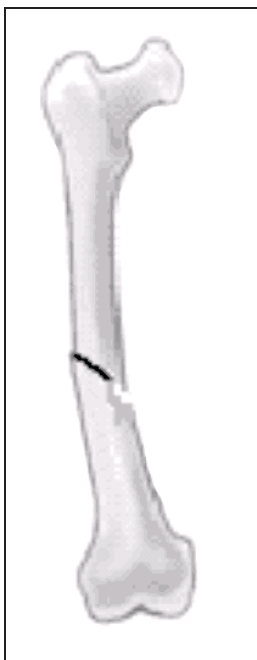


Figure 3-13. Angulation Fracture

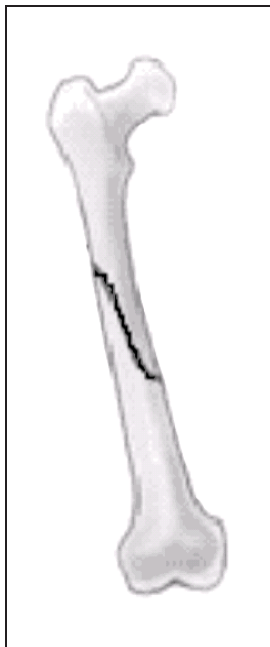


Figure 3-14. Rotational Fracture

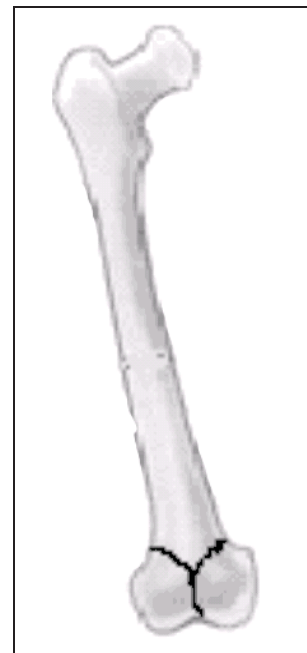

Figure 3-15. Compression Fracture

- In **rotational fractures** (figure 3-14) the bone is twisted and a spiral, often ragged, fracture results. Imagine a piece of chalk that is twisted until it breaks. A characteristic spiral fracture line is produced that makes one complete rotation around the circumference of the chalk.
- **Compression fractures** (Figure 3-15) of the long bones produce T-shaped or Y-shaped fractures due to the hard shaft being driven into the cancellous ends. These fractures are usually observed at the distal ends of the bones. Compression fractures are commonly found in the spine and occur when the vertebrae collapse from their normal height of an inch or so to about half that size.

## BLUNT FORCE INJURY TO THE SKULL

3-31. Blunt force injury to the skull is caused when an object strikes the head or when the head strikes an object (such as when an individual falls and the head strikes a concrete pavement). Blunt force injuries to the scalp, lacerations, abrasions, and contusions have been covered in paragraph 3-18. Therefore, this section will deal solely with the effects of blunt force injuries to the skull.

3-32. Numerous factors affect the severity, extent, and appearance of skull injuries due to blunt force trauma. These factors include the amount of force applied to the skull; the time over which the force was delivered; the size, shape, weight, and consistency of the impacting object; and the contour and thickness of the skull at the point of impact.

- Regardless of the combination of the above factors, there is one consistency in blunt force trauma to the skull. When a blow is delivered to any region of the skull, the skull flattens and bends inward at point of impact. Regions that border the impact area bend outward. Outward bending of the skull may occur at a considerable distance from the point of impact.
- The region of inward bending is usually flat, circular, oval, or stellate and always surrounds the area where the blow was received. The inward bending area may conform to the weapon used. For example, if the skull is struck with a broad, flat surface, the skull will flatten out to conform to the shape of the impact surface. If a skull is struck with a hammer, a circular depressed fracture will occur.

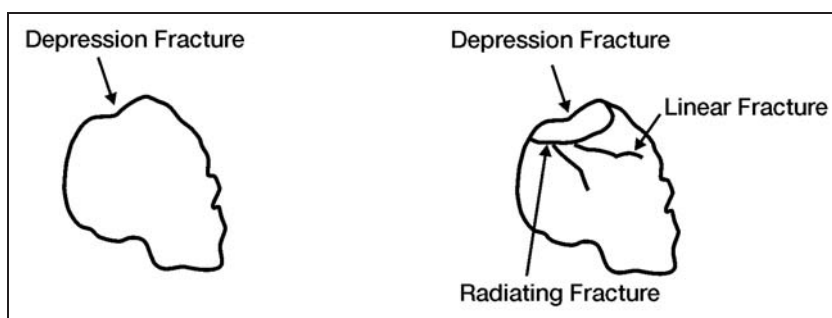
**Chapter 3**

- Where the skull is less curved, there is more inward bending and outward bending than in areas where the skull curves sharply.
- A blunt force trauma does not always produce a fracture.

3-33. Blunt force injuries to the skull are classified as depression fractures, comminuted fractures, linear fractures, circular fractures, stellate fractures, and diastatic fractures.

**Depression Fracture**

3-34. Depression fractures (figure 3-16) develop when a heavy object strikes forcefully over a small surface. The bone is pushed inward and is depressed below the normal level. The appearance is a shallow, concave “pond.” Depression fractures may only involve the outer table of bone—leaving the inner table intact. Alternately, the velocity of the force may be sufficient to involve both the outer and inner tables. Depending on the nature of the blunt force trauma and the bone impacted, there may or may not be linear fracture lines radiating from the area of depression.



**Figure 3-16. Depression Fractures**

3-35. A grazing (low velocity) blow to the occipital bone (dense bone) may result in only a depressed area of bone.

3-36. A forceful blow to the parietal bone (less dense bone) may result in a depressed area as well as fracturing. When there is sufficient force to produce fracturing, there will be radial fracture lines extending outward from the center of impact. There may or may not be linear fractures.

**Comminuted Fracture**

3-37. In comminuted fractures the bone is fragmented into many pieces. These fractures are frequently found in crushing incidents when the skull is compacted under great force, but not necessarily with great speed. The fractured area is wider than it is deep.

**Linear Fracture**

3-38. A linear fracture (figure 3-16) is any single fracture that passes through the outer and inner tables of the cranium. Unlike the name implies, linear fractures are rarely straight; they frequently diverge. They are often found as a result of direct impact with an object. A blow to one area of the head may actually produce a linear fracture on another area.

**Circular Fracture**

3-39. Circular fractures (figure 3-17) exhibit concentric or circular fracture lines encircling the point of impact. They are accompanied by radiating fractures.



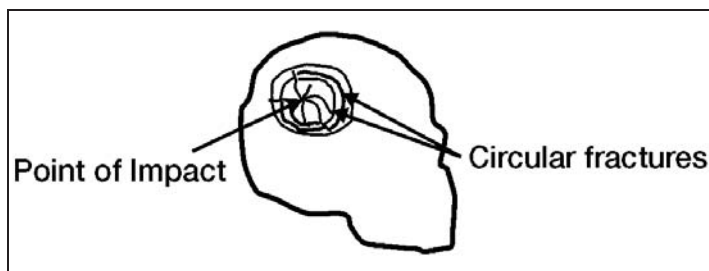


Figure 3-17. Circular Fracture

### Stellate Fractures

3-40. In stellate fractures (figure 3-18) there is a star-shaped injury at the point of impact with multiple radiating linear fractures. The fracture lines originate around the point of impact. Heavy loads of relatively low velocity are a common cause of stellate fractures.

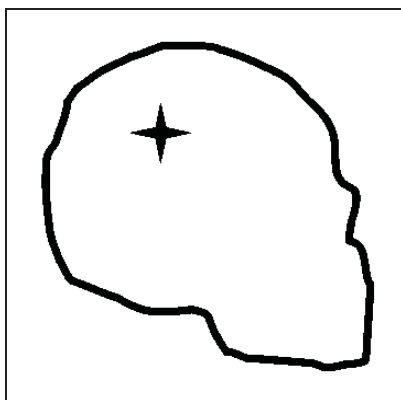


Figure 3-18. Stellate Fracture

### Diastatic Fracture

3-41. In skulls in which the sutures are not completely fused, the sutures represent areas of weakness. Diastatic fractures are fractures that travel along the suture lines causing separation of the cranial bones.

3-42. Diastatic fractures are most common in infants and young children. Diastatic fractures may also be observed in adult victims of gunshot wounds.

### SHARP FORCE INJURY

3-43. Sharp force injuries are produced by sharp-edged objects and typically present a clean appearance. The edges are usually clean, sharp, and not crushed or abraded. They are differentiated from blunt force injuries in that they lack ragged edges, marginal abrasions, and vessels that bridge the wound.


3-44. Sharp force injuries are divided into three categories: stab (cut) wounds, incised wounds, and chop wounds. Some experts include therapeutic/diagnostic wounds under sharp force injuries. These are wounds produced by medical personnel during patient treatment.

### Stab Wounds

3-45. Stab wounds (figure 3-19) to tissue are wounds where the depth of the injury is greater than the length. Because muscle and skin contract around the wound, stab wounds are smaller on the outside but deeper on the inside. Knives are most often used to inflict stab wounds, but bayonets, swords, machetes, screwdrivers, scissors, glass, forks, pens, and pencils also cause them.

**Chapter 3**

---



**Figure 3-19. Stab Wound to Skin Tissue<sup>5</sup>**

3-46. The size and shape of a stab wound in the skin depends upon the weapon, the direction the weapon entered the body, movement of the weapon, and movement of the individual stabbed. The sharpness and design of the weapon will determine the appearance of the wound margins. The stab wound may be sharp and regular, abraded and bruised, or jagged and contused.

3-47. Most experts agree that caution should be employed when rendering an opinion as to the characteristics of a knife used to inflict a fatal stab wound in soft tissue. It is generally not possible to definitely link a knife to a wound unless the knife has broken and a portion of the knife was recovered in the body. The most information that can be inferred is the maximum width of the blade, an approximation of the length, and if it is single edged.

3-48. Stab wounds to bone can be either superficial or deep. A stab wound will puncture, nick, or gouge the bone as it enters the body. Because bone is rigid, it maintains the dimension and shape of a stab wound far better than skin. The edges of a stab wound are typically clean and sharp and the bone is bent inward to conform loosely to the contour of the stabbing weapon. It is often possible to determine the type of weapon used by examining the wound in bone, especially the skull. A stab wound defect in a skull will match the width and thickness of the knife blade. It is often possible to distinguish between a single-edged and double-edged blade and a serrated edge versus a straight-edged blade in knife wounds to the bone. Some cutting tools (such as chain saws and hacksaws) leave striations on bone which can be matched with the weapon.

**Incised Wounds**

3-49. Incised wounds (cuts) (figure 3-20) are usually superficial and produced by sharp objects—such as razors, knives, glass, metal, and even paper. The incision is longer than it is deep. The edges are typically uniform, straight, clean cut, and clear of abrasions and contusions. Because incised wounds are created by drawing a sharp edge along the skin, the wound will typically begin superficial, deepen, and end superficial. The shape of an incised wound will not provide information on the weapon used.

<sup>5</sup> Dr. Edward Klatt.

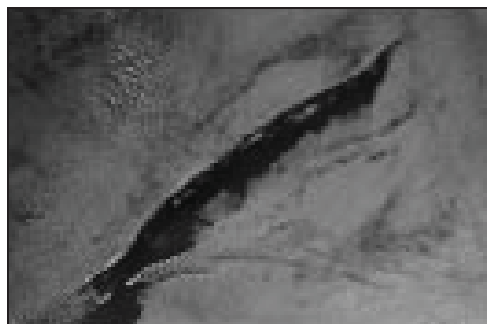

Figure 3-20. Incised Wound

### Hesitation Marks

3-50. Hesitation marks (figure 3-21) are self-inflicted incised wounds that are typically observed on suicide victims. These are multiple superficial wounds usually seen on the wrists, neck, left chest in the area of the heart, or near the wound that proved to be fatal. Hesitation marks often do not go through the skin. Parallel scars may be evidence of previous self-destructive behavior but are not necessarily evidence of suicidal ideation.

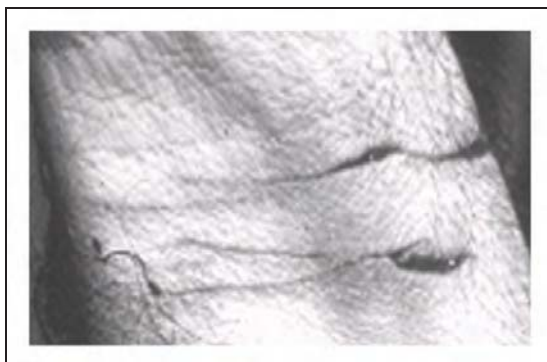


Figure 3-21. Hesitation Marks to the Wrist

### Defense Wounds

3-51. Victims of assaults can sustain sharp force injuries as they attempt to defend themselves. These defense wounds can be either incised or stab wounds. They are typically inflicted on the upper extremities (particularly on the palms of the hands and the backs of the forearms) when an individual attempts to ward off a sharp-edged weapon.

### Chop Wounds

3-52. Heavy instruments with at least one “sharp” cutting edge produce chop wounds. Instruments that produce chop wounds include axes, machetes, cleavers, and propeller blades of boats. Some experts categorize chop wounds as intermediate between sharp force and blunt force injuries.

3-53. Most chop wounds in tissue have an incised appearance. However, in a chop wound the instrument will not only divide soft tissue but will also crush the margins of the tissue and fracture and/or damage underlying bone.

3-54. A chop wound to the skull (figure 3-22) will have a deep linear impression with crushing of the edges of the wound. The fracture or damage (crushing, cutting, or fragmentation) to the underlying bone distinguishes a chop wound from an incised wound.

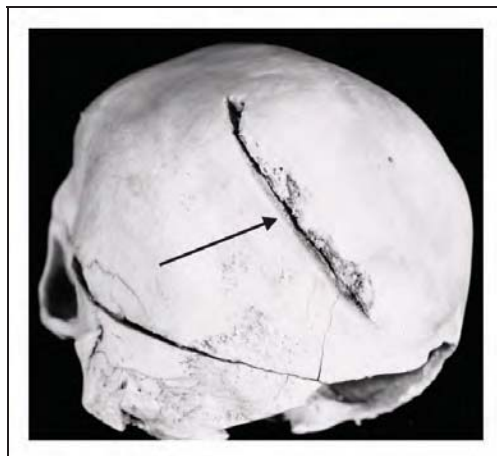


Figure 3-22. Chop Wound

## GUNSHOT WOUNDS

3-55. Gunshot wounds are classified as grazing, penetrating, or perforating. At times a combination of gunshot wounds can occur in the same individual. A penetrating wound occurs when a low-velocity bullet enters tissue and is retained in the tissue. A perforating wound occurs when the bullet passes completely through the tissue.

3-56. Gunshot wounds are divided into four broad categories, which reflect the distance of the body from the weapon. These categories are contact, near contact, intermediate (medium range), and distant. When a weapon is fired, the bullet, gases from combustion, primer components, and burnt and unburnt powder are propelled out of the muzzle at the same time. The patterns these elements produce on the skin are used to determine the range of fire.

### Contact Gunshot Wound

3-57. A contact gunshot wound occurs when the muzzle of the weapon is placed in direct contact with the surface of the body at time of discharge. The hot gases and particulate matter are blasted into the body at the same time as the bullet. In all contact wounds, the hot gases char the tissues. The gunpowder and metal fragments are deposited in and along the wound track or on the skin surface. Gunpowder blackening is present, but no tattooing or stippling (see below). There is usually an impression of the muzzle burned around the entrance wound.

3-58. Contact gunshot wounds over the skull can give rise to a stellate (figure 3-23) or lacerated appearance in the tissue, due to the expansion and tearing of tissues by gases being blown into the wound.

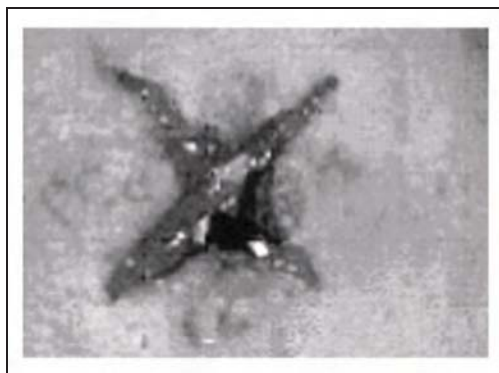


Figure 3-23. Stellate Gunshot Entrance Wound<sup>6</sup>

3-59. Contact gunshot wounds (figure 3-24) leave a round or oval central defect, abrasion collar where the bullet abraded the skin surface as it passed through it. There is a circular bruise over the skin due to muzzle impact. The size of the defect is comparable to the size of the muzzle opening or bore of the weapon.

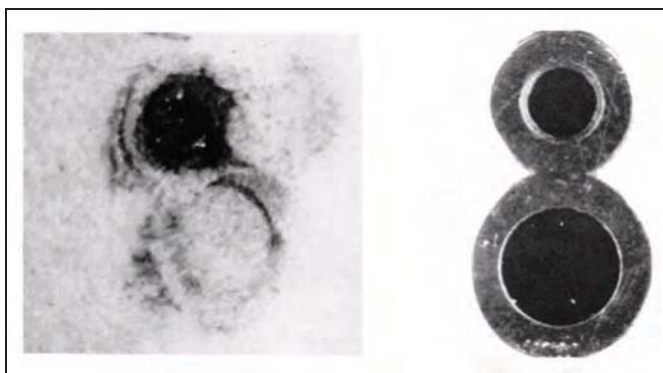


Figure 3-24. Contact Gunshot Wound (Left) and the Muzzle of the Weapon (Right)

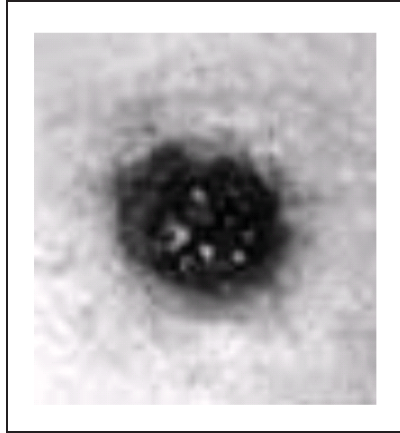### Near Contact Gunshot Wound

3-60. In near contact gunshot wounds (figure 3-25) the muzzle of the weapon is not in contact with the body, but a short distance away. The entrance wound will show similar features to the contact gunshot wound except for the absence of the muzzle imprint. There is a larger central defect (entrance wound) surrounded by a wide zone of powder soot over blackened skin—fouling. (Fouling is caused by soot that travels a short distance from the gun barrel and is deposited on the skin.)

<sup>6</sup> Dr. Edward Klatt.

**Chapter 3**

---



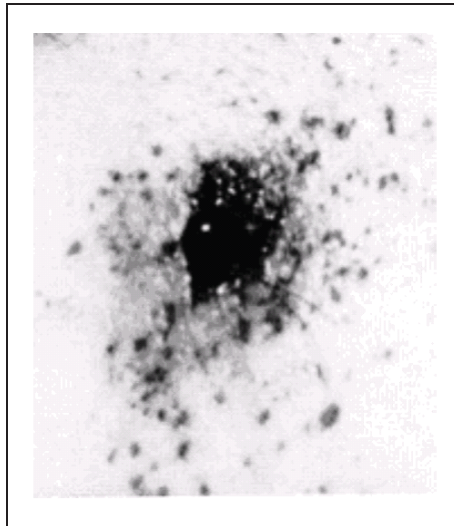
**Figure 3-25. Near Contact Gunshot Wound**

3-61. Near contact wounds caused by a pistol produce a dense zone of stippling with a wide soot deposit. The entrance defect is not large and there is no laceration of the surrounding skin.

3-62. Rifle wounds cause devastating contact injuries of the head but will also cause entrance lacerations or micro tears at a distance. Near contact wounds of the chest or abdomen with a rifle or shotgun may not lacerate due to the ability of the chest and abdominal cavities to distend and the increased thickness of subcutaneous tissues to displace pressure.

**Intermediate Gunshot Wound**

3-63. In intermediate (medium range) (figure 3-26) gunshot wounds the distance is too far for soot to travel but not too far for powder grains to travel. Hot fragments of unburned gunpowder and small metal fragments follow the bullet and produce numerous small, dry, reddish orange or brown punctate lesions around the entrance wound—tattooing. Tattooing is indicative of intermediate wounds.



**Figure 3-26. Intermediate Gunshot Wound**

**Distant Gunshot Wound**

3-64. The only marks on the body in distant gunshot wounds (figure 3-27) are those of the bullet penetrating the skin. The distance is too far for either soot or gunpowder to travel. The wound margins are

clean; there is no fouling or stippling. Classically, the entrance wound is a central hole with scalloped margins and an abrasion ring around the entrance hole. The exit wound lacks abrasion.

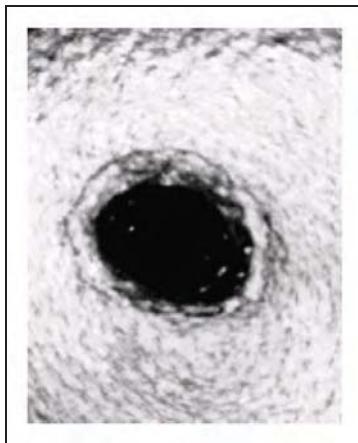


Figure 3-27. Distant Gunshot Wound, Entrance

### Gunshot Entrance and Exit Wounds

3-65. Gunshot entrance wounds and exit wounds can usually be easily differentiated in both tissue and bone. The entry wound is typically small, round to oval in shape, and sharp edged. The exit wound is often considerably larger (figures 3-28 through 3-30).

3-66. Entrance wounds typically share similar characteristics. In tissue, they are normally round or oval and sharp edged. There is a rim of flattened, abraded skin surrounding the entrance hole (the abrasion ring), which will have a punched-out appearance. The abrasion ring is caused by the bullet scraping and perforating the skin. The defect will be smaller than the diameter of the bullet due to the constriction of the surrounding skin and muscle. Entrance wounds on the palms of the hands or soles of the feet may be slit-like and much smaller than the bullet.

3-67. Exit wounds in tissue are usually larger and more irregular than entrance wounds. They may be slit-like or have ragged edges. There is no abrasion ring in the skin. If the exit wound is shored by clothing or a hard surface, there will be an abrasion of varying size around the defect.

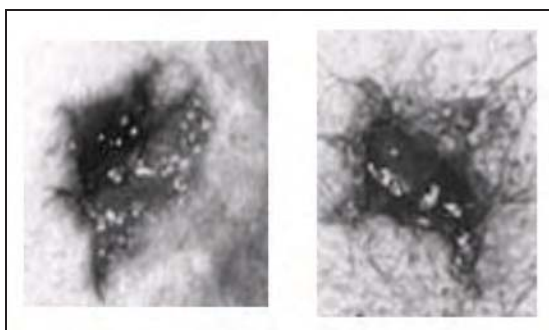
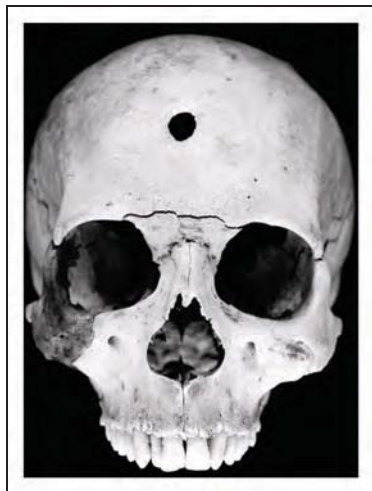


Figure 3-28. Exit Wounds to Skin Tissue

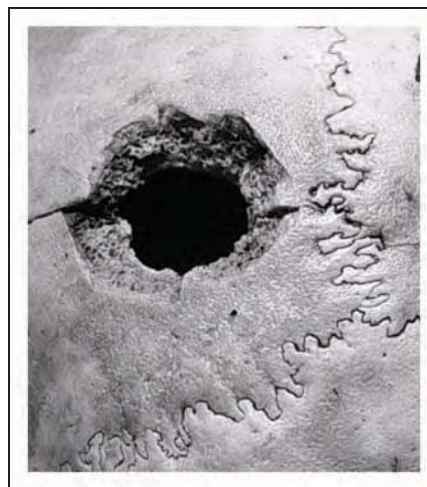3-68. When a bullet enters the skull, it leaves a round or oval sharp-edged, punched-out hole on the outside of the skull (figure 3-29). On the inside of the skull, the entrance hole will be larger and beveled. When the bullet exits the skull, the inner table is now the “entrance” surface and the outer table is the exit surface. Therefore, the inner table of an exit wound will have relatively round sharp-edged appearance and the outer table will display a cone-like exit wound. The “textbook” identifier of an entrance wound to the

**Chapter 3**

skull is internal beveling. The “textbook” identifier of an exit wound to the skull is external beveling. The exit wound has a cone-like appearance (figure 3-30).



**Figure 3-29. Gunshot Entrance Wound**



**Wound Figure 3-30. Gunshot Exit Wound**

3-69. A high velocity projectile will cause greater and more rapid fracturing than a low velocity projectile. High-power weapons—such as rifles—release high velocity projectiles. As the projectile enters the skull, there is a sudden expansion of bone that results in a “starburst” wound. There are numerous cracks radiating out from the point of impact. Low-power weapons—such as pistols—release low velocity projectiles. The wound is typically a simple entrance wound, but there may be fracturing, especially with wounds to the skull. There may or may not be an exit wound.

3-70. Artillery and mortar rounds tend to produce fragments and shrapnel between .07 and 3.0 grams. Those from grenades and landmines are smaller, approximately 0.59 grams and rarely over 1.0 grams. Shrapnel may cause laceration wounds or penetrating injury or contusions, fractures, or abrasions, or a combination of injuries.

## **ASPHYXIA**

3-71. Asphyxia is a broad term that refers to a state in which the body becomes deprived of oxygen while in excess of carbon dioxide. This state will lead to loss of consciousness and/or death. The classic signs of asphyxia are—

- An abnormal accumulation of fluid (congestion) within the face and organs.
- Cyanosis—a bluish-purple discoloration of the skin and mucous membranes due to reduction in oxygen carrying hemoglobin in the blood.
- Petechiae—small, pinpoint, dark red spots directly beneath the skin surface and the mucous membrane covering the anterior portion of the eyeball (conjunctiva). The petechiae are caused by the rupture of the small vessels, which bleed into the tissues.

3-72. Deaths from asphyxia are classified as suffocation, strangulation, and chemical asphyxia.

## **SUFFOCATION**

3-73. In suffocation deaths, oxygen fails to reach the blood. Suffocation can occur from smothering, choking, positional asphyxia (when individuals get into a position in which they cannot breathe), or when oxygen has been displaced from the air by suffocating gases.



## **STRANGULATION**

3-74. In strangulation deaths, external pressure on the neck closes the blood vessels and air passages of the neck preventing passage of blood and air to the brain. There are three forms of strangulation deaths—hanging, ligature strangulation (application of a constricting band to the neck, the force applied in any manner other than by body weight), and manual strangulation (pressure by hands or forearm against the neck).

## **CHEMICAL ASPHYXIA**

3-75. Chemical asphyxia is caused by a gaseous compound that inhibits the ability of the cells to use oxygen. The most common chemical asphyxiants are carbon monoxide and cyanide.

### **Carbon Monoxide**

3-76. Carbon monoxide is colorless, odorless, and tasteless. Most casualties of fire are due to inhaling CO rather than thermal injuries. CO deaths from defective heaters and automobile exhaust are also common.

3-77. In death by carbon monoxide poisoning in Caucasoid individuals, the skin takes on a cherry red or bright pink appearance. In individuals with dark skin pigmentation, the cherry red coloration is prominent in the nail beds, mucosa of the lips, and the conjunctivae. In autopsy the muscles, organs, and blood will also have a bright cherry red coloration.

### **Cyanide**

3-78. A cherry red or pink lividity indicates a cyanide death. Cyanide has an aroma of bitter almonds.

## **DROWNING**

3-79. Drowning is death due to submersion. Water or liquid is inhaled into the airways, blocking passage of air to the lungs. In “wet” drowning, inhaling water causes choking. Hypoxia (reduction of oxygen to tissue) causes breathing to cease and brain death occurs with the shutdown of the respiratory center. Victims are identifiable by a “foam cone” or froth covering the mouth and nostrils. “Dry” drowning occurs when the larynx spasms and the water never enters the lungs. “Dry” drowning was developed to explain drowning where there was no pulmonary edema or foam/froth. Some experts believe that “dry” drowning is the result of arrhythmia, an abnormal rate of muscle contractions in the heart.

3-80. In autopsy there is no absolute test to determine if an individual has died from drowning. The diagnosis is made based on the circumstances of death, investigative reports, witness statements, and generally nonspecific findings. If an individual is found in a river and all other causes of death have been ruled out, then that individual is presumed to have died from drowning. Some nonspecific findings include foam in the mouth, nostril, and airways; skin wrinkling (“washerwoman” appearance); water in the stomach and lungs; foreign material in the mouth, airways, lungs, and gastrointestinal tract; eyelid petechiae; and middle ear hemorrhage.

3-81. Rigor mortis (see chapter 7) may start early because of violent struggling at the time of drowning. When an individual drowns, the body sinks, the head is down, and the extremities are dangling downward. Thus, postmortem lividity (which is often light red in color) is most noted in the head and upper chest, hands, lower arms, feet, and calves due to the posture of the body while submerged.

**This page intentionally left blank.**

## Chapter 4

# HUMAN OSTEOLOGY

### OBJECTIVE

4-1. To provide mortuary affairs Soldiers with knowledge of the human skeletal system to assist proficiently in recovering skeletal remains.

### GLOSSARY OF OSTEOLOGICAL TERMINOLOGY

4-2. Anatomists and anthropologists use a specific standardized vocabulary to describe the human skeletal system. Standardized terminology facilitates unambiguous communication among all researchers.

#### ALVEOLAR PROCESS

4-3. The alveolar process is the ridge of bone in the maxilla and mandible that contains the alveoli.

#### ALVEOLUS (SINGULAR); ALVEOLI (PLURAL)

4-4. The alveolus is a single tooth socket; the cavity in which the root of a tooth is held in the alveolar process.

#### APPENDICULAR SKELETON

4-5. The appendicular skeleton includes the bones of the limbs (arms and legs), pelvic girdle, and pectoral (shoulder) girdle. The pelvic girdle includes both hip bones and the sacrum. Each pectoral girdle includes the scapula and the clavicle.

#### ARTICULATE

4-6. Articulate (verb). To come into contact with.

#### ARTICULATION

4-7. Articulation (noun). The area where two or more bones or skeletal parts come in contact with one another, such as joints and sutures. For example, the synovial joints provide a structure where bones abut against and move about one another.

#### AXIAL SKELETON

4-8. The axial skeleton includes the bones of the head, vertebrae, ribs, and sternum.

#### BOSS

4-9. A boss is a rounded eminence usually used in reference to the shape of the frontal or parietal bones of the skull.

#### CONDYLE

4-10. A condyle is a rounded projection for articulation with another bone.

**Chapter 4**

---

**CREST**

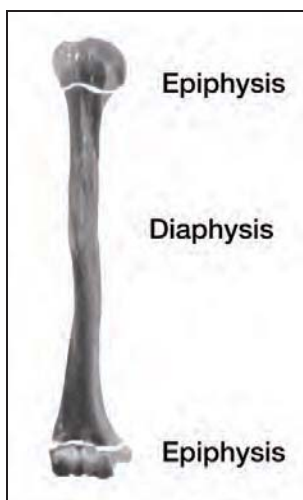
4-11. A crest is a narrow, usually prominent ridge of bone.

**DEGENERATIVE CHANGES**

4-12. Degenerative changes are those which occur in the human skeleton after the skeleton has finished growth and development. These changes are basically ones of erosion and general deterioration and ossification of otherwise soft tissue.

**DIAPHYSIS**

4-13. The diaphysis is the long straight section (shaft) of a long bone (figure 4-1). It is the extension of the primary ossification center of the long bone.



**Figure 4-1. Diaphysis and Epiphyses of the Right Humerus**

**EMINENCE**

4-14. An eminence is a bony projection that is usually not as prominent as a process.

**EPIPHYSEAL CLOSURE**

4-15. Epiphyseal closure is the fusion of the epiphysis with the diaphysis that occurs during growth.

**EPIPHYSIS (SINGULAR); EPIPHYSES (PLURAL)**

4-16. The end of a long bone that is originally separated from the diaphysis by a layer of cartilage but that later becomes united to the diaphysis through ossification (figure 4-1).

**FONTANELLE**

4-17. In an infant, the cranial bones are not joined together firmly at birth. The spaces where two sutures intersect form a membrane-covered "soft spot" called a fontanelle (fontanel). The fontanelles allow the birth canal to accommodate the neonates head during birth and provide for the growth of the skull during an infant's first year. There are five fontanelles—the anterior, posterior, mastoid, sphenoid, and metopic fontanelle (figure 4-2).

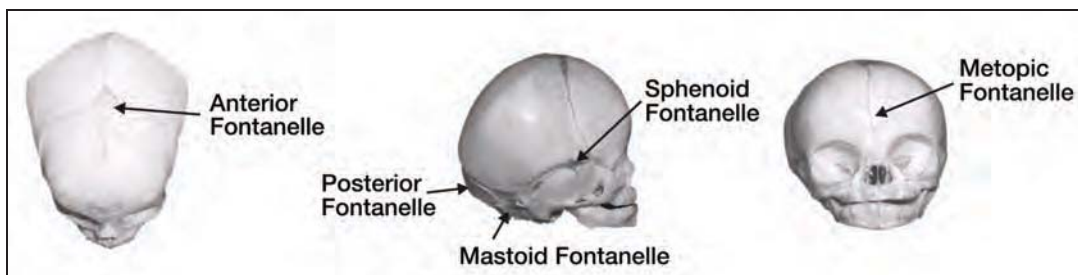


Figure 4-2. Fontanelles

## FORAMEN

4-18. A foramen is a round or oval hole, an opening. The foramen magnum is the large hole in the base of the skull through which the spinal cord passes.

## FORENSIC ANTHROPOLOGIST

4-19. Forensic anthropologists are specialists in the human skeletal system. They have advanced training in human anatomy and all aspects of the human skeleton. They combine their knowledge of human anatomy and the human skeleton to evaluate skeletonized or partially skeletonized remains in a legal context.

## FUSE/FUSION (OR UNION)

4-20. When the epiphyses of the bones unite (ossify) to their respective elements.

## HEAD

4-21. A head is the large, rounded smooth articular end of a long bone, such as in the head of the humerus and the head of the femur.

## MORPHOLOGY

4-22. Morphology is the branch of biology which deals with structure and form. In osteology, it refers to the shape and size of a bone or its general appearance.

## NECK

4-23. The neck is the constricted portion of bone between the head of a long bone and the shaft.

## OSSIFICATION

4-24. Ossification is the formation of bone, the conversion of cartilage into bone (mineralization).

## OSTEOLOGY

4-25. Osteology is the detailed study and analysis of bones and the skeletal system.

## PROCESS

4-26. A process is a bony projection or prominence.

## SINUS

4-27. A sinus is a cavity within a cranial bone.

**Chapter 4**

---

**SPINE**

4-28. A spine is a long, thin, sharp projection.

**STATURE**

4-29. Stature is the height of any animal while standing.

**SYMPHYSIS (SINGULAR); SYMPHYSES (PLURAL)**

4-30. A symphysis is the line or junction formed by a cartilaginous articulation, the most common being between the two bones of the pelvis and the two halves of the mandible.

**SUTURE**

4-31. A suture is a specially serrated and interlocking joint where the adjacent bones of the skull meet.

**TROCHANTER**

4-32. A trochanter is a large roughened prominence for the attachment of muscles, specifically one of two processes found on the femur for the attachment of rotator muscles.

**TUBEROSITY**

4-33. A tuberosity is a roughened, rounded protuberance, such as those found on the humerus.

**TUBERCLE**

4-34. Tubercle is a small, roughened, rounded eminence.

**ADULT HUMAN SKELETON**

4-35. Other than dental enamel, bone is one of the strongest biological materials in existence and is the main supporting tissue of the body. Bone is very lightweight and constitutes less than 20 percent of the weight of the human body. There are typically 206 bones in the adult human skeleton (figure 4-3). Bones grow and change during the life of an individual. As a result, bones vary like people do. The shape and size of bones can differ dramatically between individuals. Individual bones are identified on the basis of their size and shape. The long bones are the bones of the arms and legs which act as levers to produce motion when acted upon by muscles. Short bones are strong and compact and located in the wrist and ankle. Flat bones, like the scapulae and sternum, form protective plates and provide broad surfaces for muscle attachments. Irregular bones, like the vertebrae, have many surfaces and articulate at many points.

4-36. The adult skull, comprised of 28 individual bones, is the most complex element of the skeleton. Many of the cranial bones are fused in the adult skull and do not appear as individual bones and are difficult to distinguish. The skull is the bony protection for the brain and the organs of sense. Technically the term "skull" refers to the entire bony framework of the head and mandible (lower jaw). The cranium is the skull minus the mandible. The calvarium is the cranium without the face.

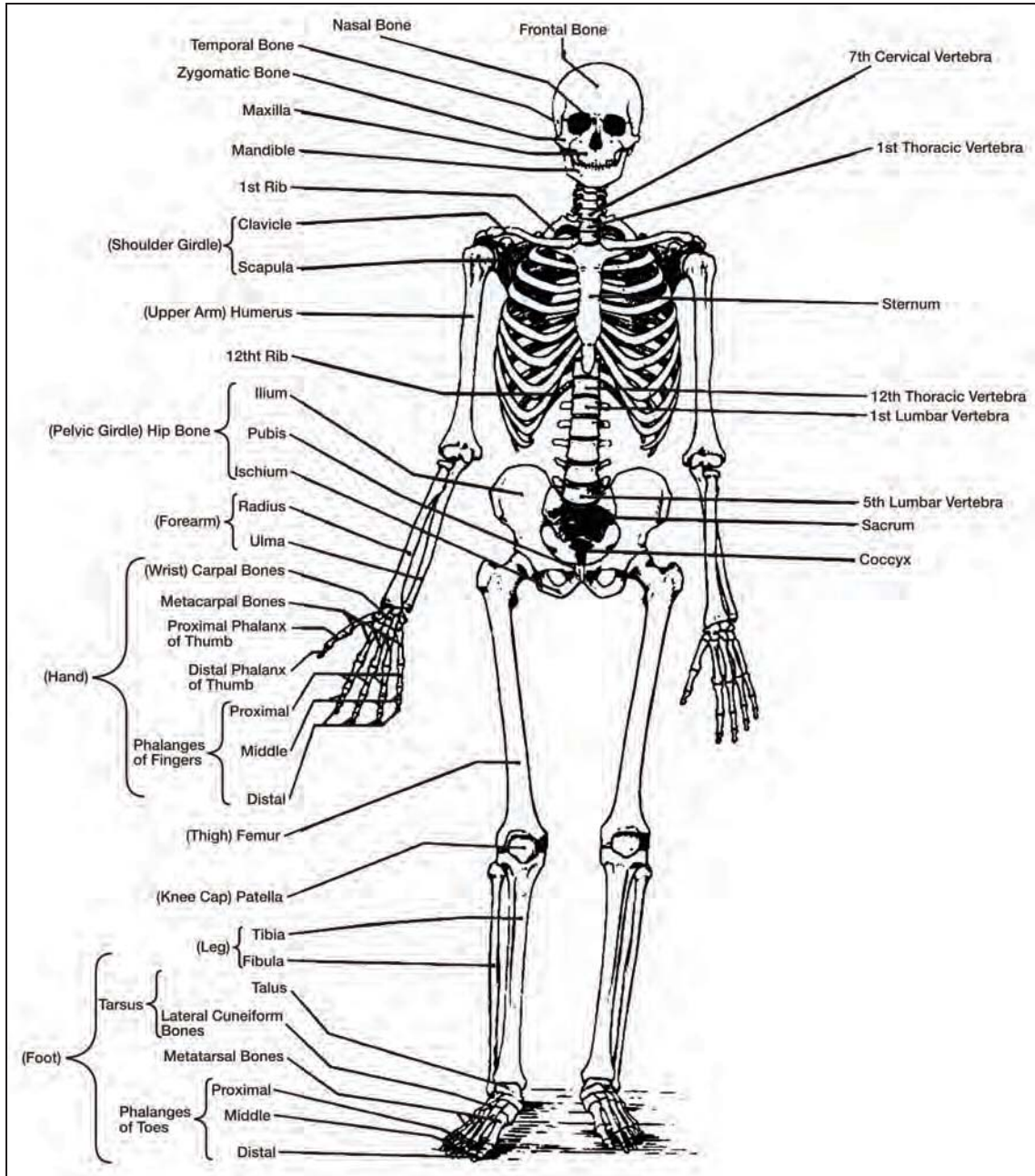


Figure 4-3. The Human Skeleton

### Frontal Bone

4-37. The frontal bone (unpaired) (figure 4-4, figure 4-5, and figure 4-6) is one of the largest and most robust bones of the skull. It is the anterior portion of the skull and curves downward to form the upper margins of the orbits. The frontal bone articulates with the parietal, ethmoid, lacrimal, nasal, and zygomatic, sphenoid and maxillae bones.

Chapter 4

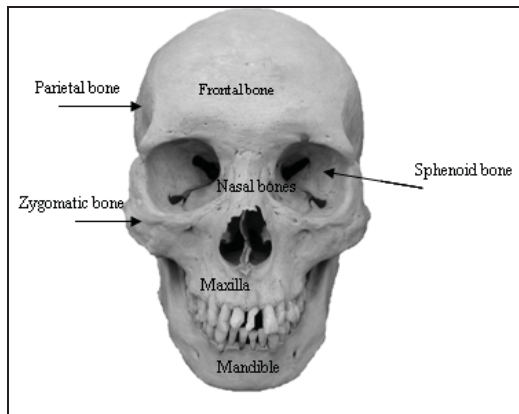


Figure 4-4. The Skull, Frontal View<sup>7</sup>

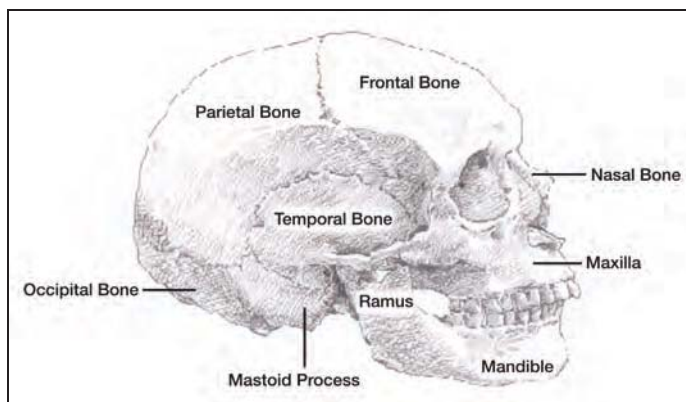


Figure 4-5. The Skull, Right Lateral View<sup>8</sup>

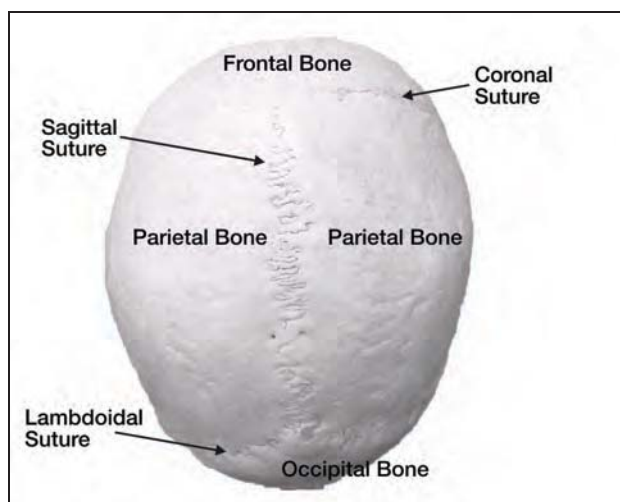


Figure 4-6. The Cranium, Superior View

<sup>7</sup> Daniel Maidman.  
<sup>8</sup> Daniel Maidman.



### Parietal Bone

4-38. The parietal bones (paired) (figure 4-4, figure 4-5, and figure 4-6) form a large portion of the sides and roof of the skull. Each parietal bone lies between the frontal and the occipital bone. They are the largest bones of the cranium and are relatively square in shape. Each parietal bone articulates with the other parietal bone at the roof of the cranium (midline) along the sagittal suture. They articulate with the occipital bone along the lambdoid suture, with the frontal bone along the coronal suture, with the temporal bone at the squamosal suture, and with the sphenoid.

### Temporal Bone

4-39. The temporal bones (paired) (figure 4-5) are located at the sides and base of the cranium. Each temporal bone holds three auditory ossicles, the bones of hearing, and provides the articulations for the mandible. Each temporal bone articulates with a parietal bone, the occipital bone, sphenoid, zygomatic bone, and mandible.

### Occipital Bone

4-40. The occipital bone (unpaired) (figure 4-5, figure 4-6, and figure 4-7) forms the posterior, inferior part of the cranium. The foramen magnum, the hole through which the spinal cord enters the cranium, is located here. The occipital articulates with the parietal bones, the temporal bones, the sphenoid, and through the occipital condyles with the first cervical vertebra.

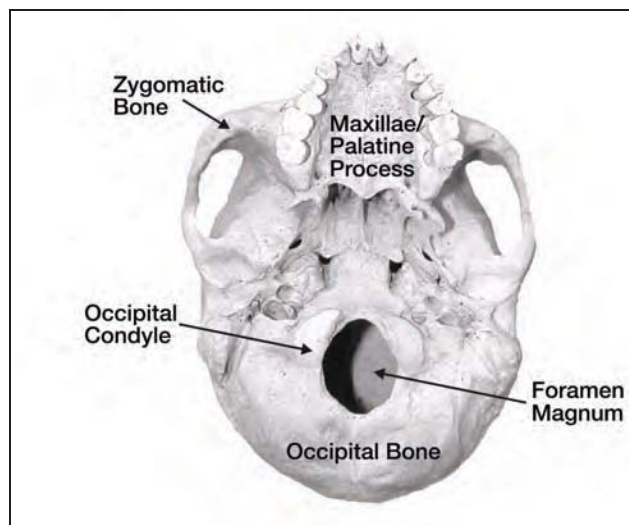


Figure 4-7. The Cranium, Inferior View

### Maxillae (Plural) Maxilla (Singular) Bone

4-41. The maxillae (paired,) (figure 4-4 and figure 4-5) are the large bones that support the upper teeth and help to form the lower margins of the orbits, the nasal opening, and the anterior portion of the hard palate (roof of the mouth). They form the major part of the face. The maxillae articulate with each other at midline and with the frontal bones, nasal bones, lacrimal bones, ethmoid, inferior nasal conchae, palatine bones, vomer, zygomatic bones, and the sphenoid.

**Chapter 4**

---

**Palatine Bone**

4-42. The palatine bones (paired) (figure 4-7) form the posterior portion of the hard palate and part of the wall and floor of the nasal cavity. These bones are small, delicate, and L-shaped.

**Nasal Bone**

4-43. The nasal bones (paired) (figure 4-4 and figure 4-5) are small, rectangular bones that form the bridge of the nose. They articulate with each other at midline, with the frontal bone at the nasal bridge, and with the maxillae.

**Lacrimal Bone**

4-44. The lacrimal bones (paired) (figure 4-5) are very small delicate, rectangular-shaped bones that form the anterior portions of the medial eye sockets. A small groove between the orbit and the nasal cavity serves as a pathway for a tube that carries tears from the eyes.

**Ethmoid Bone**

4-45. The ethmoid bone (unpaired) (figure 4-5) is a light and delicate bone that is located midline between the orbits. It forms part of the roof of the nasal cavity.

**Inferior Nasal Conchae Bone**

4-46. The inferior nasal conchae (paired) are located along the lateral walls of the nasal cavity. They are very fragile, thin, curved bones that support the mucous membranes that line the nasal cavity. These membranes aid in the sense of smell and in moistening inhaled air.

**Vomer Bone**

4-47. The vomer (unpaired) is a small, thin flat plow-shaped bone. It is located between the nasal cavities and joins with the ethmoid to form the inferior and posterior portions of the nasal septum respectively.

**Zygomatic Bone**

4-48. The zygomatic bones (paired) (figure 4-4, and figure 4-7) are also known as the malars. These triangular bones are on both sides of the face below the eyes. They form the sides of the orbits and “cheekbones.” Each zygomatic bone articulates with a temporal bone, maxilla, frontal bone, and sphenoid.

**Sphenoid Bone**

4-49. The sphenoid (unpaired) (figure 4-5) is a very irregular and complex bone that helps form the base and sides of the cranial vault and the floors and sides of the orbits. It articulates with 12 bones. The name “sphenoid” means wedge like. The sphenoid is composed of a body, two pairs of lateral expansions called greater and lesser wings, and a pair of downward projecting processes (pterygoid plates). The saddle-shaped, midportion of the sphenoid (the sella turcica) houses the pituitary gland.

**Mandible Bone**

4-50. The mandible (lower jaw) (figure 4-4 and figure 4-5) is the strongest bone of the face. It holds the lower teeth. The mandible has two upright projections called rami. (Ramus is singular.) Each ramus has a mandibular condyle that articulates with the temporal bone. Each ramus also has a coronoid process that serves as a place of attachment for the chewing muscles.

## ADULT POSTCRANIAL SKELETON

### HYOID BONE

4-51. The hyoid bone is a U-shaped bone located in the neck (figure 4-8). The hyoid does not articulate with another bone. It supports the tongue, and provides attachment for several muscles.

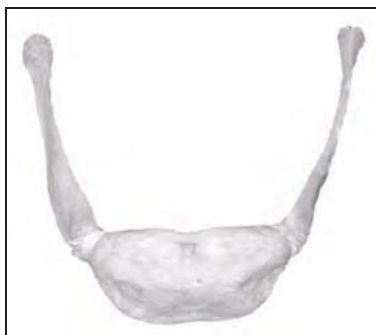

Figure 4-8. The Hyoid Bone

### VERTEBRAL COLUMN

4-52. The vertebral column protects the spinal cord and supports the weight of the head and trunk (figure 4-9). The vertebral column is usually composed of 33 elements. The upper 24 elements are separate movable vertebrae that are normally associated with the vertebral column. The sacrum (5 elements) and coccyx (4 elements) may fuse in adulthood to form an immovable bone. However, the coccyx does not always fuse to the sacrum. The sacrum and the coccyx will be described below in relation to the pelvis. The upper 24 vertebrae are divided into cervical (7 elements), thoracic (12 elements), and lumbar (5 elements) vertebrae.

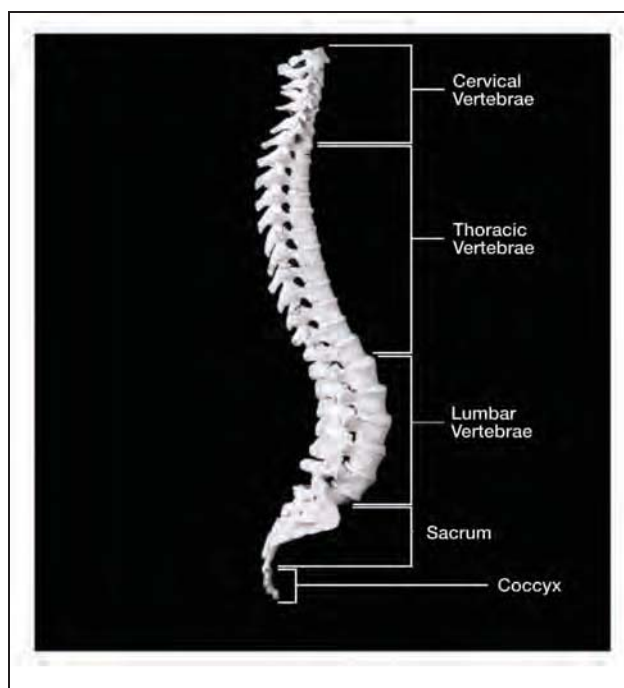
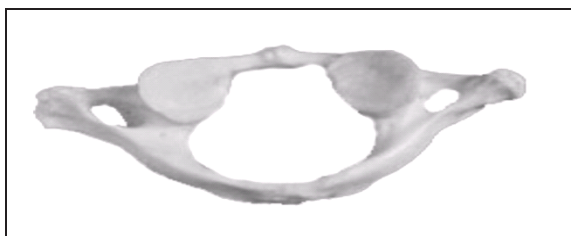


Figure 4-9. The Vertebral Column

**Chapter 4****Cervical Vertebrae**

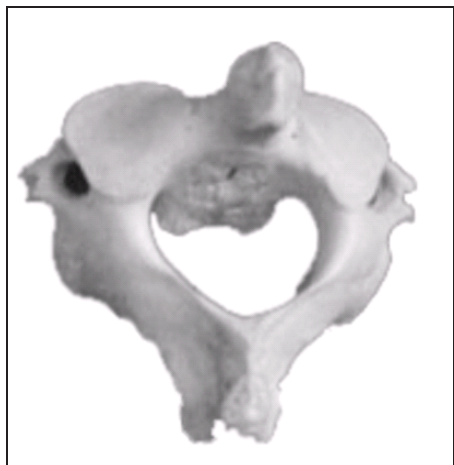4-53. The seven cervical vertebrae (C1–C7) are the smallest of the vertebrae and provide a great deal of flexibility. Two cervical vertebrae are unique—the first cervical vertebra (the atlas) and the second cervical vertebra (the axis). The remaining five (C3–C7) share similar anatomical features.

4-54. The atlas (C1) has no body and no spinous process (figure 4-10). It is basically a ring upon which the condyles of the occipital bone rest. It consists of anterior and posterior arches and a lateral mass on each side. When the head moves up and down it does so mainly at this joint.

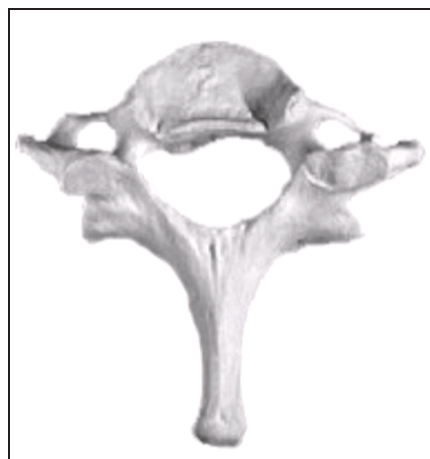

**Figure 4-10. The Atlas, C1, Superior View**

4-55. The axis (C2) has a peg-shaped (odontoid) process that acts as a pivot for the skull to rotate about when the head turns from side to side (figure 4-11).



**Figure 4-11. The Axis, C2, Superior View**



**Figure 4-12. The Seventh Cervical Vertebra, Superior View**

4-56. The seventh cervical vertebra (C7) is the largest of the cervical vertebrae (figure 4-12) and is, therefore, easily distinguished from the other cervical vertebrae. It has the largest body and the longest spinous process. Because C7 is transitional between the cervical and thoracic vertebrae, it exhibits characteristics of both.

4-57. All cervical vertebrae have transverse foramina for the vertebral arteries (figure 4-13). The spinous processes are short and small and project posterior. The body is small and broader in a medial-lateral (side to side) direction than in an anterior-posterior (front to back) direction. The vertebral foramen is large and rather triangular in shape. The transverse processes are small. The cervical vertebrae increase in size from above downward.

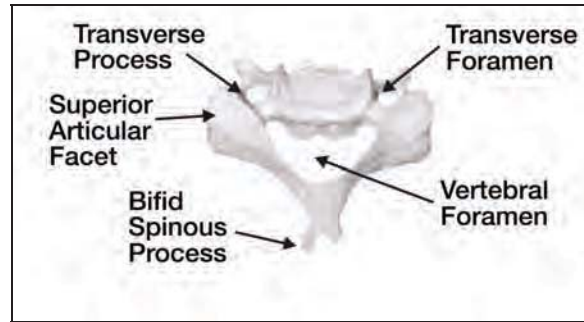


Figure 4-13. Typical Cervical Vertebra, Superior View

### Thoracic Vertebrae

4-58. The 12 thoracic vertebrae (T1-T12) support and articulate with the ribs (figure 4-14 and figure 4-15). Thus thoracic vertebrae can be distinguished by the presence of demi-facets on each side of the vertebral body where the heads of the ribs articulate. There are costal articulations on the transverse processes where the tubercles of the ribs articulate. The bodies are heart-shaped and increase in size from above downward. There are no transverse foramina. The vertebral foramina are relatively small and circular. The spinous processes are long, straight, and narrow and project inferiorly.

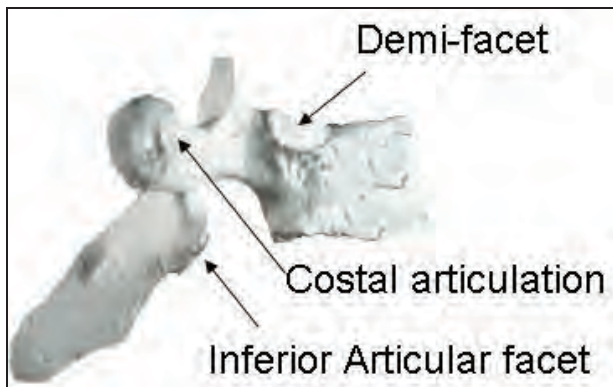


Figure 4-14. Typical Thoracic Vertebra, Lateral View

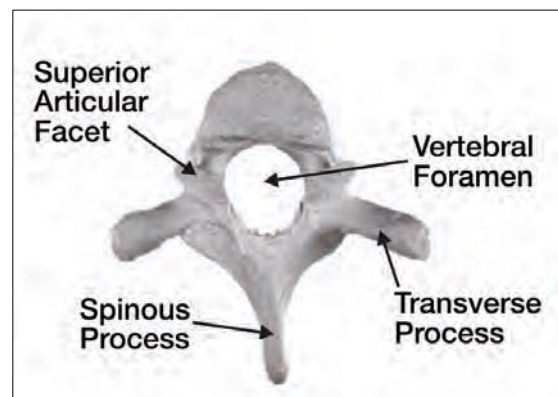


Figure 4-15. Typical Thoracic Vertebra, Superior View

### Lumbar Vertebrae

4-59. The five lumbar vertebrae (L1-L5) are the largest of the vertebrae (figure 4-16 and figure 4-17). The bodies are large and roughly kidney-shaped. Like the cervical and thoracic vertebrae, the lumbar vertebrae increase in size from above downward. There are no transverse foramina and no costal facets. The spinous processes are large, short and blunt and give a rectangular-like appearance.

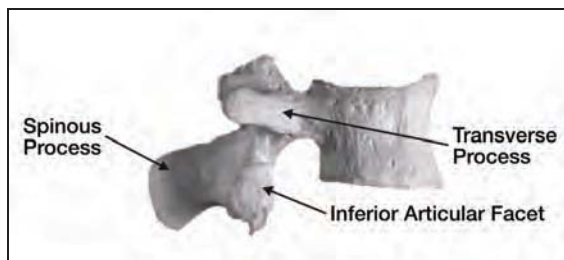


Figure 4-16. Typical Lumbar Vertebra, Lateral View

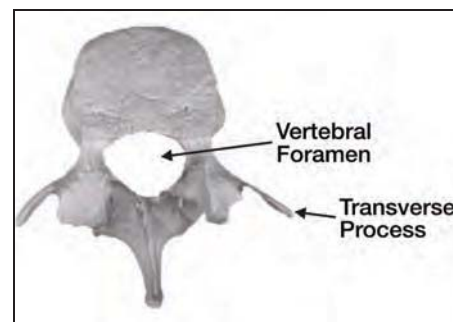


Figure 4-17. Typical Lumbar Vertebra, Superior View

**Chapter 4****STERNUM**

4-60. The sternum (breastbone) is a flat bone located in the midline of the chest, immediately beneath the skin (figure 4-18). The sternum is made up of three parts—the manubrium (superior), the body as the main portion, and the xiphoid process (inferior). The first seven ribs articulate with the manubrium and the body via cartilage at the costal notches. The medial end of each clavicle articulates with the manubrium. The xiphoid process anchors the muscles that are responsible for much of the muscular expansion and contraction of the abdomen.

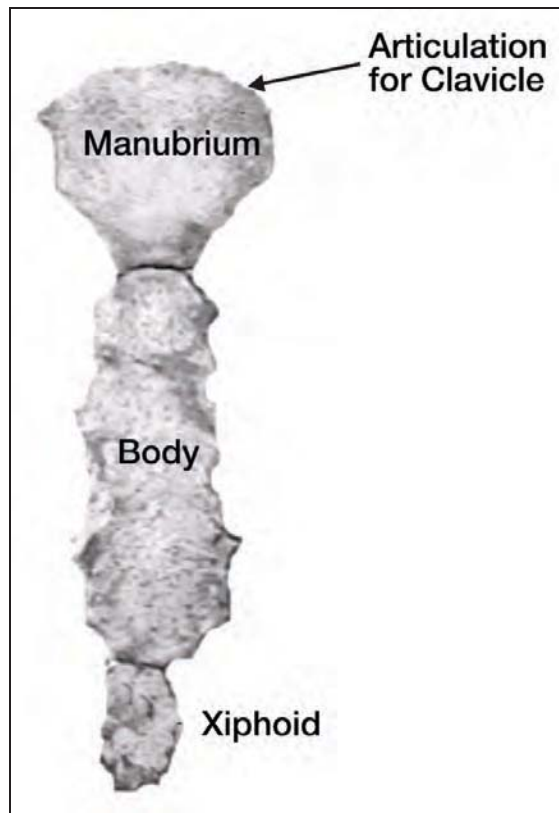


Figure 4-18. The Sternum, Anterior View

**RIBS**

4-61. There are 12 pairs of ribs that articulate with the thoracic vertebrae. The first seven pairs (ribs 1 through 7) are termed “true” ribs as they articulate directly with the sternum via cartilage. Ribs 8, 9, and 10 are termed “false” ribs as they attach ventrally to each other and the seventh rib by common cartilages. Ribs 11 and 12 are termed “floating” ribs, as the ventral ends are free-floating.

4-62. The typical rib is a long, twisted, flat bone with a round, smooth superior border and a sharp inferior border (figure 4-19). A rib has a head, neck, tubercle, and a shaft (or body). The head is dorsal and has two facets for articulation with the thoracic vertebrae. The neck is the constricted portion between the head and the tubercle. The tubercle is a prominence on the outer surface of the rib at the junction of the neck with the shaft. The shaft is the thin, curved, tapering portion between the tubercle and the ventral (sternal) end of the rib.



Figure 4-19. A Typical Rib (Left)

4-63. The first rib is atypical. It is the most curved, broadest, and shortest of the ribs (figure 4-20). It is flattened superoinferiorly (from above downward). The head usually only has one articular facet. The superior surface is roughened by muscle attachments and contains two shallow grooves, one each for the subclavian vein and artery.

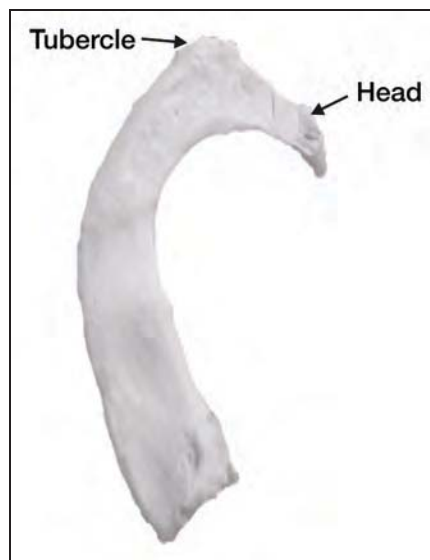


Figure 4-20. The First Right Rib, Superior View

## SCAPULA

4-64. The scapula (shoulder blade) is a large, flat, triangular bone (figure 4-21 and figure 4-22). It lies on the dorsal side of the thorax between the second and seventh rib. The scapula has two surfaces (anterior and posterior), three borders, and two processes. The borders are the vertebral (medial) border, which is the longest and thinnest; the axillary (lateral) border, which is the thickest; and the superior border, which is the shortest. On the dorsal surface is the spine, a process that runs laterally and ends in the acromion (which articulates with the clavicle). The coracoid process projects anteriorly from the superior border and provides attachment for muscles and ligaments. The scapula articulates with the humerus through the glenoid cavity.

## Chapter 4

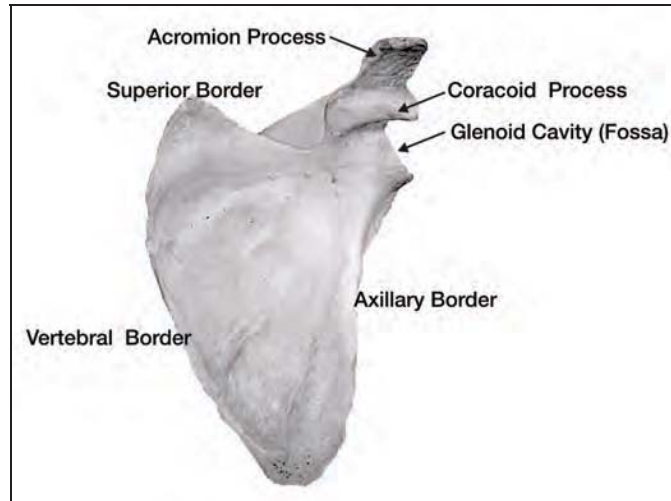


Figure 4-21. The Left Scapula, Anterior Surface

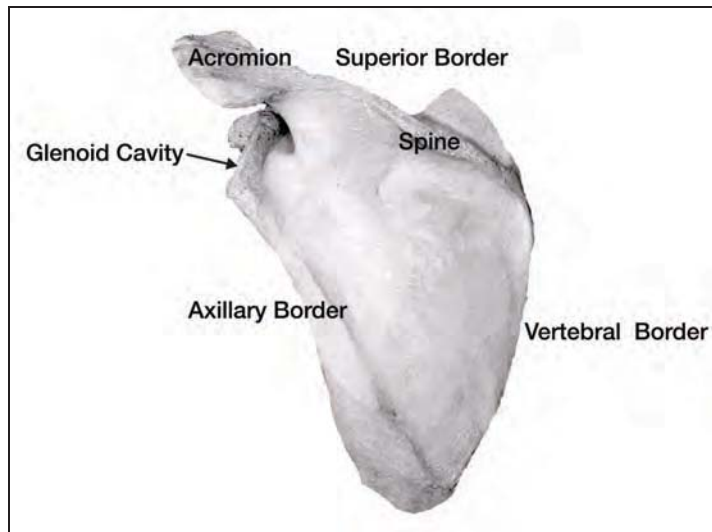


Figure 4-22. The Left Scapula, Posterior Surface

**CLAVICLE**

4-65. The clavicle (collar bone) is a long, tubular, curving, S-shaped bone (figure 4-23). It is situated just above the first rib on each side of the rib cage. The medial end is rounded and the lateral end is flattened. The clavicle articulates medially with the manubrium and laterally with the acromion process of the scapula. The clavicle acts as a brace for the scapula and provides attachment for muscles. Each respective clavicle and scapula together forms the pectoral (shoulder) girdle.



Figure 4-23. The Left Clavicle



## HUMERUS

4-66. The humerus is the bone of the upper arm (figure 4-24 and figure 4-25). It is the largest and longest bone in the upper extremity. The proximal end of the humerus consists of a head (which articulates with the glenoid cavity of the scapula), a neck, and the greater and lesser tubercles. The deltoid tuberosity, the area for attachment of the deltoid muscle, is located approximately on the proximal one third of lateral shaft. The lateral and medial epicondyles provide attachments for muscles and ligaments. The capitulum is a rounded eminence on the lateral side of the distal humerus. It articulates with the radius. The trochlea is a spool-shaped eminence on the medial side of the distal humerus. It articulates with the ulna. The olecranon fossa accommodates the olecranon process of the ulna when the forearm is extended.

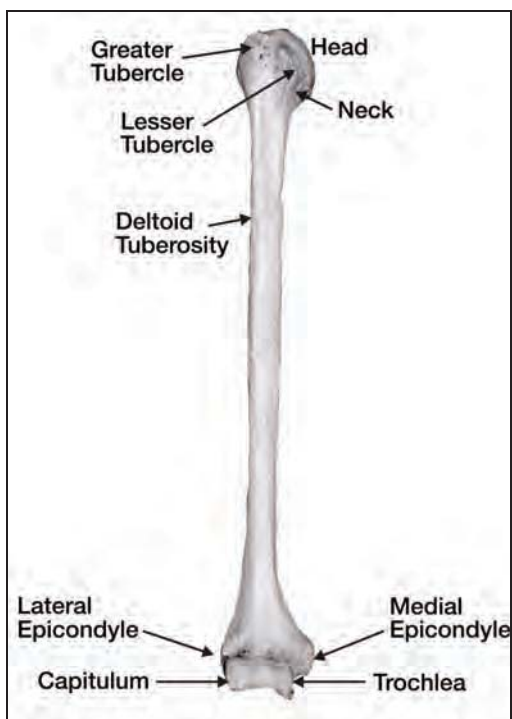


Figure 4-24. The Right Humerus, Anterior View

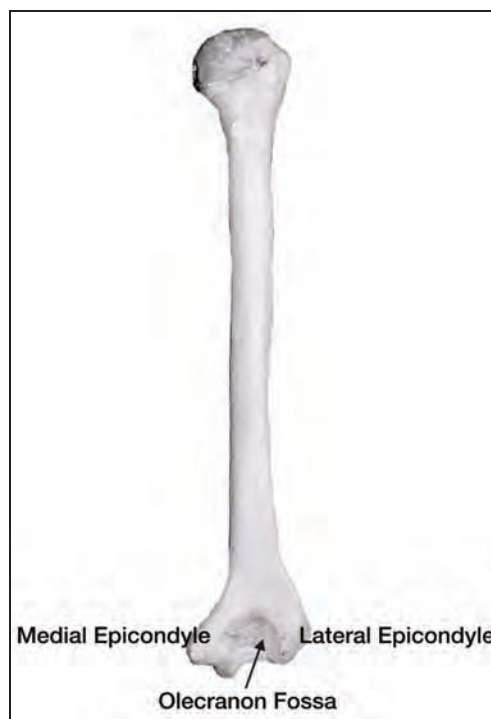

Figure 4-25. The Right Humerus, Posterior View

## RADIUS

4-67. The radius is on the lateral (thumb) side of the lower arm when the arm is in anatomical position (figure 4-26 and figure 4-27). When the arm is pronated (palm turned down) the radius crosses over the ulna. The radius is the shortest of the three arm bones. Distinguishing features of the proximal radius include the head and the radial tuberosity. The head is rounded and concave and articulates with the capitulum of the humerus. The radial tuberosity is a roughened area for muscle attachment. Distinguishing features of the distal radius include the styloid process and the ulnar notch. The styloid process is a projection on the lateral side. The ulnar notch is on the medial side for articulation with the ulna. The distal end articulates with two carpal (wrist) bones. The interosseous crest is the sharp medial edge of the shaft.

## Chapter 4




Figure 4-26. The Right Radius, Anterior View

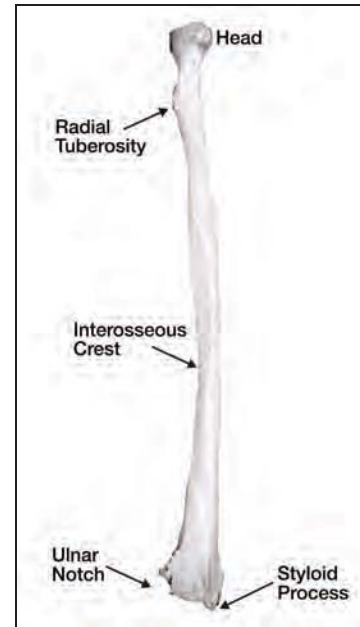


Figure 4-27. The Right Radius, Posterior View

**ULNA**

4-68. The ulna is the longest and thinnest of the bones of the forearm (figure 4-28 and figure 4-29). The proximal shaft is large but tapers to a small distal end. In anatomical position, it is on the medial (little finger) side of the forearm. Proximally, the ulna articulates with the humerus at the trochlea and laterally with the radius at both the proximal and distal ends. The olecranon process—the large, irregular C-shaped proximal end—fits into the olecranon fossa of the humerus. The distal shaft is small and consists of the small rounded head. The styloid process projects from the medial aspect. The interosseous crest is the sharp lateral edge of the shaft.




Figure 4-28. The Right Ulna, Lateral View




Figure 4-29. The Right Ulna, Anterior View

## HAND

4-69. Each hand consists of 27 major bones, which are categorized as carpals, metacarpals, and phalanges (figure 4-30). There are also small sesamoid bones that lie within the hand tendons.

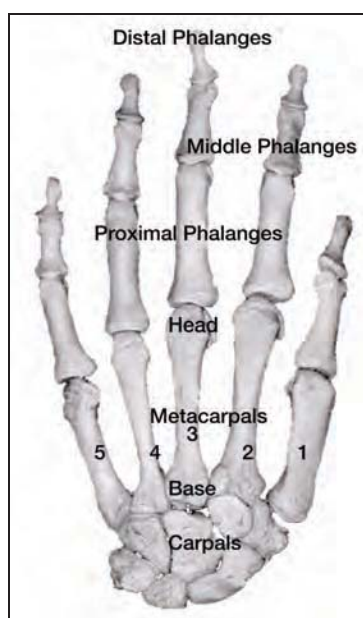


Figure 4-30. The Left Hand, Dorsal View

**Chapter 4**

4-70. The eight carpal bones together form the carpus (wrist). Each carpal bone is unique with numerous articular surfaces. They articulate with the radius and the metacarpals.

4-71. There are five metacarpal bones in the palm. They are numbered one through five, starting on the “thumb” side with number one and ending on the “little finger” side with number five. Each is cylindrical in shape and presents a head, a shaft, and a base. The heads are the rounded distal ends (which form the ‘knuckles’ when a fist is made). The bases are the proximal square-like ends that articulate with the carpal bones.

4-72. Each hand has 14 hand phalanges (the finger bones). The phalanges of digits two through five are arranged in three rows—proximal, middle, and distal. The first metacarpal (thumb) has two phalanges—proximal and distal. (The singular of phalanges is phalanx.)

**PELVIC GIRDLE**

4-73. The sacrum, the coccyx, and the os coxae form the pelvic girdle.

**Sacrum**

4-74. The sacrum is typically composed of five separate vertebrae that fuse during adulthood into an immobile bone (figure 4-31 and figure 4-32). It is a large, wedge-shaped bone that is concave ventrally. There are four foramina that perforate the sacrum and through which pass the sacral nerves. The superior border articulates with the fifth lumbar vertebra. The ala is wing-like lateral projection off the first sacral element. Laterally the sacrum articulates with the os coxa at the sacroiliac joint. Inferiorly the sacrum articulates with the coccyx. There is a median crest (spine) on the dorsal aspect of the sacrum, which is formed by the fusion of the spinous processes of the vertebrae. Beneath this crest is the sacral canal, which holds nerve roots.

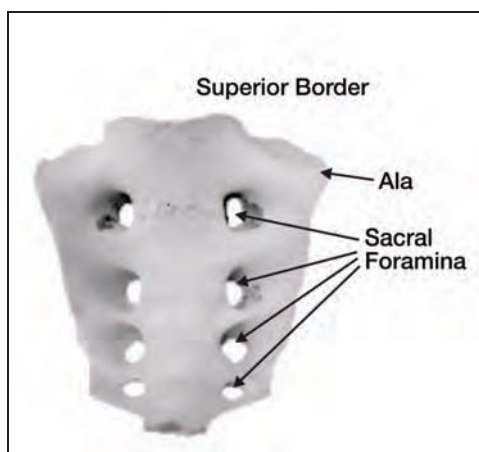


Figure 4-31. The Sacrum, Ventral View

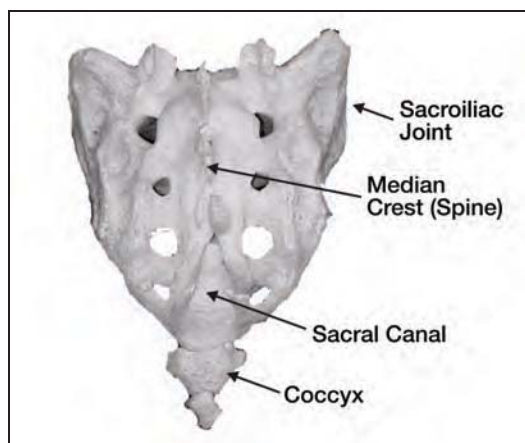


Figure 4-32. The Sacrum and Coccyx, Dorsal View

**Coccyx**

4-75. The coccyx (tail bone) is highly variable in shape (figure 4-32). It can consist of three to five segments with four elements representing the norm. Pelvic muscles and ligaments attach to the coccyx. The elements of the coccyx can, but do not always, fuse with each other and the sacrum.

## Os coxa

4-76. The os coxa (hip/pelvis) is a large irregular bone that has at times been called the innominate—meaning nameless—because it does not resemble any common object. The os coxae (plural) articulate with the sacrum and with each other. Each os coxa is composed of an ilium, ischium, and pubis (figure 4-33 and figure 4-34).

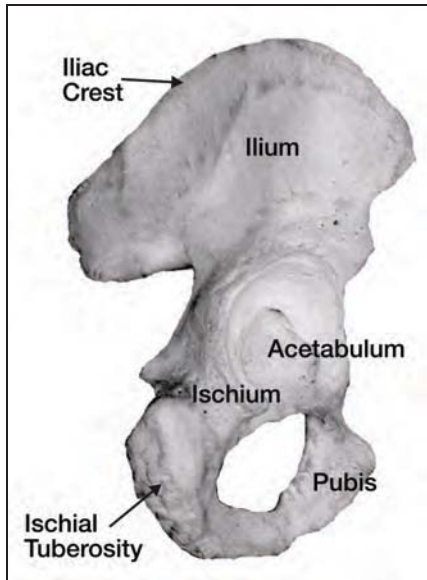


Figure 4-33. The Right Os Coxa Lateral View

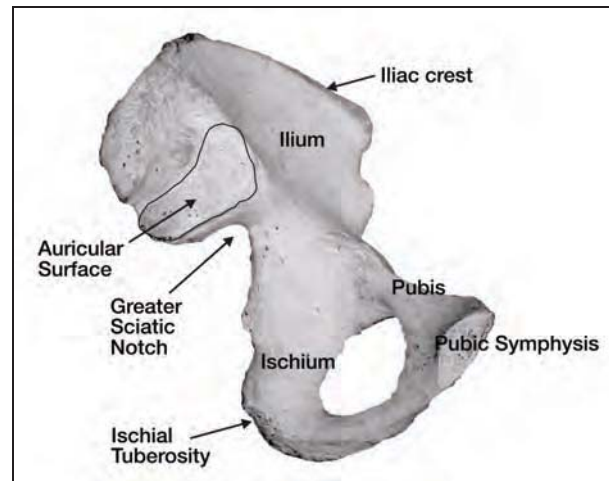


Figure 4-34. The Left Os Coxa, Medial View

4-77. The ilium is the largest portion of the os coxa. It is the upper broad, flattened, blade-like portion of the bone. The ilium flares outward to give the hip prominence. The superior border of the ilium is called the iliac crest. The auricular surface articulates with the sacrum.

4-78. The ischium is the L-shaped inferior, posterior portion of the bone. The ischial tuberosity is blunt and thick and bears the weight when sitting.

4-79. The pubis is the anterior portion of the os coxa. It contains the pubic symphysis, the surface where the os coxae articulate with one another. The ilium, ischium, and pubis meet and join to form the acetabulum. The acetabulum is the socket of the hip that faces laterally and articulates with the head of the femur.

## FEMUR

4-80. The femur (thigh bone) is the largest, heaviest, longest, and strongest bone in the body (figure 4-35 and figure 4-36). Proximally, the femoral head articulates with the acetabulum. Proximal characteristics are the head, neck and the greater and lesser trochanters—large eminences, which provide places for muscle attachments. Distally it articulates with the patella and proximal tibia. The anterior shaft is smooth and rounded. The linea aspera is a wide crest or ridge on the posterior shaft that serves as a place of attachment for several muscles. Distally the femur has lateral and medial condyles. The patellar surface separates the condyles on the anterior surface. The intercondylar notch (or fossa) separates the condyles on the posterior surface.

## Chapter 4

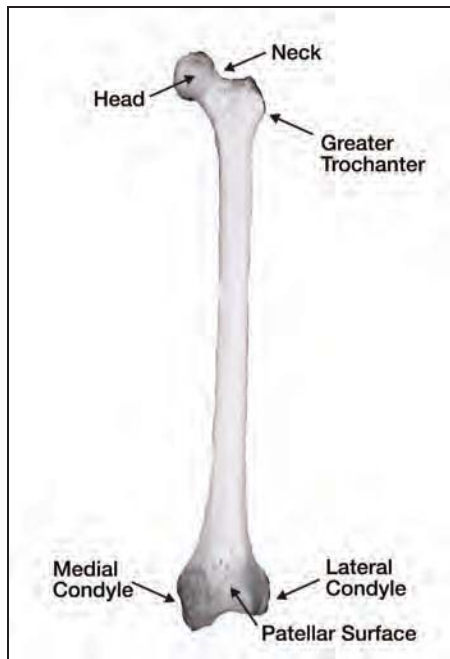


Figure 4-35. The Left Femur, Anterior View

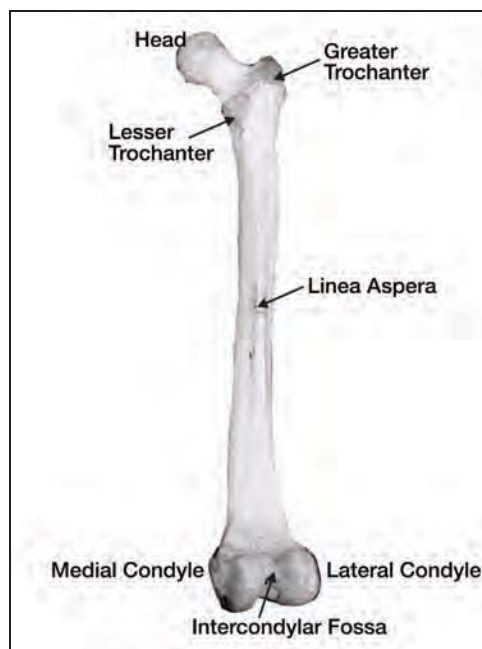


Figure 4-36. The Right Femur, Posterior View

**PATELLA**

4-81. The patella (kneecap) is a small triangular sesamoid bone—a bone that develops in a tendon that moves over a bony surface (figure 4-37 and figure 4-38). The apex points inferiorly. The thick base is proximal. The dorsal surface articulates with the patellar surface of the femur.




Figure 4-37. The Right Patella, Ventral View

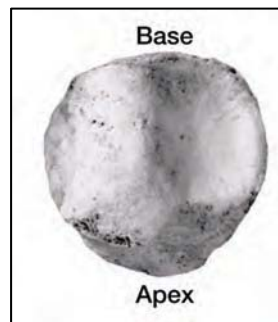


Figure 4-38. The Right Patella, Dorsal View

**Tibia**

4-82. The tibia (shinbone) is the medial and larger bone of the lower leg (figure 4-39 and figure 4-40). Proximally, the medial and lateral condyles articulate with the condyles of the distal femur. Separating the medial and lateral condyles is the intercondylar eminence, a raised area. The inferior lateral aspect of the lateral condyle has a circular articular facet for the articulation with the head of the fibula. The prominent anterior crest forms the “shin.” Distally, the tibia articulates with the fibula and the talus of the foot. The medial malleolus is the projection on the medial side of the distal tibia, the medial bulge of the “ankle.”

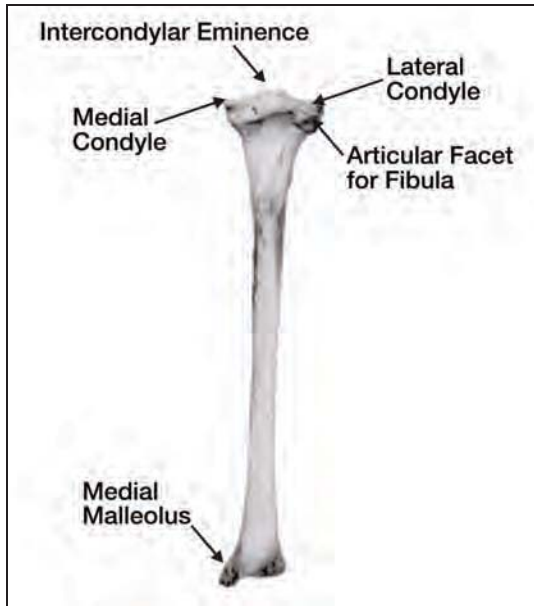


Figure 4-39. The Right Tibia, Posterior View

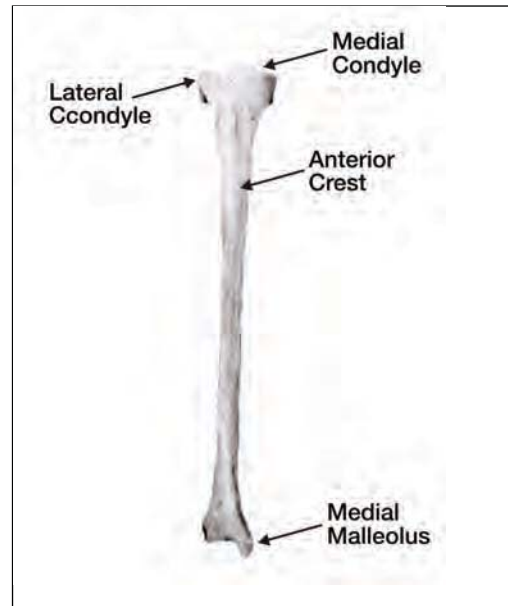


Figure 4-40. The Right Tibia, Anterior View

## FIBULA

4-83. The fibula is the lateral bone of the lower leg (figure 4-41 and figure 4-42). The proximal end is called the head with a projection called the styloid process. The shaft is long and slender with much individual variation in shape. The distal end of the fibula articulates with the tibia and talus. It forms a triangular lateral malleolus, the lateral bulge of the ankle.




Figure 4-41. The Right Fibula, Dorsal View




Figure 4-42. The Right Fibula, Medial View

**Chapter 4****FOOT**

4-84. There are 26 major bones in each foot (one less than in each hand). The foot bones are categorized as tarsals, metatarsals, and phalanges (figure 4-43). There are also small sesamoid bones that lie within the foot tendons.

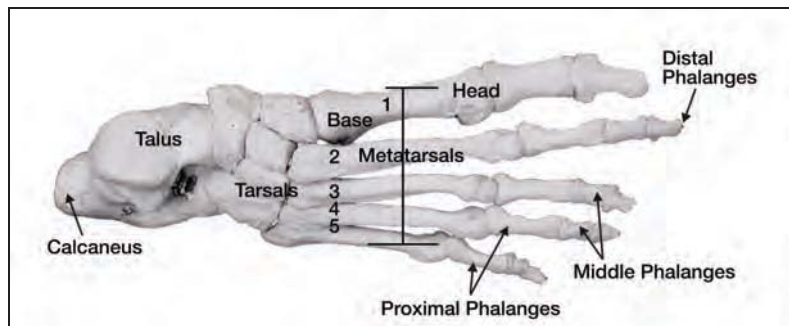


Figure 4-43. The Right Foot, Dorsal View

**Tarsal**

4-85. The seven tarsal bones combine with the metatarsals to form the arches (medial arch and anterior arch) of the foot. The talus is the tarsal bone that articulates with the distal tibia and fibula. The calcaneus (heel bone) is the largest tarsal bone.

**Metatarsals**

4-86. The metatarsals are numbered one through five, starting on the “big toe” side with number one and ending on the “little toe” side with number five. Each is tubular in shape and presents a head, a shaft, and a base. The head is the rounded distal end. The base is the proximal square-like end.

**Phalanges**

4-87. Each foot has 14 phalanges (the toe bones). The phalanges of digits two through five are arranged in three rows—proximal, middle, and distal. The first metatarsal has two phalanges—proximal and distal.

**FETAL AND IMMATURE SKELETON**

4-88. In the normal operating theater the mortuary affairs specialist may never encounter skeletal fetal remains. Therefore, a detailed description of such remains is not necessary. There may be, however, circumstances in which a basic knowledge of fetal remains may be beneficial to case resolution in a field and/or mortuary setting.

4-89. It is important to remember that fetal skeletal remains are extremely fragile and friable. They are very small, thin bones that disintegrate easily (figure 4-44).

4-90. To the untrained eye, fetal skeletal remains may not even resemble human bone. Because the bones of the human skeleton develop from a number of separate centers of ossification and growth, the newborn skeleton includes many bones that are separated into numerous parts. For example, the fetal occipital bone develops from four parts; the scapula develops from nine parts; and the humerus from eight parts.

4-91. Most of the bones in the skeleton grow through a process of ossification, in which bones are preceded by cartilage precursors. Ossification of the cartilage starts before birth. During ossification the cartilage takes on the characteristic shape of the bone and is replaced by bony tissue. The process of ossification of human bone is complicated. For example, 11 weeks before birth there are approximately 806 centers of bone growth. As the skeleton grows, the centers unite so that by birth there are about 450. Over the years the process of ossification culminates in the typical 206 bones of the human adult skeleton.



4-92. The typical subadult long bone basically consists of three centers of ossification—termed primary and secondary centers. The primary center of ossification is the diaphysis (shaft) of the long bone. The secondary centers are the epiphyses. There is a layer of cartilage between the diaphysis and epiphyses known as an epiphyseal plate or growth plate. This plate is a cartilaginous center that allows for growth. Epiphyses are present at each end of the long bones, on the superior and inferior faces of the vertebral bodies, and in certain other locations where special processes are required for the attachment of muscles.

4-93. In the early stages of ossification, the epiphyses are difficult to distinguish. The epiphyses are typically rounded, lacking the more mature shape. To an untrained observer they will not be recognized as human bone. As the epiphyses grow, they begin to take on adult characteristics.

4-94. As the individual matures, the individual bones grow in size and shape and progressively take on the appearance of the adult bone. Before adolescence, many of the small secondary centers of ossification in the long bones have fused to the bone, leaving only the proximal and distal epiphyses of the long bones unfused to the shaft. Before adolescence, the flat bones and the irregular bones have also assumed their adult shape, leaving only the epiphyses unfused. Later, the epiphyses fuse with the main center to form one complete bone (figure 4-45).

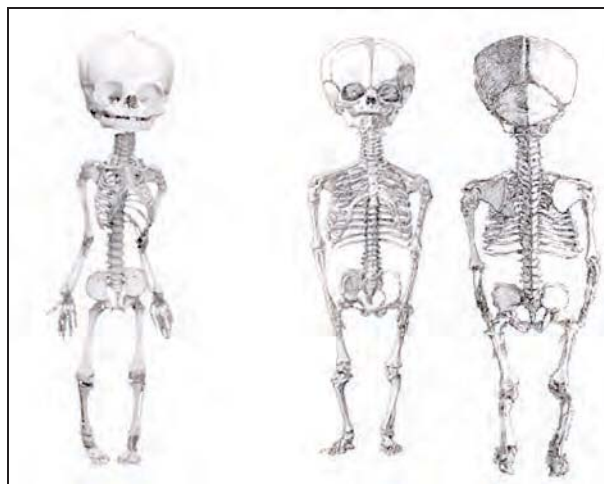


Figure 4-44. The Fetal Skeleton

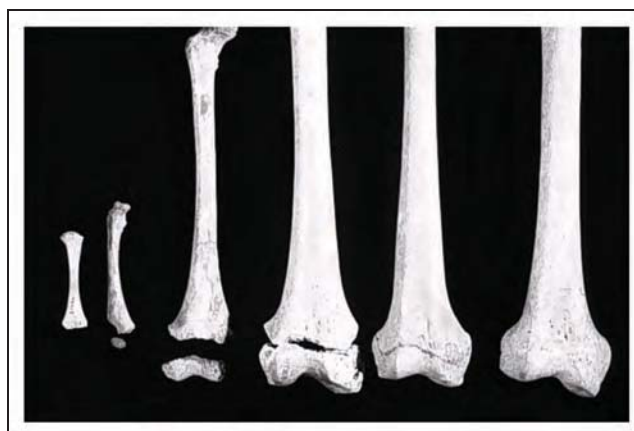

Figure 4-45. From Left to Right: Fetal Femur Diaphysis; Juvenile Femur with Appearance of Epiphyses; Adolescent Femur; Subadult Femur; Subadult Femur (Note Recent Fusion of Epiphysis to Diaphysis); Adult Femur

**This page intentionally left blank.**

## Chapter 5

# DENTAL ANATOMY AND MORPHOLOGY

### OBJECTIVE

5-1. To provide the mortuary affairs Soldier with knowledge of the human dentition to be able to assist proficiently in recovering disassociated dental remains.

### GLOSSARY OF ODONTOLOGICAL AND ANATOMICAL TERMINOLOGY

5-2. Odontologists and anthropologists use a specific standardized vocabulary to describe the human dentition. Standardized terminology facilitates unambiguous communication among all examiners and researchers (see figure 5-1).

#### ALVEOLAR PROCESS

5-3. The alveolar process is the ridge of bone in the maxilla and mandible that contains the alveoli.

#### ALVEOLUS (SINGULAR), ALVEOLI (PLURAL)

5-4. The alveolus is a single tooth socket; the cavity in which the root of a tooth is held in the alveolar process.

#### APEX

5-5. The apex is the terminal or pointed end of the tooth root.

#### CEMENTUM

5-6. Cementum is the bone-like tissue that covers the root of a tooth.

#### CROWN

5-7. The crown is that part of the tooth covered by enamel (anatomical). It is the portion of the tooth that is visible in the mouth (clinical).

#### CUSP

5-8. A cusp is a conical or cone-shaped elevation on the occlusal surface of the premolars and molars and on the incisal edge of the canines.

#### DECIDUOUS DENTITION

5-9. The deciduous dentition are the primary (baby) teeth. They are the first to form, erupt, and function. There are twenty deciduous teeth. They are shed and replaced by the permanent dentition.

**Chapter 5**

---

**DENTIN**

5-10. Dentin (or dentine) is the hard tissue that forms the main body of the tooth. It surrounds the pulp cavity and is covered by enamel in the anatomical crown. Wear of the occlusal surface of a tooth may expose dentin.

**DENTITION**

5-11. All the teeth considered collectively in place in the maxilla and mandible.

**EDENTULOUS**

5-12. Edentulous means without teeth. It may refer to the loss of all the maxillary and/or mandibular teeth.

**ENAMEL**

5-13. The white mineralized tissue that covers the dentin of the anatomical crown of the tooth.

**FORENSIC ODONTOLOGIST**

5-14. A forensic odontologist practices forensic odontology. Forensic odontology is a branch of forensic medicine and, in the interests of justice, deals with a specialized interest in identification and the proper examination, handling, and presentation of dental evidence in a court of law.

**NECK**

5-15. The neck is the constricted part of the tooth at the junction of the crown and root.

**ODONTOLOGY**

5-16. Odontology is the study of the development, formation, and abnormalities of the teeth.

**PERMANENT DENTITION**

5-17. The permanent dentition are the adult teeth, which are 32 in number.

**PULP**

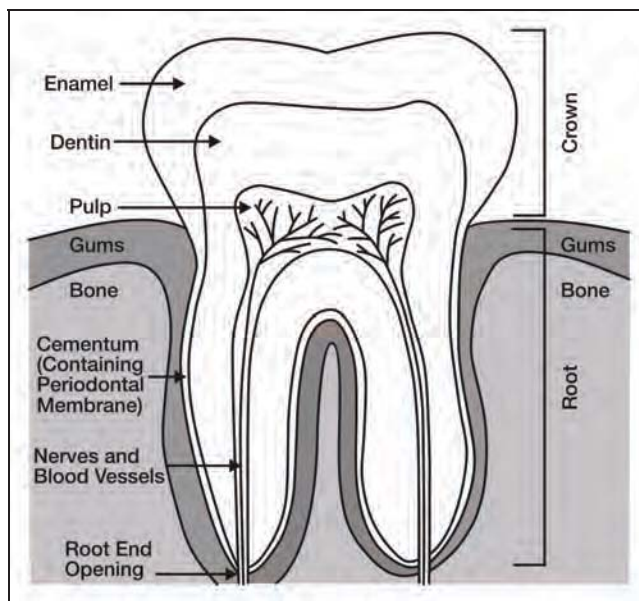
5-18. Pulp is the soft tissue that constitutes the central cavity of the tooth. It includes nerves and blood vessels.

**PULP CAVITY**

5-19. The pulp cavity is the entire central cavity of a tooth, which contains the pulp.

**ROOT**

5-20. The root is the part of the tooth that anchors the tooth in the alveolus. It is covered by cementum. The root is not visible in the mouth.

Figure 5-1. Tooth Anatomy<sup>8</sup>

## TOOTH SURFACES

5-21. While the vocabulary for the surfaces of the anterior and posterior teeth is basically the same, there are some differences.

### ANTERIOR

5-22. The anterior teeth (incisors and canines) have four surfaces (mesial, distal, facial, and lingual) and one edge on their crowns (figure 5-2). As a group, the anterior teeth have single roots and incisal edges or single-cusped crowns ending in narrow edges designed to incise or bite off relatively large amounts of food. They are aligned to form a smooth curving arch from the distal surface of the canine on one side of the arch to the distal surface of the canine on the opposite side.

- Mesial is the surface nearest the midline of the dental arch.
- Distal is the surface farthest from the midline.
- Facial (or labial) is the surface toward the lips (outside). The terms “facial” and “labial” are used interchangeably. However, the term “facial” will be used in this manual for consistency in identifying dental remains.
- Lingual is the surface toward the tongue (inside).
- Incisal edge or surface is the biting edge of the anterior teeth.

<sup>10</sup>Ms. Jeananda Col

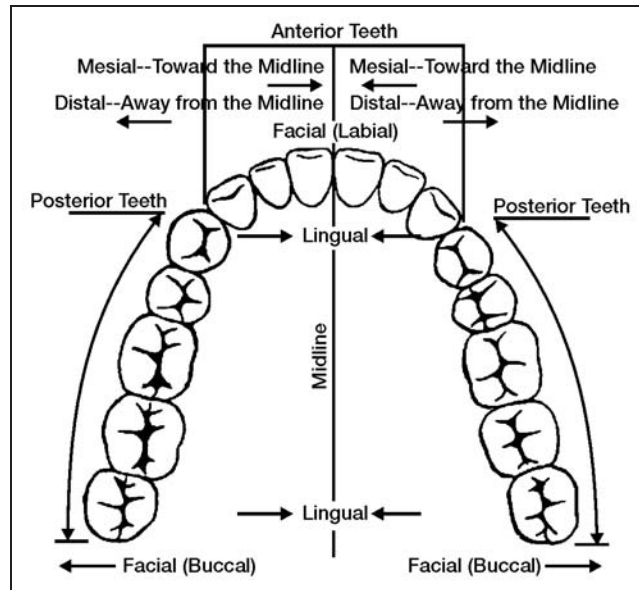
**Chapter 5**

Figure 5-2. Tooth Surfaces

**POSTERIOR**

5-23. The posterior teeth (premolars and molars) have five surfaces on their crowns. Posterior teeth differ from anterior teeth in that they have more than one root, they have multiple cusps forming occlusal surfaces designed to crush and grind food to small parts, and the part of the dental arch that they form has little or no curvature.

5-24. Mesial, distal, and lingual are the same surfaces as defined for the anterior teeth.

5-25. Facial (or buccal) is the surface toward the cheeks (corresponds to facial in the anterior teeth). The terms “facial” and “buccal” are used interchangeably. However, the term “facial” will be used in this manual for consistency in charting dental remains.

5-26. Occlusal is the chewing surface of the posterior teeth.

**TEETH CLASSIFICATION**

5-27. The teeth are arranged in two arches—upper and lower. The upper arch teeth are termed maxillary. The lower arch teeth are termed mandibular. There is an imaginary vertical line called the midline that divides each arch into two halves. The halves in each arch are called quadrants. Thus, there are four quadrants in the mouth—the upper right and upper left (maxillary) and the lower right and lower left (mandibular).

**DECIDUOUS DENTITION**

5-28. Each quadrant of the deciduous dentition contains 5 teeth, for a total of 20 teeth. There are three types of deciduous teeth—the incisors, canines, and molars (figure 5-3). The number in parentheses following the tooth name indicates how many of each tooth is represented in each quadrant.

- Incisors (2). The two teeth in each quadrant which are closest to the midline. They are named central (immediately adjacent to midline) and lateral incisors.
- Canine/cuspid (1). The third tooth from midline in each quadrant.
- Molars (2). These first and second molars are the fourth and fifth teeth from midline in each quadrant.

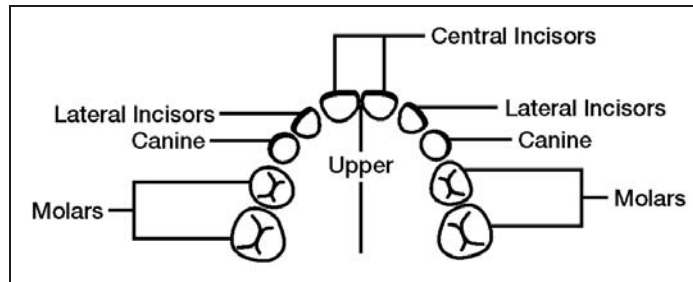


Figure 5-3. Classification of Deciduous Dentition

## PERMANENT DENTITION

5-29. Each quadrant of the permanent dentition contains 8 teeth, for a total of 32 teeth. There are four types of permanent teeth—the incisors, canines/cuspid, premolars/bicuspid, and molars (figure 5-4). The number in parentheses following the tooth name indicates how many of each tooth is represented in each quadrant.

- Incisors (2). The two teeth in each quadrant, which are closest to the midline. They are named central (immediately adjacent to midline) and lateral incisors. The incisor crowns are flat and blade-like, as they are designed for cutting and incising.
- Canine/cuspid (1). The third tooth from midline in each quadrant. The tooth is conical with a pointed cusp. The canines are designed for tearing, piercing, and holding.
- Premolars/biscupids (2). These first and second premolars are the fourth and fifth teeth from midline in each quadrant. The crowns are round with broad occlusal surfaces. They usually have two cusps and are also called bicuspid. The premolars are designed for grinding and reducing food material.
- Molars (3). These first, second, and third molars are the sixth, seventh, and eighth teeth from midline in each quadrant. The crowns are larger and squarer and have more cusps than the other teeth. Molars typically have four cusps and multiple roots. The molars are designed for crushing, grinding, and reducing food material.

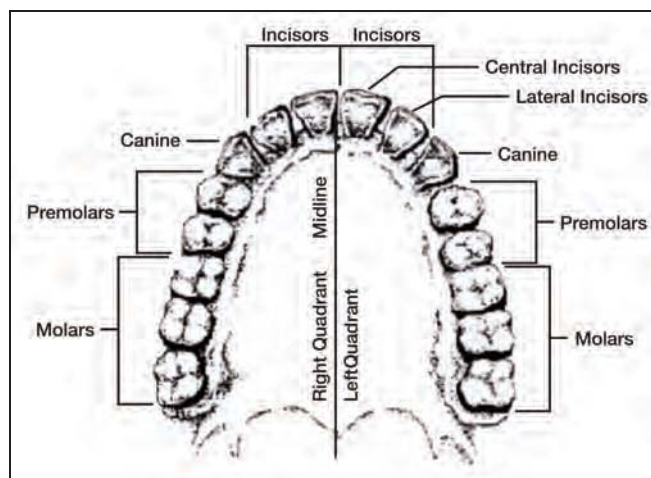


Figure 5-4. Classification of the Permanent Dentition (Maxillary)

## UNIVERSAL NUMBERING SYSTEM

5-30. Each tooth is assigned a number to simplify its designation (figure 5-5 and figure 5-6). Instead of writing out the name for the tooth, it is customary to assign a number, letter, or symbol to the tooth in question. The universal numbering system is the one with the most wide-spread usage and is the system

**Chapter 5**

used by the armed services. It assigns a different number in a consecutive arrangement for all the permanent teeth and a number-letter to each of the deciduous teeth.

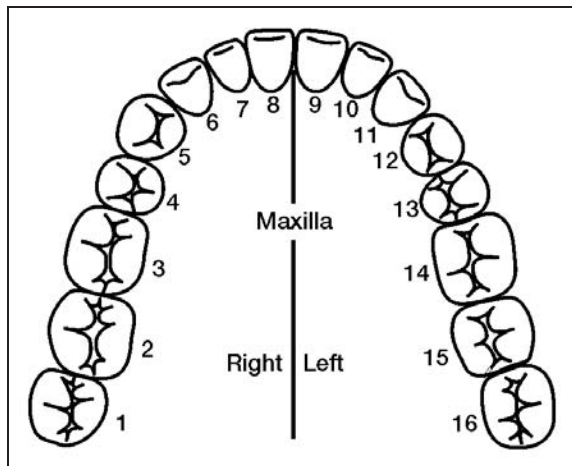


Figure 5-5. Maxillary Permanent Dentition

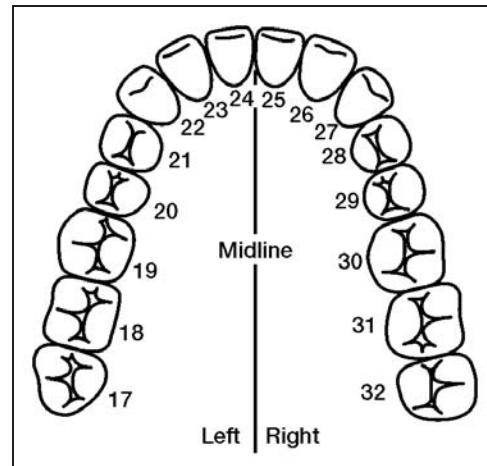


Figure 5-6. Mandibular Permanent Dentition

5-31. For the permanent dentition the numbering begins with the upper right third molar (#1) and continues around the maxillary arch to the upper left third molar (#16). At this point the succession drops to the lower left third molar (#17) and continues around the mandibular arch to the lower right third molar (#32).

5-32. The 20 deciduous teeth are numbered in the same manner (1-20), but a small (d) is added to the number as a suffix to designate deciduous. For example, the upper right second molar is #1d, the upper left second molar is #10d, the lower left second molar is #11d, and the lower right second molar is #20d (see figure 5-7).

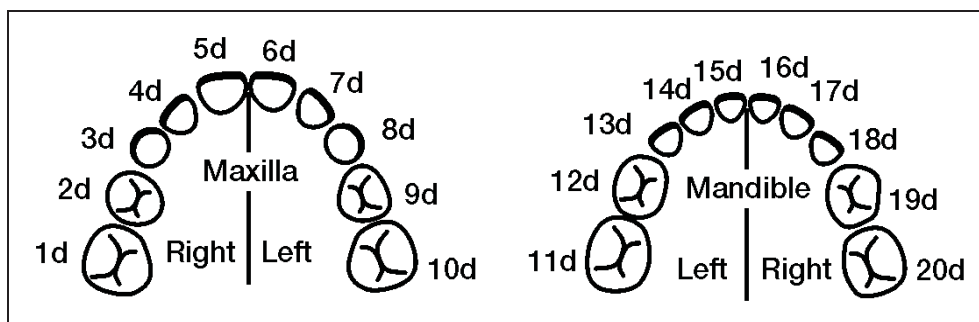


Figure 5-7. Deciduous Dentition

## DECIDUOUS DENTITION

5-33. There are three types of deciduous teeth—the incisors, canines/cuspids, and molars. There are no premolars/bicuspid. The functional role of the deciduous teeth is similar to the function of the permanent dentition.

5-34. Individual descriptions of the deciduous dentition will not be given. For general considerations, with the exception of the deciduous first molars, the deciduous teeth are smaller counterparts of the permanent dentition. The deciduous incisors and canines/cuspids are virtually identical to their permanent counterparts. The deciduous second molars very closely resemble the permanent first molars.



5-35. The deciduous first molars do not resemble any of the other teeth, deciduous or permanent. They are the precursors of the permanent premolars. Thus the crowns of the deciduous maxillary and mandibular first molars do not resemble any other permanent molar crown.

5-36. The crowns of deciduous teeth are lighter in color than the permanent teeth. They exhibit a bluish-white cast compared to the grayish-white color of the permanent teeth.

## PERMANENT DENTITION

### MAXILLARY AND MANDIBULAR INCISORS

5-37. The incisors are the two teeth in each quadrant—closest to the midline—on either side of the midline in the maxilla and mandible. They have single roots, and the crowns present a sharp incisal ridge or edge. The lingual surface may be shovel-shaped. The mandibular incisors are smaller than the maxillary incisors.

5-38. The permanent maxillary central incisors (figure 5-8) are located adjacent to the midline on the anterior portion of the maxillary dental arch. They are the largest of the incisors. The crowns are greater than those of the maxillary lateral incisors. The universal numbers are #8 (r) and #9 (l).

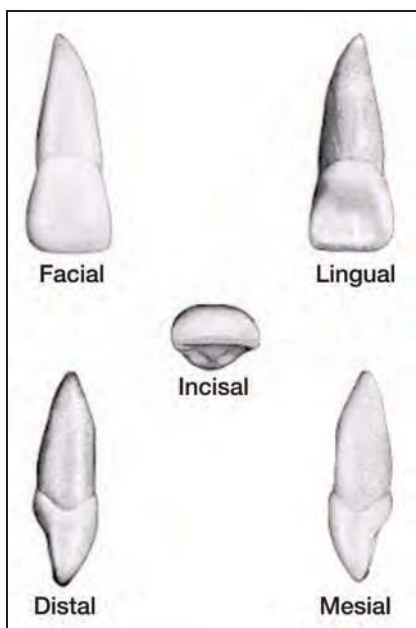


Figure 5-8. Maxillary Right Central Incisor

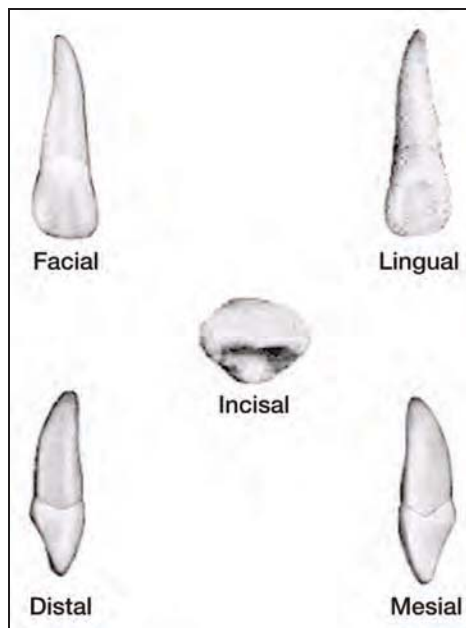


Figure 5-9. Maxillary Right Lateral Incisor

5-39. The permanent mandibular central incisors are the smallest and most symmetrical of all the teeth. The universal numbers are #25 (r) and #24 (l).

5-40. The permanent maxillary lateral incisors (figure 5-9) resemble the central incisors but on a smaller scale. They are smaller in all respects, except root length, which is roughly the same. Maxillary lateral incisors vary in form more than any other tooth, except the third molar. The universal numbers are #7 (r) and #10 (l).

5-41. The permanent mandibular lateral incisors resemble the mandibular central incisors, except that they are slightly larger in all dimensions and less symmetrical in outline. The incisal edges are not as straight as the mandibular central incisors, the distal portion curves toward the lingual. The root lengths are normally greater than those of the central incisors. The universal numbers are #26 (r) and #23 (l).

**Chapter 5****MAXILLARY AND MANDIBULAR CANINES/CUSPIDS**

5-42. The canine/cuspid is the longest tooth in the dental arcade and has the largest root in relation to crown size of any tooth. The canine has a single-pointed cusp. The mandibular canines are smaller in size than the maxillary canines and also have a narrower crown.

5-43. The permanent maxillary canines/cuspids (figure 5-10) are the longest teeth in the arch. They are the only teeth with one cusp. The universal numbers are #6 (r) and #11 (l).

5-44. The permanent mandibular canines/cuspids are similar in many respects to the maxillary canines. The universal numbers are #27 (r) and # 22 (l).

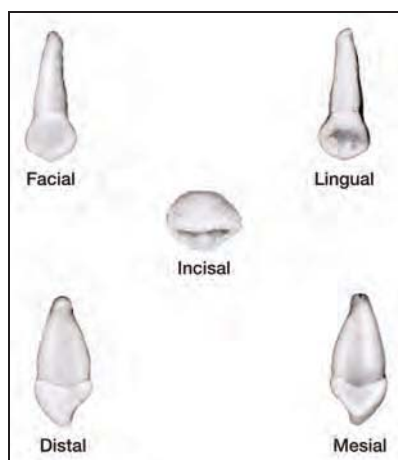


Figure 5-10. Maxillary Left Canine/Cuspid

**MAXILLARY AND MANDIBULAR PREMOLARS/BICUSPIDS**

5-45. The premolars are also referred to as bicuspid because of the presence of two cusps on the crown. The maxillary first premolars usually have two roots, which may have fused. The remaining premolars usually have a single root.

5-46. The permanent maxillary first premolars/bicuspid (figure 5-11) have the longest crowns of the maxillary premolars. The two maxillary first premolars are more similar to each other than are the mandibular first premolars. They have two clearly defined cusps (facial and lingual) of approximately equal size. The universal numbers are #5 (r) and # 12 (l).

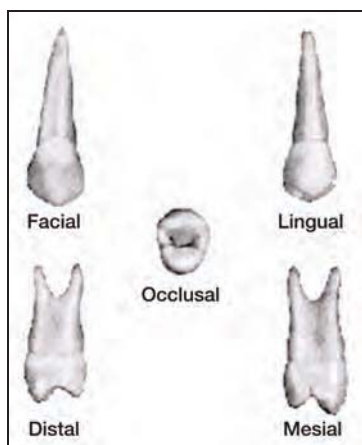


Figure 5-11. Maxillary Left First Premolar/Bicuspid

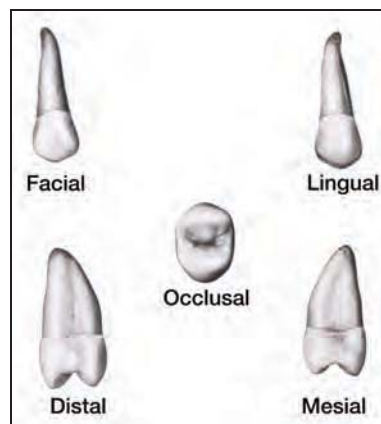


Figure 5-12. Maxillary Left Second Premolar/Bicuspid

5-47. The permanent mandibular first premolars/bicuspid are smaller than the second mandibular premolars. They have two cusps, but only the facial cusp is functional. The mandibular first premolars have some characteristics which resemble those of the mandibular canine. These premolars exhibit more variations in form than do their maxillary counterparts. The universal numbers are #28 (r) and #21 (l).

5-48. The permanent maxillary second premolars/bicuspid closely resemble the maxillary first premolars with the following exceptions. The crowns are smaller, the cusps are about equal in height, and they normally have a single root. In general, the maxillary second premolars are slightly smaller in all dimensions than the maxillary first premolars. The universal numbers are #4 (r) and #13 (l).

5-49. The permanent mandibular second premolars/bicuspid (figure 5-12) are larger and better developed than the mandibular first premolars. These teeth assume two common forms in which they may have either two or three cusps. The three-cusp form probably occurs most often. In this form there is one facial and two lingual cusps. These premolars exhibit more variations in form than do their maxillary counterparts. The universal numbers are #29 (r) and #20 (l).

## MAXILLARY AND MANDIBULAR MOLARS

5-50. The maxillary molars typically have three roots, while the mandibular molars typically have two roots which may be fused.

5-51. The permanent maxillary first molars are the largest teeth in the maxilla and have the largest crowns. They are referred to as the “6-year” molars as, on the average, they erupt at approximately 6 years of age. The universal numbers are #3 (r) and #14 (l).

5-52. The permanent mandibular first molars (figure 5-13) are the largest and strongest teeth in the mandible. They normally have five well-developed functional cusps and two well-developed roots. Like the maxillary first molar, they are referred to as the “6-year” molars as, on the average, they erupt at 6 years of age. The universal numbers are #30 (r) and #19 (l).

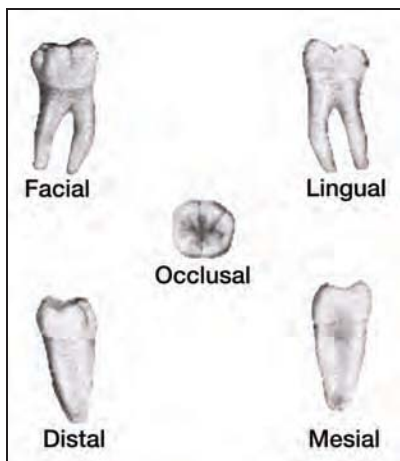


Figure 5-13. Mandibular Right First Molar

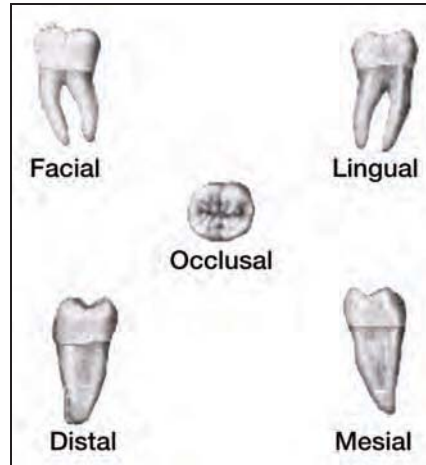


Figure 5-14. Mandibular Left Second Molar

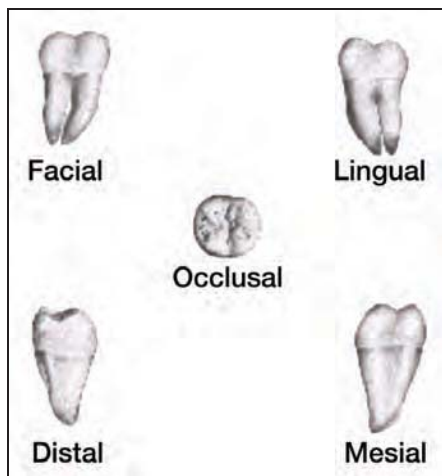
5-53. The permanent maxillary second molars closely resemble the maxillary first molars but are generally smaller. The roots are long and can be longer than those of the maxillary first molars. There may be fusion of the two buccal roots. They are referred to as the “12-year” molars as, on the average, they erupt at 12 years of age. The universal numbers are #2 (r) and #15 (l).

5-54. The permanent mandibular second molars (figure 5-14) closely resemble the mandibular first molars. They are, however, smaller in all dimensions and more symmetrical. They normally present four cusps. The two facial and two lingual cusps are nearly equal in development. The teeth have two roots that are closer together than those of the mandibular first molars. Like the maxillary second molars, they are

**Chapter 5**

referred to as the “12-year” molars as, on the average, they erupt at 12 years of age. The universal numbers are #31 (r) and #18 (l).

5-55. The permanent maxillary third molars (wisdom teeth) are the most variable teeth in the upper arch in form, size, and number of roots. They closely resemble the maxillary second molars but smaller in all directions. The crowns show more rounding and the roots are normally the shortest of the maxillary molars. There is a greater chance for fusion of all the roots than in either of the other maxillary molars. The third molar erupts between 17 and 21 years of age. The universal numbers are #1 (r) and #16 (l).



**Figure 5-15. Mandibular Right Third Molar**

5-56. The permanent mandibular third molars (wisdom teeth) are the most variable teeth in the lower arch in general form, size, crown form, and number of roots (figure 5-15). They closely resemble the maxillary second molars but are smaller in all directions. The crown shows more rounding and the roots are normally shorter than those of the mandibular first and second molars. Single-fused roots are common as there is a greater chance for fusion of the roots than in either of the other mandibular molars. The third molar erupts between 17 and 21 years of age. The universal numbers are #32 (r) and #17 (l).

## DENTAL CARIES

5-57. Dental cavities (or caries) are an infection caused by a combination of carbohydrate-containing foods and bacteria that live in the mouth. The bacteria are contained in a film that continuously forms on and around teeth. This film is called plaque. Although there are many different types of bacteria in the mouth, only a few are associated with cavities. Some of the most common include *Streptococcus mutans*, *Lactobacillus casei* and *acidophilus*, and *Actinomyces naeslundii*. When these bacteria find carbohydrates, they digest them and produce acid. The exposure to acid causes the PH on the tooth surface to drop. Before eating, the PH in the mouth is about 6.2 to 7.0, slightly more acidic than water. As "sugary foods" (candy, sugar frosted breakfast cereals, ice cream, soda, Kool-Aid, and so forth) and other carbohydrates are eaten, the PH drops. At a PH of 5.2 to 5.5 or below, the acid begins to dissolve the hard enamel that forms the outer coating of the teeth. Every exposure to these foods allows an acid attack on the teeth for about 20 minutes. As the cavity progresses, it invades the softer dentin directly beneath the enamel and encroaches on the nerve and blood supply of the tooth contained within the pulp.

5-58. Cavities attack the teeth in two main ways. The first is through the pits and fissures, which are grooves that are visible on the top biting surfaces of the back teeth (premolars and molars). The pits and fissures are thin areas of enamel that contain recesses that can trap food and plaque to form a cavity. The cavity starts from a small point of attack, and spreads widely to invade the underlying dentin. The second route of acid attack is from a smooth surface, which is between or on the front or back of teeth. In a smooth surface cavity, the acid must travel through the entire thickness of the enamel. The area of attack is generally wide and comes to a point or converges as it enters the deeper layers of the tooth.

5-59. The first visible sign of dental decay may be a slightly whitened area in the enamel. This can be easily overlooked when the enamel is wet but will stand out when it is dry. The caries develops from the whitened area and varies in size from that of a pinhole to a hole that covers a large percentage of the tooth. More advanced decay may appear yellowish brown or black.

## **DENTAL RESTORATIONS**

5-60. Dental restorations are broken down into three categories: temporary restorations, permanent restorations, and prosthetic appliances.

### **TEMPORARY RESTORATIVE MATERIALS**

5-61. Temporary restorative materials are primarily used for emergency and temporary treatment for permanent teeth and on deciduous teeth. The following materials are used to fill cavities, cement crowns, and crown (cap) teeth:

- Zinc oxide combined with eugenol is used primarily for emergency filling of advanced caries and fractured enamel and for temporarily cementing crowns and some appliances. Zinc oxide and eugenol are low in strength and have poor resistance to abrasion.
- Cavit is a clay-like grey material that is most often used as a temporary filling material after root canal therapy.
- Ketac bond or silver is white or gray reinforced cements that can be used to help rebuild a tooth after root canal therapy or as a temporary filling material.
- A stainless steel crown maybe either a dull or shiny gray temporary cap used on a tooth prepared for a permanent full crown.

### **PERMANENT RESTORATIVE MATERIALS**

5-62. Permanent restorative materials are those substances that will last as long as the natural tooth, if not longer, if proper dental hygiene procedures are followed. Permanent restorative materials are subdivided into direct and indirect restorative dental materials.

#### **Direct Restorative Dental Materials**

5-63. Direct restorative dental materials are those used to directly fill the cavity in the tooth.

- Amalgam is used for dental fillings and sometimes for replacing portions of broken teeth. Amalgam is a very durable mixture composed mainly of mercury (43–54 percent) and varying percentages of silver, tin, and copper. A large percentage of all permanent restorations are made of amalgam. This gray filling material is used on the posterior teeth, primarily on the occlusal surfaces.
- Composite, resin, or white fillings have been around for about 30 years. Composite fillings are composed of an organic polymer known as bisphenol-A-glycidyl methacrylate (BIS-GMA), and inorganic particles such as quartz, borosilicate glass, and lithium aluminum silicate. They are used primarily for esthetic fillings in the front or back teeth.
- Glass ionomers are a mixture of fluoride containing glass powder and organic acid. They form a solid tooth-colored restoration. They are used for small non-load-bearing fillings, as cements for crowns and bridges, and as temporary restorations.
- Resin-ionomers are a mixture of submicron glass filler and fluoride containing glass powder and acrylic resin that forms a solid tooth colored restoration. They are used in small non-load-bearing fillings, as cements for crowns and bridges, and as liners.

#### **Indirect Restorative Dental Materials**

5-64. Indirect restorative dental materials are those that are made by a dental laboratory and used to restore a tooth. (The composites as described above can be processed and used as indirect restorative dental materials.)

**Chapter 5**

---

- Porcelain (ceramic) is a glass-like material formed into fillings and crowns using models of the prepared teeth. Porcelain can be made to match the color of the tooth being repaired. It is used for inlays, veneers, crowns, and fixed-bridges. Porcelain is often fused to an underlying metal structure to provide strength to a filling, crown, or fixed bridge.
- Gold alloys are mixtures of gold, copper, and other metals. They are used for onlays, inlays, cast crowns, and fixed bridges.
- Nickel or cobalt-chrome alloys are mixtures of base metal alloys, such as nickel and chromium, with a silver appearance. They are used for some crowns, fixed bridges, and partial denture frameworks.

5-65. Gutta-percha is a widely used pink rubber-like substance used to fill the roots during root canal therapy. It is easy to manipulate and does not dissolve in oral fluids.

**PROSTHETIC APPLIANCES**

5-66. Prosthetic appliances are replacements or substitutions for natural teeth.

**Denture**

5-67. A denture is a removable replacement for missing teeth and adjacent tissues.

5-68. A denture is typically made of acrylic resin, sometimes in combination with various metals. Dentures constructed more than 30 years ago can also be made from cobalt chromium—a strong, hard metal. Dentures are constructed using flesh-colored material with natural-looking teeth inserted into the base material.

5-69. Complete and partial artificial dentures make up the great bulk of dental prosthetic appliances. A complete denture replaces the entire complement of teeth in an arch. A partial denture is for people who have some natural teeth remaining or who only need to replace a few teeth. It fills in spaces created by missing teeth and prevents other teeth from migrating.

**Dental Bridge**

5-70. A dental bridge is an appliance used to replace one or more missing teeth. There are three types of bridges.

- A fixed bridge replaces one or more missing teeth. It is made out of a series of joined crowns or caps that fit into the open place in the mouth, “bridging” the gap. This bridge is made of a pontic (false) tooth held together by two crowns (a cap that covers the tooth). The bridge is cemented to the teeth on either side of the gap. The wearer cannot remove a fixed bridge.
- A “Maryland” bridge (resin bonded bridge) is a pontic tooth fused together to metal bands—bonded to the teeth on either side of the gap with resin cement. This is a common bridge when teeth are missing from the anterior mouth.
- A cantilever bridge is used in areas that are under less stress. They are most appropriate when there are teeth on only one side of the open gap.

**Dental Implants**

5-71. Dental implants are used to replace missing teeth and to prevent bone loss under dentures. They are titanium rods about one centimeter long that are inserted into the mandible or maxilla. Implants are substitutes for roots of missing teeth. They serve the same purpose as the tooth roots; they act as anchors. The implant rods can be threaded, perforated, hollow, solid, coated, or textured.

## DENTAL ANOMALIES

5-72. Descriptions of some of the most common abnormalities/variations of the teeth and tooth form follow.

- Abrasion is the wearing away of tooth structure, typically the occlusal surface, through mastication (chewing of food), sharp particles, incorrect brushing, or friction of clasps holding a partial denture.
- Dental fluorosis (mottled enamel) is caused by excessive fluorine intake during the enamel calcification period. The tooth exhibits chalky white bands or areas, which usually become pigmented brown or yellow.
- A diastema is a space between teeth that are normally in contact.
- Enamel hypoplasia is a defect in the enamel that occurs during the development of the enamel. They are grooved bands that can be shallow or deep, and run horizontally across the crown of the tooth. Environmental and genetic factors that interfere with tooth formation are thought to be responsible for enamel hypoplasias.
- Enamel pearls are small, rounded nodules of enamel that are attached to the root surfaces of teeth.
- Erosion is the chemical wearing away of the tooth structure. It appears on the external surface at the gum line of the tooth. Where erosion is present, the enamel is usually hard and shiny. In some cases, the crown may almost be separated from the root.
- Fusion occurs with the union of two adjacent teeth. The fusion usually involves the crowns only, but can on occasion involve the crowns and the roots. Fusion is most common in the anterior teeth.
- A tooth fracture is a broken tooth. The enamel, dentin, and pulp are chipped away. A fracture of the tooth does not have to involve all tooth surfaces. If only the enamel is chipped, it is referred to as an enamel fracture.
- Macrodonia is used to refer to teeth that are larger in size than normal. The incisors and canines are most commonly affected.
- Malocclusion is any deviation from the normal relationship of the occlusal surfaces of the teeth. Dental malocclusion is a condition in which the upper and lower jaws do not fit together normally, either because they are not the right size or because the teeth are not aligned correctly. This can be due to genetics, from trauma to the face or jaw, or from dysfunction of the temporomandibular joint.
- Microdonia is used to refer to teeth that are smaller in size than normal. The maxillary lateral incisors and maxillary third molars are most commonly affected.
- Migration/drift is when one or more teeth move or drift into a space not occupied by a tooth. The absent tooth was either extracted or erupted in an unusual manner.
- Rotation may be present in any of the teeth, but it is more common in the anterior teeth. A rotated tooth is one that is twisted in such a way that one or more of its surfaces are not in their proper location.
- Supernumerary (extra) teeth are an excessive number of teeth. The term “accessory” is frequently used as the “extra” teeth usually do not resemble normal teeth in size or shape.

**This page intentionally left blank.**



## Chapter 6

# BASIC MEDICOLEGAL DEATH INVESTIGATION

### OBJECTIVE

6-1. This chapter serves as a rudimentary outline on basic medicolegal death investigation. The intent of this chapter is not to make the mortuary affairs specialist a proficient medicolegal death investigator. However, this chapter will provide the mortuary affairs specialist with the knowledge of medical, legal, and scientific standards to ensure that all crucial forensic evidence is preserved and documented in compliance with MDI standards during the 92M mission of search, recovery, evacuation, and tentative identification of remains.

### MEDICOLEGAL DEATH INVESTIGATION DURING COMBAT

6-2. United States Code, Title 10 Armed Forces, Subtitle A, Part II, Chapter 75, Subchapter 1, section 1471, empowers the Armed Forces Medical Examiner System (AFMES) to conduct forensic pathology investigations to determine the cause or manner of death of a deceased person if such an investigation is justified under specified circumstances. Therefore, the Armed Forces Medical Examiner System establishes a Department of Defense standard system for medicolegal death investigations (MDI) coming under federal jurisdiction.

6-3. The Chief of the Armed Forces Medical Examiner System, in a memorandum dated 15 December 2003, stated:

- Due to the increasing level of accountability for our fallen service members in times of peace and war, by families, the military, and the public, the Office of the Armed Forces Medical Examiner (OAFME) is treating each battlefield fatality as a forensic medicolegal death investigation.
- This policy requires rigorous adherence to medical, legal, and scientific standards from the time the remains are recovered until released from forensic hold to ensure that all crucial forensic evidence is preserved and documented.
- The OAFME cannot accomplish their mission without the full support of the Mortuary Affairs Specialist (MOS 92M).
- This MDI policy has a significant impact by virtue of the 92M's mission of search, recovery, evacuation, and tentative identification of remains.
- The 92M is one of the first responders to the scene.
- All search, recovery, and evacuation efforts MUST comply with MDI standards.
- All anatomical, dental, and fingerprint charting MUST be done at a mortuary under the AFMES supervision.
- If remains are not handled appropriately, significant forensic evidence will be lost and that evidence may be unrecoverable.

6-4. The mortuary affairs specialist does not work as a medicolegal death investigator. However, the above guidance renders it imperative that the mortuary affairs Soldier/Marine be well-versed in medical legal death investigative principles to ensure that crucial forensic evidence is preserved during search and recovery operations and the evacuation of human remains to the Armed Forces medical examiner.

6-5. The emphasis is on the critical preservation and documentation of forensic evidence. Proper preservation and documentation of evidence begins at the initial stage of the identification process. For the mortuary affairs specialist this would be in the field; for example, during a search and/or recovery mission for human remains or when receiving and processing human remains at a collection point or TMEP. If

**Chapter 6**

---

evidence is compromised at this initial stage, then the forensic work that follows will be compromised—ultimately affecting the outcome of the identification. Preservation and documentation of evidence is critical to the final positive identification of human remains as well as in the determination of the cause and/or manner of death.

6-6. Sections 6-22 through 6-151 describe MDI procedures that are to be followed in an ideal medical legal investigation conducted within civilian sectors. It is both impractical and infeasible that military search and/or recovery, collection point, and TMEP operations mirror all the procedures conducted in a typical medicolegal death investigation. However, MDI procedures for preserving evidence, documenting a scene, and documenting the remains and associated evidence and personal effects must be followed to the extent possible to ensure compliance with the AFMES standards.

6-7. The goal of any recovery operation is to recover all human remains and collect and safeguard personal effects and/or evidence. In compliance with the AFMES standards, the recovery team will establish and document the context in which all human remains and evidence is found, will secure all human remains and evidence, and will ensure that the human remains and personal effects/evidence are safely and securely transported to a final destination.

6-8. During the search and recovery of human remains and personal effects/evidence, the mortuary affairs Soldier will apply archeological principles to ensure the recovery meets with both scientific and AFMES standards. Archeological principles provide the basis for the sound documentation of the context from which human remains and associated personal effects /evidence are recovered during a mission (refer to JP 4-06, chapter V, Procedures for the Search and Recovery of Human Remains). Because documentation is a primary focus of any recovery operation, all activities at the site must be documented in a thorough and consistent manner as outlined in sections 6-38 through 6-1245. Combining archeological principles with MDI standards will ensure that human remains and personal effects/evidence will be recovered in agreement with AFMES standards.

6-9. During the processing of human remains at a collection point or TMEP, mortuary affairs Soldiers will ensure that any and all potential forensic evidence is preserved. Ensure that nothing interferes with future examinations. Do not take fingerprints, removing clothing, or remove military equipment. Do not cut pockets, clean the body or place anything on the body. Do not remove hazardous material, weapons, and munitions. Inventory PE to establish chain of custody, but do not cut the clothing, including the pockets, during the process. Personal effects will remain with the body during evacuation to the mortuary.

6-10. The following chapter provides MDI guidelines for the mortuary affairs Soldier to follow in combat, as well as mass disaster, situations.

## **INTRODUCTION**

6-11. To successfully complete a death investigation requires training in a variety of disciplines. The term “medicolegal investigation of death” incorporates both medical and legal knowledge. Since death is often a natural medical event that demands an understanding of human anatomy, physiology, and disease processes, the need for medical knowledge is obvious. Likewise, as some deaths may involve the commission of a crime or other unnatural events, it is also essential to have an understanding of jurisdictional laws and the legal aspects of a case. In addition, the medicolegal death investigator must have knowledge of criminalistics and public health issues.

6-12. At a typical death scene, the local law enforcement agency is responsible for the overall scene. The medicolegal death investigator responds to a death scene to assume the responsibility for the body and to conduct an investigation to help establish the cause and manner of death. Proper investigation at the death scene, with follow-through investigations, will ensure that significant information concerning the death will be documented. Medicolegal death investigators must have the requisite medical knowledge, knowledge of the legal aspects of the job, and the proper techniques for interacting with family, friends, police, and other individuals whom the investigator may contact in the course of an investigation.

6-13. Medical legal investigations (primarily unnatural or suspected unnatural deaths) in the United States are carried out by medical examiner or coroner systems. The current trend is for medical examiner

systems to replace the coroner system. However, there are still a significant number of coroner systems in operation in the United States.

6-14. The coroner system is older than the medical examiner systems. Coroners have been around for centuries, dating back to when there were no forensic pathologists, and autopsies were virtually unheard of. A coroner is an elected official who may or may not be a physician (anyone could become a coroner). Training required for a coroner varies from none to a few hours to 1 to 2 weeks. The coroner investigates by inquest any death not due to natural causes. The coroner will make the decision as to cause and manner of death. The coroner will determine if an autopsy should be conducted and will have a pathologist conduct the autopsy. Since the coroner or his administrative designee signs the death certificates, it follows that in a coroner system the doctor who completes the autopsy in most cases will not be the one to sign the death certificate.

6-15. The medical examiner system was first introduced in the United States in Boston, Massachusetts, in 1877. Medical examiners—usually physicians and generally with training in pathology, medicolegal death investigation, and performance of forensic autopsies—generally have greater expertise in unnatural death investigations than do coroners. The major advantages of a statewide medical examiner system are the high quality of death investigations and forensic pathology services and their independence from population size, county budget variation, and politics. Certification of death is done by highly trained medical professionals who can integrate autopsy findings with those from the death scene and the laboratory. These professionals have core competency in assessing immediate and earlier medical history and physical examination.

## **ROLE OF THE MEDICOLEGAL DEATH INVESTIGATOR**

6-16. The medicolegal death investigator is typically a representative of the medical examiner's/coroner's office. He is the eyes and ears of the medical examiner, with jurisdiction over all evidence from the body. The death investigator should be better trained and more knowledgeable of the causes of death than other investigators at the scene. He must know medical terminology, abbreviations, medicine in a clinical setting, prescribed prescriptions, and various medical procedures.

6-17. The death investigator focuses on the physical condition of the body at the scene. The death investigator gathers detailed preliminary information at the scene concerning injuries, trace evidence, identification, estimation of time of death, cause of death, and manner of death. This information is invaluable to other forensic scientists, including the medical examiner and investigators and criminalists from law enforcement agencies.

6-18. The death investigator will conduct an investigation when a death is violent, suspicious, occurs in custody, or occurs at the work place. Many jurisdictions require an investigation in all infant/child deaths and in nonviolent deaths in individuals less than 30 years of age.

6-19. The death investigator will request medical records, review the records, thin the records to pertinent files only, and then copy the records.

6-20. The death investigator will meet with families, interview witnesses, and write a narrative report of his findings concerning the death incident.

## **ARRIVE AT THE DEATH SCENE**

### **Introduce Self**

6-21. When the investigator arrives at the death scene, he must take the initiative to introduce himself. This introduction serves to establish formal contact with other official agency representatives, helps to identify the lead investigator/team leader and first responder to the scene, and helps to establish a common investigative effort. The investigator will then work with other key personnel to ensure scene safety before entering the death scene.

**Chapter 6**

---

**Establish Scene Safety**

6-22. Scene safety is essential to the investigative process. Safety can be compromised by a variety of factors, including hostile crowds, dangerous terrain, collapsing structures, traffic, or chemical and biological hazards. It may be that these particular hazards actually caused the death. The investigator must be alert to these conditions and establish scene safety before entering the scene. Appropriate emergency personnel may need to be contacted to control hazardous conditions. In these instances, scene processing must be delayed until the area has been declared safe.

**Confirm Death**

6-23. The standard operating procedure for confirming death varies from jurisdiction to jurisdiction. The appropriate individual—be it physician, medical examiner, coroner, nurse, or paramedic—must make the determination of death or evidence of death before the death investigation begins. The investigator must, therefore, ensure that the authorized individual has viewed the body and made an official pronouncement of death. After the death has been determined, the medicolegal jurisdiction can be established.

6-24. The investigator must document the name and title of the individual who pronounced the death and the official time, date, and location of death. These items are an essential component of the investigation.

**Communicate with Responding Agency/Agencies**

6-25. As numerous agencies respond to a typical death scene, information is dispersed among various individuals, such as police officials, crime laboratory personnel, and emergency personnel. The death investigator must recognize the various responsibilities of these agencies and receive and share information accordingly.

6-26. The death investigator must identify specific responsibilities, share appropriate preliminary information, and establish the investigative goals of each agency present at the scene. A scene briefing will ensure the initial factual exchange of information as it is known at the time. (A crime scene is not static, information and situations change as time goes on.) This information includes scene location, time factors, initial witness information, agency responsibilities, and investigative strategy. The scene briefing will also serve to ensure that each participant is familiar with each other's role and responsibility.

6-27. The death investigator must cooperate with other investigators, law enforcement officials, and other specialists at the scene. Each involved individual has legal responsibilities. Conflicts can arise if these responsibilities are not understood by all parties before the investigation begins.

6-28. The death investigator has the legal authority to request information from outside agencies. The correct procedures must be followed to request this information. Typically the investigator makes a formal request in writing to the appropriate agency.

6-29. The death investigator will also share information with outside agencies. This information is typically records that have been compiled by the medical examiner/coroner. The investigator may share this information as long as the requesting agency has a legal right to the information.

6-30. The death investigator must maintain confidentiality. He may not release information received from an outside agency to a third party. This information is not the investigator's (or his office's) right to release. The requesting third party must request the information directly from the original office.

**Conduct a Scene Walk-Through**

6-31. The preliminary walk-through is necessary to minimize scene disturbance, identify potential evidence, and prevent the loss and/or contamination of that evidence. The walk-through will provide the investigator with an overview of the entire scene, the first opportunity to locate and view the body and identify fragile evidence, an opportunity to determine the time interval between the death incident and the time the medical examiner's office was notified, and formulate an investigative plan for a systematic examination and documentation of the scene and the body.

**Initiate Chain Of Custody**

6-32. Establishing and maintaining a chain of custody over evidence ensures the integrity of the evidence and reduces the likelihood of a challenge to that integrity. A court will require proof that evidence collected during an investigation and that being submitted to the court are one and the same. Chain of custody is initiated with the marking of physical evidence at the time of collection. Chain of custody is a witnessed, written record of all the individuals who had contact with and/or maintained control over items of evidence. It is documentation of possession that serves as a list of individuals who had custody of the evidence, the date(s) of transfer, and where the evidence was secured while in custody. The chain of custody provides integrity, accountability, and unbroken control over the evidence, and ensures that the evidence has not been tampered with or substituted. It establishes proof that the items of evidence collected at the scene are the same items presented in a court of law.

6-33. The death investigator must know which agency is responsible for the collection and custodianship of specific types of evidence. The medical examiner/coroner is routinely responsible for the body and associated evidence. The death scene and associated evidence is the jurisdiction of the local law enforcement agency.

6-34. The law varies from state to state, so it is essential that the death investigator is knowledgeable about his jurisdiction's statutes. The investigator must work with other responding agencies to determine the applicable laws regarding evidence collection. The investigator must follow local, state, and federal laws for evidence collection to ensure that it will be admissible in a court of law.

6-35. The evidence is placed into a container at the scene and labeled or tagged. Information pertaining to the case—such as the name or initials of the collector; the date the item was collected and transferred; the agency, case number, and type of crime; and a brief description of the item—is written on the label or tag.

6-36. The U.S. Army uses DA Form 4137 to maintain chain of custody (refer to appendix B). Any individual who initiates a chain of custody and signs the objects over to the appropriate authority should retain a copy of the form.

**DOCUMENT AND EVALUATE THE DEATH SCENE****Photograph the Death Scene**

6-37. Usually a representative of the responding law enforcement agency will photograph the entire death scene. The death investigator should take photographs for the forensic pathologist/medical examiner performing the autopsy. Photographs must be available for other investigators and agencies to recreate the death scene.

6-38. The photographic documentation of the death scene establishes a permanent record of the scene and associated evidence. Photographs in conjunction with the written documentation, sketches, and witness statements will provide adequate documentation of the body and the scene.

6-39. Photographs depict a sequence, from general to specific, of a death scene. Therefore, photographs should be taken of the overall scene, of midrange views to show the relationships of evidence, and close-ups of each item of evidence. Typically two close-up photographs of each object will be taken, one with a scale or ruler and one without. Additional close-up photographs will be taken as needed. The progressive nature of the photographs allows for orientation of the scene as a whole and the orientation of evidence and objects within the scene. Evidence photographs provide for examination of specific items of evidence and may be substituted for laboratory examination in the case of transient items.

6-40. Ensure that an adequate amount of photographs are taken. Photographs should be detailed and, like a written narrative, tell the story of the death scene.

6-41. Photographs should be taken as soon as possible, typically immediately following the preliminary scene survey. Thoroughly photograph the death scene before it has been examined and before the body and any objects have been moved. If an item has been compromised prior to documentation, do not move the

**Chapter 6**

---

object to “stage” it the way it would have looked at the time of the crime. If an item has been inadvertently moved, document the occurrence in writing.

6-42. Prepare a scene placard with the date, time, location, agency, case number, and investigator. Photograph the placard before taking any other photographs.

6-43. A photographic log, a complete written record of all photographic documentation at the scene, must be kept.

6-44. Photograph the scene and the body from different angles to provide various perspectives that may aid in any future analyses. Take general, overall photographs of the scene to provide a spatial orientation of the scene to the surrounding area. Take midrange photographs of the relationship of objects to one another. Proceed to detailed photographs of the body, to include the face, and of specific injuries and areas of the scene.

6-45. The investigator should take photographs even if the body or other evidence was moved. If evidence and/or the body was moved prior to photographing, it should be noted in the written report. Never reintroduce the evidence and/or body into the scene.

**Provide Written Documentation of the Death Scene**

6-46. Everything a death scene investigator learns during the investigation should be documented. Written documentation of the death scene provides a permanent record that, in correlation with photographs and sketches, will enable authorities with a legitimate interest to recreate the scene. Effective notes attempt to answer the who, what, when, where, why, and how of the investigation. Notes should be taken in chronological order and should not be edited. They should be detailed and document step-by-step all actions. Notes should be as specific as possible, complete, and thorough. They should provide a running narrative of the conditions at the death scene. Notes should describe the scene as it appears and record transient evidence (odors, sights, sounds) and weather conditions. The location and description of potential physical evidence and objects should be recorded before anything is moved. Notes do not include opinions, analysis, or conclusions. They include only the facts. Rough notes, as well as sketches, should never be discarded but included in the case file.

6-47. In addition to filling out all required office forms, the investigator should write a narrative report concerning the circumstances of the death and the individual’s medical history. This report should be written in chronological order and in a form that can be easily understood by forensic professionals as well as laymen. It is not unusual for the family of the decedent to request a copy of the investigator’s report.

6-48. The investigator should ask who, what, where, when, how, and why to answer key death investigation questions. These answers form the body of the narrative report. Each report must be accurate, thorough, unbiased, and clearly written immediately after the investigation. When writing the narrative, the death investigator should use terminology such as, “in accordance with the records at hand” or “according to such and such an individual.” This terminology makes it clear that the investigator is passing on information as received. Outside agencies often depend on information from the death investigator to complete their analyses. The investigator’s report must, therefore, be written in a timely fashion.

6-49. Sketches are drawings that accurately depict the appearance of a death scene. The sketch is a permanent record of the scene. It documents objects present and the position, size, and relationship of the objects to one another. It must portray the most essential elements of the death scene and their relationship to the scene.

6-50. A rough sketch is drawn at the scene and is used as a model for the finished sketch. The rough sketch is usually made before evidence collection. It shows all the evidence to be collected and all relevant structures. Rough sketches are not normally drawn to scale. However, measurements of objects and between objects must be taken during sketching for a drawn-to-scale diagram, if necessary.

6-51. The final sketch is prepared from the rough sketch and is usually prepared for courtroom presentation. The final sketch presents a clean, uncluttered appearance.

6-52. The sketch should include the agency case number, incident type, name of the sketcher, date, time, location, weather and lighting conditions, reference points, a key or legend, north orientation, and a scale.

6-53. Sketches are used to supplement photographs. They have an advantage over photographs in that they can cover a large area and can be drawn to leave out much of the clutter that appears in photographs. A sketch will also provide a better representation of spatial relationships of objects to each other than does a photograph.

6-54. There are three useful methods for completing a sketch—floor plan, exploded, and triangulation. The type of sketch chosen is not especially important. What is important is that the sketch best depicts the death scene and most easily illustrates the event to the viewer.

### *Floor Plan*

6-55. The floor plan is the most common and simplest method (figure 6-1). It provides an overhead (bird's eye) view of the scene detailing locations where evidence is found. It may be used in nearly all crime scene situations where items of interest are located in one plane.

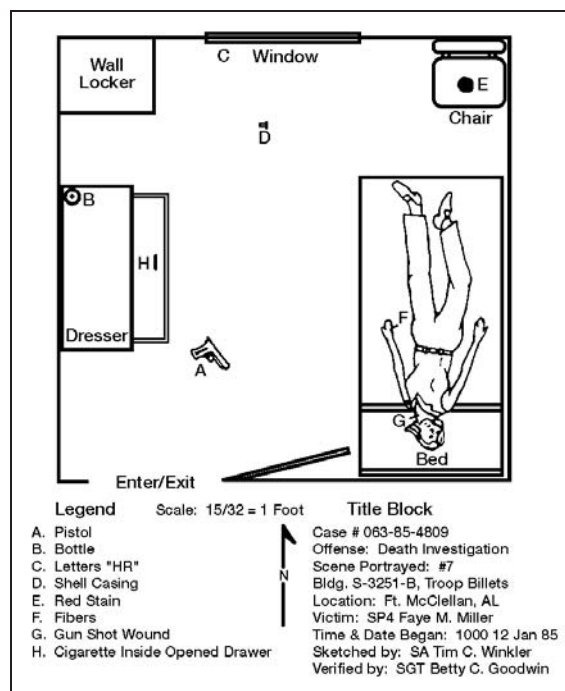


Figure 6-1. Floor Plan Method

### *Exploded View*

6-56. The exploded view or cross-projection method (figure 6-2) is similar to the floor plan—except the walls have been folded down into the same plane as the floor. This allows for documentation of evidence found on/in the walls.

Chapter 6

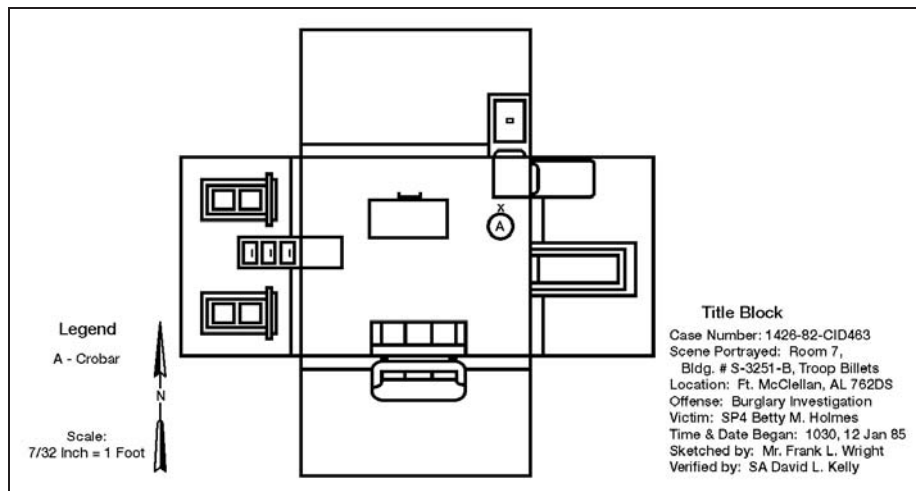


Figure 6-2. Exploded/Cross-projection Method

Triangulation Method

6-57. The triangulation method (figure 6-3) is particularly useful for outdoor scenes. Evidence is measured from two separate points of reference to locate and position the evidence within the diagram.

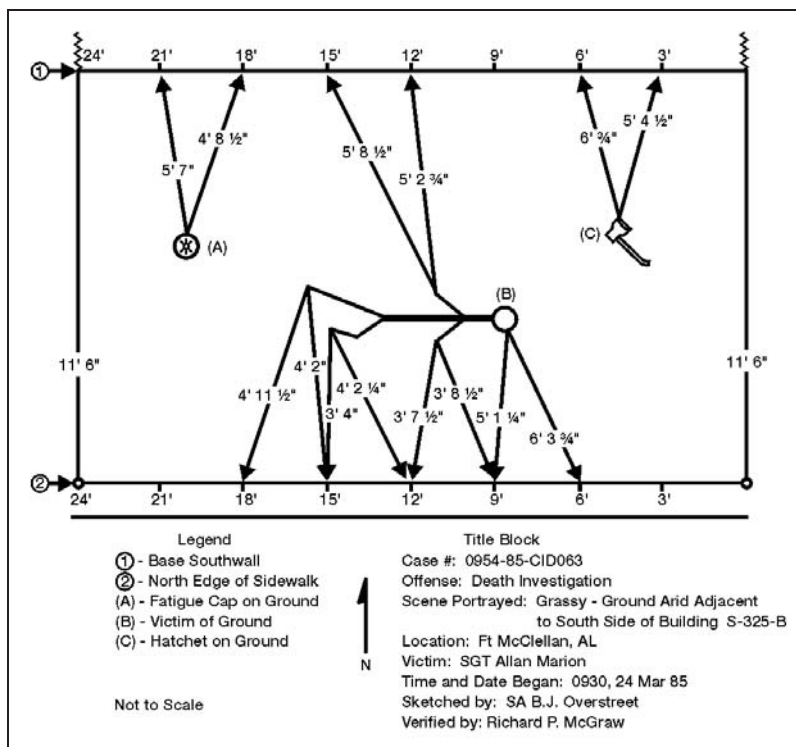


Figure 6-3. Triangulation Method

6-58. All documentation will be compiled into a case file. Forensic and/or technical reports shall be added to the file when they become available.



### Evaluate Probable Location of Injury or Illness

6-59. The precise location where the decedent is found within the scene is important (as is the geographic location of the scene) and must be documented. Scene sketches are used to depict the exact location of the body. Measure as accurately as possible from fixed points within the scene and describe the orientation of the body—such as head to east, feet to west.

6-60. As the environment where the decedent was discovered affects the body's postmortem changes, it is important to document the environmental conditions at the location. Observe the environment and associated evidence at the death scene. These observations will include a variety of factors/situations. The investigator should record such conditions as temperature, airflow, moisture, lighting, unusual conditions, and the type of surface the body was resting upon.

6-61. The location where the body was found may not be the actual location where the injury or illness that caused/contributed to the death took place. The death investigator must make a concerted effort to determine the location of any and all injuries or illnesses. Physical evidence at these locations may be relevant in establishing the cause, manner, and circumstances of death.

- If the body was moved after death, the investigator must make every attempt to determine the original location and how the body was moved.
- In livor mortis the color, location, and blanchability should be consistent with the position of the body as discovered. In rigor mortis the stage, intensity, and location of the body should be consistent with the position of the body as discovered. The death investigator should identify and document any discrepancies.
- The investigator should check the body, clothing, and scene for inconsistencies of trace evidence and document the location of this evidence.
- The investigator should check for drag marks and any post-injury activity.
- The investigator should correlate the information obtained from the body with information derived from the scene to provide a reliable evaluation of the scene and the death incident.

### Collect and Safeguard Physical Evidence and Personal Property

6-62. As part of the investigation, the responsible individual will ensure that all personal effects and physical evidence are collected, inventoried, safeguarded, and released as required by law. The distinction between personal effects and physical evidence should be made. Physical evidence can be any object that the investigator feels is pertinent in explaining the circumstances of the crime. Personal effects may or may not be physical evidence. Personal effects are property on or near the body, which belongs to the decedent and can be returned to the family/next of kin. The appropriate authority must distinguish between personal property and physical evidence. The decedent's personal property must be safeguarded to ensure proper processing and return to the next of kin. Physical evidence on or near the body must be safeguarded to ensure chain of custody and its availability for further evaluation by forensic specialists.

6-63. The investigator must ensure that all items, personal property, and/or physical evidence are removed prior to the closure of the scene and relinquishment by officials. After a scene is turned over, it will require a search warrant to reenter the scene. Additionally, once law enforcement personnel have left the scene, the investigator may not return without the permission of the owner.

6-64. One of the most (if not the most) important factor in a death scene investigation is the handling of evidence. Most of the clues that lead to the solution of a crime are at the scene in the form of physical evidence. Physical evidence is any material item at a crime scene that would prove that a crime was committed, that could link a suspect to a scene or victim, that could establish the identity of a victim or suspect, and/or establish key elements of a crime. Physical evidence collected from a scene is the cornerstone upon which successful case resolution depends. The death scene investigator must be proficient in recognizing, collecting, preserving, packaging, and processing physical evidence.

**Chapter 6**

---

***Physical Evidence***

6-65. All physical evidence on the body should remain in its original position—to the maximum extent possible—and be protected while the body is transported to the morgue. Frequently there is evidence on the body that may not be visible to the naked eye. Trace evidence is very small—often microscopic—physical evidence that can be discovered on a body. Trace evidence is difficult to recognize, locate, and collect. Although microscopic, trace evidence is often a significant part of an investigation. It is often helpful in placing a suspect at a scene or in contact with a particular item or individual. Clothing is an excellent source of trace evidence. Footwear, the victim's body, the suspect's body, tools used as weapons, tools used in burglaries, and a vehicle used in a hit-and-run are additional examples. The variety of types of trace evidence is almost endless. Some examples include fibers, textiles, hair, blood, glass, soil, paint, metals, rope, cigarettes, tobacco, burned paper, ash, vegetation, foodstuffs, cosmetics, tape, and electrical wires.

6-66. When an individual comes into contact with a person or location, exchanges of trace evidence will often occur. Locard's Exchange Principle states that anytime someone enters a crime/death scene, they either bring something in or take something out with them. Every contact leaves a trace. The importance of exchange/transfer of evidence is that it links suspects to victims or locations. The linkage of trace evidence is directional in that it is equally important to find physical evidence from the suspect on the victim and evidence from the victim on the suspect.

6-67. The appropriate authority will collect any physical evidence that is related to the death and make it available to the medical examiner. Any item that is on or attached to the decedent is under the control of the medicolegal death investigator. Any item at the death scene that is not on or attached to the decedent is under the control of the law enforcement agency.

6-68. The appropriate collection and packaging of different types of physical evidence is very important. Improperly collected and/or packaged evidence can be compromised or even obliterated before it reaches the laboratory. Therefore, it is strongly recommended that only trained criminalists or crime scene evidence specialists collect, mark, preserve, and package evidence. The following general guidelines are offered.

- Place evidence in a sterilized container. Contrary to popular belief this container is almost never a plastic bag.
- Secure physical evidence in suitable containers so that the evidence can be preserved and transferred safely.
- Place each item of evidence in a separate container.
- Seal all evidence containers with evidence tape at the scene at the time of collection. (The evidence tape should completely cover any openings of the container and be marked with the collector's initials and date and time of collection. The marks should extend over the edge of the evidence tape onto the package itself.) (See figure C-1.)

6-69. A variety of packaging materials, sealing tape, and assorted evidence collection materials are commercially available. Different types of evidence require different packaging.

- Most evidence can be collected in paper containers, such as bags, envelopes, packets, and boxes.
- Liquids can be stored in nonbreakable, leak-proof containers.
- New, unused, lined paint cans or glass jars with screw-cap lids are used for arson evidence or other volatile materials.
- Small items (such as hair and fibers) should be folded up in a sheet of paper (pharmaceutical/druggist fold) and then placed in an envelope. Alternately, they can be placed in a glassine bag.
- Wet evidence of a biological nature (such as blood) should be allowed to air dry before packaging. If this is not possible, wet evidence of a biological nature should be packaged preferably in paper and permitted to air dry as soon as possible.
- Plastic can be used in a judicious and timely fashion—although plastic can draw moisture and permit the growth of microorganisms, which can destroy or alter evidence (refer to appendix C).

***Personal Property***

6-70. Describe jewelry as to style, type, color, and location on the body. All descriptions of jewelry should be generic, not specific. For example, never describe a ring as gold with a diamond; describe it as yellow metal with a clear stone. This process should always be conducted in the presence of a witness. Do not remove jewelry from the body.

6-71. Count money and list the amount using the denominations of currency present following jurisdictional protocols. Note credit card details.

6-72. Examine personal papers to determine if they contain identification information or notes of intent of self-harm or suicide.

6-73. The appropriate authority should confiscate all illicit drugs and paraphernalia; prescription, over the counter, and homeopathic medications; and alcoholic beverage containers, when appropriate. These items will be conveyed to a toxicologist and will be vital in determining what, if any, contribution these items made to the death. The investigator should note the location of these items as there is a strong likelihood that the fatal item will be found in the same room as the decedent.

6-74. Ensure that the property form/chain of custody includes the date and case number and is signed by both the investigator and witness. Seal the personal property in a bag or envelope and release it to the proper authorities.

**Interview Witness(es) at the Death Scene**

6-75. Jurisdictional policies dictate who should be interviewed at a death scene and by whom. The investigator must be knowledgeable about these procedures and act accordingly.

6-76. Interviews should include basic information such as the decedent's identification; time, date, and physical condition when last seen alive; time, date, and location of the discovery of the body; the individual who discovered the body; medical, social, and employment history; and any other events that may have a bearing on the death.

6-77. If possible, the investigator will collect the following information from every witness interviewed:

- All available identifying data (full name, address, date of birth, and work, home, and/or mobile phone numbers).
- The relationship/association, if any, of the witness to the decedent.
- The basis of the witness' knowledge (how does the witness have knowledge of the death?). The investigator will note any discrepancies between the witness' statement and the appearance of the scene and any discrepancies between witnesses' statements.

6-78. When conducting an interview, the investigator should be assertive without being aggressive. He must have control of the situation. Provide guidance and structure to the interview (especially when dealing with distraught family members). Be aware of body language and present a neat appearance. Maintain eye contact, exude confidence, and speak slowly. A medicolegal death investigator is a good listener.

6-79. Whenever possible avoid technical terms. Explain investigative and medical procedures in words that are easily understood by the layperson. When providing notification of death, avoid expressions that may be misunderstood or lead to confusion and misinterpretation. Terms such as "expired," "passed away," "bit the dust," should never be used. There is no confusion/substitution for the words "death," "died," or "deceased."

**DOCUMENT THE BODY****Photograph the Body**

6-80. Photographic documentation of the body at the scene creates a permanent record of body position, identity, final movements, and appearance. Photographs are irreplaceable for studying the death scene later. They will assist in proving or disproving the consistency of the defendant's story and may be submitted as

**Chapter 6**

---

evidence. Ideally, the investigator should obtain both instant and permanent high-quality photographs of the body.

6-81. The body should be photographed as it was initially discovered, before either it or associated physical evidence is moved. Photograph both the body and the immediate scene. Take photographs that depict the relationship of the victim to physical evidence.

6-82. The decedent's face should be photographed. The face, and the rest of the body, should never be cleaned for a photograph. Take multiple shots if necessary.

6-83. Take at least two photographs of the body at 90-degree angles to each other. Take overall and close-up photographs of the body from four directions.

6-84. Take close-up photographs of all wounds, injuries, and/or marks observed on the body at both an intermediate and close-up distance. Photograph any physical evidence or items that have potential to be physical evidence. Take as many photographs as needed to adequately document the body. Photograph the decedent with and without a scale.

6-85. Take additional photographs after items that interfere with the photographic documentation have been removed. An example of this would be the removal of a body from a vehicle.

6-86. Photograph the opposite side of the body after it has been turned over (after the external examination). Photograph the surface beneath the body only after the body has been removed.

**Conduct a Superficial External Body Examination**

6-87. After the body has been photographed, conduct a thorough and systematic external examination of the body at the scene. The death investigator's main responsibility is to determine as much as possible about the death from the decedent at the scene. The external examination provides the death investigator with objective data on the most single important piece of evidence at the death scene—the body. The examination provides details concerning the decedent's physical attributes, relationship to the scene, and possible cause and manner of death.

6-88. The external examination does not include any analyses on the body at the death scene—do not take fingerprints, do not collect trace evidence/residue, do not remove clothing, do not clean the body, and do not place anything on the body that might interfere with future examinations.

6-89. Assess the body in a methodical fashion—begin at the top of the decedent's head and progress downward, concentrating equally on all portions of the body. It is better to begin the examination without turning the body over. If the decedent is lying on his/her back, examine the front of the body first and vice versa. Place a clean white sheet next to the body and roll the body onto the sheet when the other side of the body is to be inspected. The sheet prevents contamination and/or loss of evidence.

6-90. When the examination is complete, the sheet will serve to encase the body. Both ends of the sheet are secured/knotted before placement in a human remains pouch.

6-91. The hands, feet, and head, when necessary, should be placed in paper bags and secured with a rubber band or evidence tape. Do not place the rubber bands or evidence tape on the skin of the decedent; place them on the paper bags.

6-92. Each body should have an identification tag securely attached before transport to the morgue.

6-93. Document the decedent's position (for example, supine or prone)—this may help establish if the body was moved before discovery. Describe the location where the body was found—this may have a bearing on trace evidence on and around the body. Document the direction of the body (for example, head to the west and feet to the east).

6-94. Document the environment in which the decedent was found, as the environment has a definite impact on the rate of decomposition. Note temperature, wind, precipitation, moisture, and the surface on which the body was resting.

6-95. The death investigator should document a full description of the decedent. Describe the demographic profile of the decedent—include sex; skin color, approximate age (or date of birth, if known); approximate height (note if measured or estimated); approximate weight (note if weighed or estimated); hair color, length, and style; eye color (contacts or eye glasses); clothing; jewelry; tattoos; scars; and state of nutrition, cleanliness and dental care.

6-96. To the extent possible, document the clothing worn by the decedent. Describe all items worn (color, fabric, type), their state of cleanliness, their position, appropriateness of size, appropriateness in manner worn, and appropriateness for the weather and location. If the clothing is inappropriate for the weather and location where the decedent was found, the discrepancies must be explained. Describe if the clothing is consistent with normal dressing techniques. Note if any portion of the clothing is out of place. Document the location of any cuts, tears, or defects in the clothing as they may be consistent with trauma to the body.

6-97. Document the presence or absence of injury, trauma, abnormalities, unnatural-appearing marks, scars, and/or tattoos to the body. Document the presence of medical treatment or resuscitative efforts.

6-98. After the body is moved, carefully inspect beneath the body for additional evidence/information.

### **Document Cause, Manner, and Time of Death**

6-99. Documentation of postmortem changes is essential to determine an accurate cause and manner of death, to provide information on the time of death, to corroborate witness statements, and to determine if the body was moved before law enforcement personnel arrived.

6-100. There are numerous methods that, when used in conjunction, will provide for an estimation of time of death. Use a combination of all available evidence. Weigh the evidence and be suspicious when some factors seem to deviate considerably from the others.

6-101. It is important to assess the state of rigor mortis and specify the time and place of the assessment. State if rigor mortis is not present or just beginning, if the extremities bend with some difficulty, if the extremities bend with much difficulty, or if the extremities will not bend.

6-102. Describe the presence or absence of livor mortis, its location on the body, and its color. Color can indicate cause of death. For example livor that is cherry red indicates (carbon monoxide or cyanide poisoning or hypothermia).

6-103. Body temperature (algor mortis) can be measured using scientific measuring equipment, such as a telethermometer. If no such equipment is available, then the investigator can touch (wearing gloves) an uncovered portion of the body and determine if the temperature is hot, warm, cool, or cold.

6-104. If the body stays at the scene for more than 1 hour after the initial assessments have been made, then a second set of assessments (rigor mortis, livor mortis, and body temperature) should be made.

6-105. Document the stage of decomposition, insect activity, and plants around the body, if present.

6-106. To aid in estimating time of death, determine when the individual was last seen alive and by whom. Document the remarks, name, address, phone number, and relationship of the individual who last spoke with or saw the individual alive. Document the remarks, name, address, phone number, and relationship of the individual who discovered the body. Also focus on why the individual found the body.

6-107. Document the decedent's daily activities and ordinary habits. Question friends, relatives, and neighbors to discern if the decedent engaged in any unusual activities shortly before death, what was the decedent's usual waking, sleeping, and eating habits. Answers to these questions may help narrow the time of death.

6-108. The death scene investigator should note—

- If there is uncollected mail or dated items (such as a newspaper or a sales receipt).
- If the alarm clock is set.
- If food is in the refrigerator and/or on the stove and what the condition is of the food (fresh, outdated, spoiled).

**Chapter 6**

---

- The last meal consumed.
- If animals are in the house, what is their condition.

6-109. The death scene investigator must gather information that relates to the cause and manner of death. The type of death will dictate the information that the investigator will need to document. The questions that an investigator should ask in a drowning are different than those in the case of a self-inflicted gunshot wound.

6-110. Any blood splatter/patterns found on or near the decedent should be photographed, both with and without a measuring device, before the body is moved. Splatter and flow patterns should be consistent with gravity. Discrepancies should be noted.

6-111. Any items or substances that may have caused or contributed to the death should be noted, photographed, and collected by the proper individual.

6-112. The results of the superficial external examination of the body may yield information regarding the cause and/or manner of death. The death scene investigator should note any marks of violence (stab wound, gunshot wounds), ligature marks, or physical restraints. Are defense wounds present, indicating that the decedent put up a struggle? The death investigator should be able to recognize the effects of different types of trauma to a body that may allow him to establish the cause and manner of death. (For details, refer to chapter 3.)

**Preserve Evidence on the Body**

6-113. Photographic and written documentation of evidence on the body establishes a permanent record of the evidence. To maintain chain of custody, the death investigator must collect, package, preserve, and transport evidence properly. In addition to physical evidence present on the body, body fluids (such as blood) must be photographed and documented prior to collection and transport. Remember that any item that is on or attached to the body belongs with the body and therefore to the medical examiner/coroner.

6-114. Photograph the evidence that is associated with the body.

6-115. In addition to proper collection, packaging, preservation, and transport of evidence, the death investigator should know the potential examinations that can be conducted on evidence. Evidence may include insect casings, maggots, body fluids, cartridge casings, pill containers, weapons, and so forth. The death scene investigator should be able to recognize the various types of analyses that are performed on evidence and where the analyses can be done.

6-116. The death investigator should document all body fluids (froth, purge, or other substances) as to location and pattern before the body/samples are transported.

6-117. Typically the physical evidence, clothing, personal effects, and equipment on a body should remain in its original position and be protected when the body is transported to the morgue. However, ammunition and firearms and other potentially dangerous items, such as a syringe, do not remain with the body. In some rare instances, the investigator may collect trace evidence (blood, hair, fibers) before transport of the body to the medical examiner. He should be knowledgeable of jurisdiction procedures for evidence collection.

6-118. Ensure that the decedent's hands, feet, and head, if necessary, were properly bagged. When such precautions have been taken to preserve evidence, they should be documented in writing.

**Ensure the Security of the Remains**

6-119. Ensuring the security of the remains facilitates proper identification of the remains, maintains chain of custody of the remains and associated evidence, and safeguards personal property.

6-120. It is essential that the death investigator assures that the body reaches the medical examiner in the same condition as it left the scene. Prior to the body leaving the scene, the death scene investigator must ensure that the body is protected from postmortem trauma, tampering, and/or contamination.

6-121. The death investigator may be a part of the labeling, packaging, removal, and transfer/transport of the remains. Place an identification tag on the body to prevent misidentification upon receipt at the medical examiner's/coroner's office. This function also serves to protect all potential physical (trace) evidence and/or property and clothing on the body.

6-122. Place the body in a clean, secured white sheet. The death scene investigator should then supervise the placement of the decedent into a human remains pouch.

6-123. The responsibility for custody of the body varies from jurisdiction to jurisdiction. The proper authority should be familiar with all individuals who will be in contact with the body from the time it leaves the scene until it reaches the medical examiner's office. If any problems arise regarding the respectful and careful handling of the decedent, these issues should be immediately addressed and resolved.

### **Participate in the Scene Debriefing**

6-124. A scene debriefing is the best opportunity for all participants to communicate special requests, share data regarding particular scene findings, and establish clear lines of responsibility.

6-125. The scene debriefing helps all investigators establish post scene responsibilities. Responsibilities include, but are not limited to, the individual responsible for the identification of the decedent, the individual who will notify the next of kin, the individual responsible for media relations, and the individual responsible for evidence transportation.

6-126. During the debriefing, participating investigators can communicate the need for assistance from outside agencies and additional specialists—such as social services, anthropologists, crime laboratory technicians, and so forth.

6-127. Confidentiality must be maintained when using additional outside agencies.

## **ESTABLISH AND RECORD THE DECEDENT'S PROFILE/DEMOGRAPHIC INFORMATION TO FACILITATE IDENTIFICATION**

### **Document the Discovery History**

6-128. The death investigator, or other responsible authority, must establish a decedent's profile which will, in turn, facilitate subsequent investigations of the case. The death investigator must document the individual(s) who discovered the body, where it was discovered, and when. The investigator should record why/how that particular individual(s) discovered the body and the circumstances surrounding the discovery.

### **Determine Terminal Episode Information**

6-129. Any contributing factors that may have played a significant role in determining cause and manner of death should be documented to assist the medical examiner/coroner in his examination of the body. (Refer to chapter 7.)

6-130. The death investigator should document when, where, how, and by whom the decedent was last seen alive.

6-131. The death investigator should document the incidents prior to death, including any resuscitative attempts.

### **Document the Decedent's Medical History**

6-132. In both sudden/unexpected deaths and natural deaths a detailed medical history may aid in determining cause and manner of death. In natural deaths, the thorough medical history helps to focus the medical examiner's investigation.

**Chapter 6**

---

6-133. The decedent's medical history determines the need for a postmortem examination and/or additional laboratory tests. The relationship between disease and injury may play a role in the cause and manner of death. Medical history helps to exclude other causes and manners of death and may be such that an invasive autopsy is not needed.

6-134. The death investigator should contact the decedent's medical provider(s) to obtain medical records. The investigator should ask the physician questions concerning any previous illness, therapy, or diagnoses. The investigator should document the decedent's medical history, including medications taken, and a family medical history from family members.

6-135. The death investigator should request medical records from hospitals or medical treatment facilities, if necessary, to confirm the decedent's medical history and treatment.

**Document the Decedent's Mental Health History**

6-136. If necessary, a detailed psychiatric history should be obtained. The decedent's mental health history may provide insight into the behavior/state of mind of the individual during the time preceding death. This information, in turn, may aid in establishing the cause, manner and circumstances of death.

6-137. The death investigator should document the following:

- Decedent's mental health history, including hospitalizations and treatment by mental health professionals.
- Family mental health history.
- Any history of suicidal tendencies, gestures, or attempts.

**Document the Decedent's Social History**

6-138. The death investigator, or other authority, should gather information from sources familiar with the decedent concerning the decedent's social history. This information may help determine the cause, manner, and circumstances of death.

6-139. The death investigator should document the following:

- Marital/domestic history, domestic abuse, and family history concerning similar deaths and significant dates.
- Relationships, friends, associates, and sexual history.
- History of smoking, amount of alcohol consumption, and/or use of illegal or therapeutic drugs.
- Employment, financial, and criminal history.
- Educational background.
- Daily routines, habits, and activities.

**Establish the Decedent's Identification**

6-140. Positive identification of the decedent allows for notification of next to kin, grief resolution for survivors, settlement of estates and insurance claims, resolution of criminal and civil litigation, disposition of the remains, basic human dignity and respect, and completion of the death certificate. The state of human identification falls into one of three categories—unidentified, presumptive, or positive.

***Unidentified***

6-141. Unfortunately, despite exhaustive efforts by forensic experts there are some remains that may never be identified. These cases are frequently where individuals are unknown, decomposed, mutilated, skeletonized, or incinerated. Victims of mass casualties and military operations may also be difficult to identify. Unidentified individuals should be described as to the location where found.



**Presumptive**

6-142. Presumptive identifications are typically made on skeletal, badly decomposed, or burned remains. An individual who is a presumptive identification should not be designated as a John Doe, Jane Doe, or Baby Doe. The individual should be designated as BTB.

---

*Note.* Skeletal remains should be examined by a forensic anthropologist (refer to chapter 9 for details).

---

6-143. Presumptive identification (from clothing and portable personal property found on or near the body) and circumstantial identification (from the location found, such as residence, work place, or vehicle) is perilous and should be avoided. Personal property is portable and can easily be added to or removed from the decedent. A presumptive identification may, however, be made at times (depending on the circumstances in which remains were discovered). For example, virtually incomplete human remains are discovered in a residence completely destroyed by fire. The occupant of the home was last seen in the home and there is no reason to believe that anyone else was present in the house. Therefore, a presumptive identification can be made based on a probability of circumstance or circumstances.

6-144. A comparison of antemortem and postmortem radiographs is frequently used as a means to establish identification. The concurrence between the radiographs does not always ensure a positive identification. A presumptive identification can be made if the radiographs are consistent and all other possible individuals have been eliminated from the identification process.

6-145. Physical features, such as birth marks, tattoos, scars, surgical procedures, and other physical anomalies are useful in establishing a presumptive identification. Depending on the particular case, the presence or absence of such features will help establish a possible identification or eliminate possible individuals from the identification process.

6-146. Although visual identification is the most common and easiest method of identification, it is the least reliable. It is a subjective means of identification, it is not scientific, and problems may arise. Injuries, burns, mutilation, and decomposition can lead to extensive disfigurement and make a visual identification impossible. Many people bear a close resemblance to one another. Family members may be in a highly emotional state, in shock, or denial. In some cases, the identifier may have something to gain from a misidentification of the body, such as insurance fraud or covering up a murder.

**Positive**

6-147. Positive identifications are based upon scientific methods, such as fingerprint comparison, dental, DNA, radiographs, and/or autopsy findings compared with antemortem medical records. (Refer to chapter 8 for details.)

**MAINTAIN ETHICAL AND LEGAL RESPONSIBILITIES****Maintain the Dignity of the Decedent**

6-148. The decedent's body must be treated with dignity, reverence, and respect. The decedent's rights must be protected. The decedent has a name, family, and friends. Morgue humor can be a destructive force in the life of the death investigator—it is inappropriate, distasteful, and if excessive requires disciplinary action. Inappropriate gestures, touches, and statements must not be tolerated. The death investigator has a professional responsibility to maintain the dignity of the deceased.

**Safeguard Personal Property Against Theft**

6-149. Items found on the body at the time of death will eventually be returned to the decedent's next of kin. The death investigator must assume all items on the decedent, no matter how seemingly insignificant, are of values to family members. An item that may appear to be of no monetary value may, in actuality, be of great sentimental value to a family member.

### **Project a Positive/Professional Image**

6-150. The death investigator should take professional responsibility for every death reported to him. The death investigator is accountable to his office and the community for the work he performs. The death investigator must maintain and project a positive, professional image in all interactions with outside organizations and the decedent's family. The death investigator should never judge a family's reaction to death as cultural, social, and ethnic backgrounds will affect their behavior. Volatile and unpredictable situations can develop at a death scene or during interviews with witnesses and family members. The investigator must remain focused and complete the investigation free of prejudices and bias.

## Chapter 7

# EXAMINATION OF FLESHED REMAINS

## OBJECTIVE

7-1. To provide the mortuary affairs Soldier with the knowledge to proficiently process DD Form 890 and assist forensic specialists with autopsies of fleshed remains.

## SCOPE OF THE AUTOPSY

7-2. An autopsy is a postmortem medical examination of a dead body to determine the cause of death. The word “autopsy” is derived from the Greek word “autopsia,” meaning to see for oneself. The autopsy is a series of tests and examinations performed on a body to identify an injury and/or disease that may have caused or contributed to the death. The autopsy provides a permanent legal record of the gross and minute anatomical peculiarities of the individual’s health and cause of death. There are two types of autopsies.

## PRIVATE AUTOPSY

7-3. A private autopsy is typically conducted after legal next-of-kin requests in various circumstances. These situations include, but are not limited to, sudden death, unexpected death, questions concerning patient care, questions concerning the cause of death, alleged malpractice, and refusal of the hospital to conduct an autopsy. Medical autopsies in hospitals require the consent by the next of kin. Hospital autopsies, as a rule, stress internal examinations and are usually satisfied with cursory external examinations.

## FORENSIC AUTOPSY

7-4. The forensic autopsy is a connection between law and medicine and can be performed without the permission of the next of kin for legal reasons. The results of the autopsy furnish the forensic pathologist with the evidence on which to base a medicolegal opinion.

7-5. The forensic autopsy is performed to establish the circumstances preceding and surrounding a death, to determine the cause and manner of death, and to approximate the time of death. Physical evidence will be identified, collected, and preserved. Information gained from the forensic autopsy will be provided to law enforcement agencies, families, attorneys, news media, and others with a need to know.

7-6. The forensic autopsy is performed—

- In deaths due to violence.
- Deaths that are sudden, unexpected, or unexplained.
- Deaths occurring in custody.
- Deaths occurring in unusual places or under suspicious circumstances.
- Deaths involving the possibility of neglect.
- Deaths in which no physician will certify the death as natural.
- Deaths in the workplace.
- To assist in reconstruction of the fatal injury.
- To assist law enforcement agencies in the prosecution of a crime and/or identification of a victim.
- To assist in matters of public health.

## FORENSIC AUTOPSY PROCEDURES

7-7. A forensic autopsy involves both an internal and an external examination, as well as examination of all available information regarding the medical history of the decedent, the circumstances surrounding death, and the scene investigation. The forensic autopsy may include toxicology, histology, chemistry, and/or microscopic examination of tissues and fluids. Forensic autopsies place a higher degree of emphasis on the external examination than do medical/private autopsies. This fact is related to the legal aspect of the forensic autopsy and the expertise of the forensic pathologist, who is trained to recognize patterns of injury, collect physical evidence, and investigate the circumstances surrounding the death. The autopsy report typically includes written documentation, body diagrams documenting injuries and identifying characteristics, and photographs.

7-8. Photographic documentation of the autopsy occurs before, during, and after the autopsy. The body should be photographed before anything is moved, removed, or added to the body. The sequence of photographs should tell the story of the autopsy and proceed logically from one to the other. Typically a photograph of the full-length view of the body is taken. Another standard shot in forensic autopsy photography is the full-face (identification) view. This photograph is taken to establish the identity of the body. Close-up views of injuries, wounds, and organs may be taken.

### EXTERNAL EXAMINATION

7-9. The external examination is a detailed examination of the external surface of the body, from head to toe. It begins before removal of the clothing. During the external examination the forensic pathologist will—

- Examine clothing for the presence of tears consistent with wounds on the body, blood, other body fluids, and foreign/trace evidence.
- Document general body/identification characteristics including, but not limited to, racial group; sex; height; weight; state of nourishment; body build; appearance of the ears, eyes, nose, and mouth; hair color and length; and eye color.
- Document more specific identifying characteristics such as prosthesis, pacemaker, scars, moles, tattoos, skin lesions, needle tracks, or other markings that may aid in identifying the body.
- Document any significant antemortem conditions (amputations, abnormalities, deformities, disfigurements, loss of eye, and so forth) and/or diseases.
- Document postmortem changes—namely, algor mortis, rigor mortis (extent and degree), livor mortis (distribution, dual pattern, color, contact pallor), and putrefactive (decompositional) change.
- Describe and take inventory of clothing, jewelry, valuables, personal effects, and physical evidence.
- Document specific injuries either by grouping them according to anatomical location or in numerical order. In cases of multiple injuries, the numbering sequence does not imply the order in which the injuries were inflicted or degree of severity. Injuries are described by type (abrasion, laceration, stab wound and so forth), location, size, shape, pattern, and color.
- Describe evidence for medical intervention. This includes all medical equipment attached to, or accompanying, the body—such as, a urinary catheter or intravenous lines. External surgical incisions are described in continuity with the internal evidence of surgery.
- Depending on the nature of the death, collect certain biological and trace evidence. The forensic pathologist, or trace evidence analyst under the pathologist's supervision, collects trace evidence—such as glass, hairs, and fibers—from the clothing and body for examination by other forensic specialists. Biological evidence—such as semen, saliva, tears, and perspiration—can be collected from the external body.
- Take fingerprints, palm prints, footprints, or any combination thereof.
- Take photographs.
- X-rays will be taken to document injuries or to aid in the identification process. If antemortem X-rays exist, then the forensic pathologist may take X-rays during autopsy for comparison of

features as a means of identification. X-rays are also used to locate bullets, foreign metallic fragments, and metal appliances from surgical procedures.

## **INTERNAL EXAMINATION**

7-10. The internal examination is a systematic dissection of the body and the removal of internal organs for observation. The pathologist—

- Exams every body organ and records the results. He provides a gross description of body organs to include weight, appearance, and any abnormalities observed.
- Describes diseases, chronic or previously unknown,
- Describes internal injuries in connection with related external injuries. The internal trajectory/course of injuries is charted.
- Records negative observations (observations that there are no injuries or abnormalities of the organs). A statement that a certain finding is not present can be as important as a positive finding. These statements are included in the autopsy report to verify that a certain part of the anatomy was, indeed, examined.
- Collects biological specimens (an essential part of every forensic autopsy). Biological samples, tissue samples for histology slides, and toxicology specimens are typically taken. The Armed Forces Institute of Pathology recommends taking the following samples during autopsy: blood (up to 100 milliliters); urine (100 milliliters); bile (all available); vitreous (all available); liver (100 grams); brain (100 to 200 grams); kidney (50 grams); lung (50 grams); and gastric (50 grams).
  - Whole tissue, cells obtained from tissue, blood, organs, eye fluid, gastric contents, and body fluids are sources of biological samples. Biological samples may be taken for a number of reasons including, but not limited to, DNA testing, determination of alcohol content, presence of drugs, and presence of disease. Specimens are also taken for toxicological analysis. Toxicology analysis provides tests and analysis of the role that drugs and toxic agents played in the cause and manner of death.
  - Histology is the study of the minute structure of tissues, basically at the cellular level. The tissue samples taken by the pathologist are frozen, cut in a chamber, mounted on a slide, and stained for immediate review. Or samples may be fixed, paraffin embedded, cut and stained for later review. The paraffin embedded tissue is stable for many years of storage. This process provides a view of the tissue at the cellular level to help the pathologist diagnose cause of death.
- Takes photographs.

## **CAUSE, MANNER, AND MECHANISM OF DEATH**

7-11. Two of the most important functions of the forensic pathologist are the determination of cause and manner of death. The forensic pathologist—using autopsy findings, laboratory tests, and the facts concerning the circumstances leading up to the death—forms an educated opinion on the cause and manner of death.

### **Cause of Death**

7-12. The cause of death is the forensic pathologist's medical opinion concerning any injury or disease that started the events that lead to the death. It is the specific reason that a person dies. Several examples of cause of death are: gunshot wound, stab wound, heart disease, AIDS, drug overdose, strangulation, and hanging.

### **Manner of Death**

7-13. The manner of death explains how the cause of death came about. Manner of death is basically a medicolegal opinion made by the forensic pathologist based on the individual's history, the circumstances of death, autopsy findings, and any substantiated investigative information. Manner of death is listed as

**Chapter 7**

---

natural (absence of hostile environment/caused by disease), homicide (someone else caused the victim's death), suicide (the victim caused his/her own death intentionally), accident (presence of a hostile environment/caused by violent means), or undetermined. While homicide is a neutral term, suicide requires evidence of intent.

**Mechanism of Death**

7-14. Mechanism of death is the physiologic reason for an individual's death. It is produced by the cause of death. For example, an individual is discovered hanging (cause), dies of asphyxia (mechanism), and the death is ruled a suicide (manner). Or an individual is shot in the abdomen (cause), dies of massive internal hemorrhaging (mechanism), and the death is ruled a homicide (manner).

**TIME OF DEATH**

7-15. The forensic pathologist will attempt to determine time of death. Determining time of death is based on eyewitness accounts and changes in the appearance and characteristics of the body after death. Determining the interval between the time of death and the time the body is found can be difficult. The exact time of death cannot be determined, unless witnessed. All the methods used to determine the time of death are not precise; instead, they usually give relative indicators. They are estimations. As the amount of time between death and the attempt to determine the time of death increases, the estimate is less precise and there is a greater chance for error. There are numerous individual observations when used together will provide the best estimate of the time of death. These are rigor mortis, livor mortis, algor mortis, decompositional changes, and stomach contents. Environmental conditions and the physical characteristics of an individual must also be considered as they impact and affect these observations.

**Rigor Mortis**

7-16. Rigor mortis is the stiffening of the muscles after death due to chemical changes in the muscle fibers. Muscular relaxation immediately after death is followed by the onset of rigidity and shortening of the muscle. All muscles of the body begin to stiffen at the same time and the same rate. However, different muscles appear to stiffen at different rates because of their size. The small muscles of the cheek, jaw, face, hands, and feet appear to stiffen first followed by a gradual spread to the large muscle groups. A body is said to be in full rigor when the jaw, elbow, and knee joints are immovable.

7-17. Rigor mortis usually appears 2 to 4 hours after death, peaks between 6 and 12 hours, and disappears between 12 and 36 hours. Rigor mortis passes as muscle decomposition begins, usually between 24 and 36 hours. As rigor disappears, the muscles will begin to loosen in the same order they appeared to stiffen.

7-18. Body temperature, physical activity before death, cocaine, amphetamines, and the environment where the body was found will affect the onset of rigor mortis. For example, the higher the body temperature, the sooner rigor occurs. Rigor develops more quickly if an individual was involved in strenuous physical activity just before death. Rigor is accelerated in warmer environments and slowed in cooler environments.

7-19. When a body stiffens, it will stay in position until rigor passes or if rigor is physically broken. If rigor is broken by manipulation of a particular joint, it does not reappear in the same area. Rigor mortis is typically less set in the old and young.

7-20. Rigor mortis does not "defy" gravity. If the arms and legs of a body are raised above the surface into the air, the body has been moved after rigor had begun.

**Livor Mortis**

7-21. Livor mortis is the reddish-violet discoloration of the body after death. It is caused by the settling of the blood in vessels, through gravity, in the dependent areas of the body (such as on the back of an individual lying supine). Some dependent areas will not discolor because the bones will compress the skin against a hard surface and prevent the settling of blood. These areas will appear pale in contrast. For

example, if a body is on its back, the area below the elbows, scapulae, and buttocks will be pale. This is called "contact pallor."

7-22. Livor mortis is noticeable approximately 1 to 2 hours after death and develops gradually until it becomes fixed between 8 and 12 hours. Turning the body cannot displace livor once livor has fixed. Livor mortis will be visible until the body becomes completely discolored by decomposition.

7-23. Livor mortis is important in determining if a body has been moved after death. If a body is discovered face down and there is livor mortis on the back, then at the time of death the body was on its back. If a body is moved after partial development of livor, a dual pattern, called shifting, may result.

7-24. The color of livor mortis may provide an indication relating to cause of death. A cherry red color suggests carbon monoxide or cyanide poisoning or hypothermia. A green-brown color suggests drugs or poisons affecting hemoglobin formation in the blood. A dark blue discoloration suggests asphyxia.

### **Algor Mortis**

7-25. Algor mortis is the cooling of the body after death to the ambient (surrounding) temperature. Some physicians use body temperatures to determine time since death. The most reliable readings are obtained from the liver and rectum. The reading is entered into a formula to calculate time since death.

7-26. The temperature of the body may rise 1.0 to 1.5 degrees in the first few hours after death, and then begin to fall. The body starts to cool approximately 2.0 to 2.5 degrees Fahrenheit per hour in the first 6 hours after death. Between 6 and 12 hours, the body cools at approximately 1.5 to 2.0 degrees Fahrenheit per hour. Between 12 and 30 hours, the body cools at approximately 1.0 to 1.5 degrees Fahrenheit per hour.

7-27. There are numerous variables that affect algor mortis. These include environmental conditions and temperature, illness, body fat, body surface area (infants cool more quickly), the surface the body was lying on, the amount of clothing worn, air currents, and body temperature at time of death. The determination of time since death by algor mortis depends on two assumptions that may or may not be true.

- The first assumption is that the body temperature at the time of death was the normal 98.6 degrees. Level of physical activity, drug and alcohol use, exposure to cold, and shock are some examples of factors that can affect normal body temperature.
- The second assumption is that a body cools at a constant, uniform rate. As stated, many factors affect the rate at which a body loses heat.

### **Decomposition**

7-28. Decomposition (putrefaction) is the sequence of physicochemical events that begins with death. It results from cell destruction and the actions of internal and/or external bacteria. Bacteria from the intestinal tract and wounds enter the blood vessels and tissue through the walls of the intestines and from the external environment.

7-29. Rates of decomposition depend on a variety of factors including, but not limited to, temperature, humidity, precipitation, soil composition, insect activity, presence or absence of clothing, body weight and size, and where the body was discovered. A generally accepted approximation for degree of decomposition is that 1 week in air is equivalent to 2 weeks in water and 8 weeks in soil. Thus, a body on the ground surface will decay before a body in the water. A body in water will decay before a body buried in soil. Rates of decomposition are not precise and differ in different parts of the country. The following is a general picture of decomposition.

- As rigor passes, the skin turns greenish in the right lower abdomen (24 hours) and then spreads through the rest of the abdomen (24 to 36 hours).
- The face will swell/bloat and marbling will appear (36 to 48 hours). Marbling is a greenish-black coloration along the vessels.
- The body will go through general bloating from the gas formed by the bacteria. The body is now a pale green to green-black color. Increased internal temperature caused by bacterial gas

**Chapter 7**

---

production forces body fluids out of body orifices, a process called purging (60 to 72 hours). Typically decomposition occurs more rapidly in areas of injuries.

- Between 4 and 7 days localized collections of fluids appear in the epidermis (skin blebs). Hair sloughing and skin slippage occurs. Over days and weeks, body tissues dehydrate and skeletonization occurs.
- After complete skeletonization, the bones will slowly weather and break down. This process can last decades or centuries. The effects of weathering include bleaching, exfoliation of the cortical bone, and demineralization. As with fleshed remains, the rate and severity of these decompositional changes are affected by environmental conditions.
- Alternatives to decomposition include mummification and adipocere formation. In mummification, the body dries out faster than decomposition takes place. Mummification typically occurs in hot, dry environments. In adipocere formation, the tissues are transformed into a wax-like substance that acts as a preservative. Adipocere ('grave wax') forms in the absence of free oxygen and in a wet, cool environment, such as a water burial (a drowning victim, for example), an airtight but moist crypt, or a moist grave.

**Stomach Contents**

7-30. The volume and type of food present in the stomach at autopsy may be used to identify the composition of "the last meal" and estimating the time interval between eating and death. Estimating time since death based on stomach volume is, however, very imprecise. For example, a body discovered in the late afternoon with breakfast type food in the stomach would suggest that death occurred in the morning. A variety of factors affect this estimation of time since death. These include, but are not limited to, weight of the meal, liquid content of the food, caloric content, amount of chewing, and composition of the food. In general, however, a light meal is digested in 1 to 2 hours and a heavy meal takes between approximately 4 and 6 hours. The intestine usually empties between 10 and 12 hours after the last meal.

**Forensic Entomology and Forensic Biology**

7-31. Environmental conditions at the scene can help experts determine the time since death. Entomological and botanical data together may narrow the time of death to weeks or months.

7-32. Medicolegal forensic entomology is the branch of entomology that focuses on legal investigations. Medicolegal forensic entomology uses insects that inhabit decomposing remains to aid criminal/legal investigations. The identification of insects collected from or near corpses depends on a fully qualified forensic entomologist. Typically a forensic entomologist is consulted in a death investigation to provide an estimation of PMI, to help determine if the body was moved after death, and/or to help determine if the body was disturbed at some time. However, the primary application of forensic entomology is to determine the PMI, which can be accomplished in one of two ways. The method used is dictated by the circumstances of each case.

7-33. When the PMI is from 1 month and up to a year or more, then the forensic entomologist analyzes the successive wave of insects that are present on the remains. Each stage of decomposition attracts different species of insects. Some insects are, however, involved in each stage of decomposition. The first group of insects to arrive on a corpse is the family Calliphoridae—the blowflies. Blowflies, the metallic green or blue flies, can arrive within a few minutes of death in the presence of blood or other body fluids. Other insects, not attracted to fresh remains, arrive later. Some insects arrive to feed on other insects already inhabiting the remains. There is an overlap in the arrival time (succession) of insects that are present on the remains. The different species of insects present on the remains at a given time combined with a knowledge of the local insect population and rates of arrival and development allows the forensic entomologist to determine an estimation of the PMI. The estimation will always be a range of time, not an exact time of death. Knowledge of the succession of insects can also be used to indicate the season of death, such as late summer.

7-34. When the PMI is less than a month, then the forensic entomologist will analyze maggot age and development. If the entomologist knows how long after death the eggs are laid, and how fast the larva grows, then he can estimate the length of time that the corpse was exposed to insects (PMI). This method



can provide a PMI of a day or less if used within the first few weeks of death. The most important insects on the corpse are the family, Calliphoridae—the blowflies. There are four life/developmental stages for the family Calliphoridae—egg, larva, puparium, and adult (figure 7-1). Each of these developmental stages takes a set, known time based on temperature. The insect will develop faster at warmer temperatures.

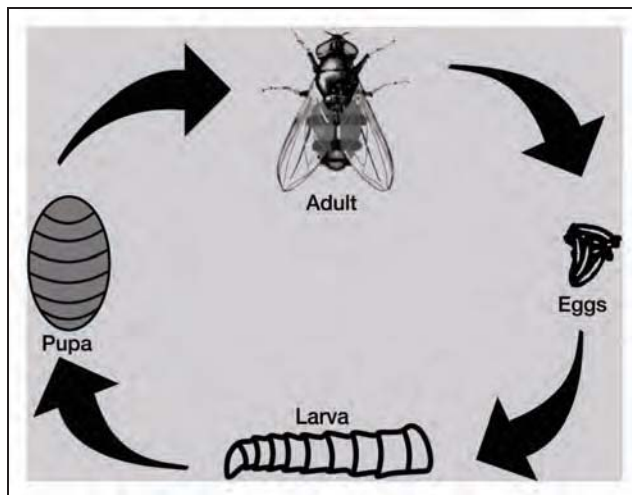


Figure 7-1. The Life Cycle of the Blowfly

7-35. When the female blowfly arrives at a corpse, she lays clumps of white, sausage-shaped eggs. The eggs are typically laid in the natural orifices—such as the mouth, ears, and nasal openings, and wounds.

7-36. After a set period of time, the eggs hatch into a first stage larva, commonly known as maggots. The maggots are white and cone-shaped and grow by eating the corpse. As they grow, they will move from the area in which they were laid to other areas, such as beneath the corpse and along the edges. These larvae molt into the puparium.

7-37. The puparium (plural, puparia) continues to feed for a while until it stops to find a safe place to pupate. During this time, the living insect is inside its hardened outer skin. This outer shell, pupal case, protects the insect as it metamorphoses into an adult. While inside the pupal case, the insect cannot eat or move. The freshly formed pupae are pale in color but darken to a deep brown in several hours. The puparia are frequently overlooked at crime scenes as they are usually not found on the corpse, but rather in the vicinity of the corpse. They are frequently found in the folds of clothing and may also be found up to 30 feet from the corpse.

7-38. After a number of days, an adult fly will emerge from the pupa. The newly-emerged fly does not fly much as its body hardens. At first the fly is pale in color and soft with crumpled wings. The wings expand later and the fly turns blue or green.

7-39. The forensic entomologist can also help to determine if the body was moved after death. Insect species vary by location and can be very particular about the type of environment they inhabit and where they feed or lay eggs. For example, some insects prefer shade, some prefer sun, some inhabit rural areas, and others prefer urban environments. Some insect species are unique to specific geographic regions. Therefore, if the insect species recovered from a corpse at a given location are not native to the location, but rather are from a different location, then it is obvious that the body was moved after death. This information will also provide the legal authorities with an indication of the type of area where the death actually occurred.

7-40. Lastly, maggots can be tested by the forensic pathologist to determine the presence of chemicals in remains. When the maggots feed on a body, they digest any chemicals present in the body. Testing maggots can provide information on suspected poisoning and drug overdose cases.

7-41. Forensic botanists also play an important role in criminal cases. Occasionally vegetation is associated with the remains or site being investigated. Forensic botanists can determine if a body has been moved

**Chapter 7**

---

from the original location and can link plant matter from the scene with that found upon the victim and/or the victim's personal effects. They can also determine the time of year a particular specimen would normally be present, its growth stage, and how much time elapsed since the body was found. Very often, trace botanical evidence can link an object or suspect to the scene of a crime, as well as rule out a suspect or support an alibi. The forensic botanist relies on the facts that plants can be identified through microscopic characteristics—such as seeds, pollens, and spores—and that many plants grow exclusively in particular areas.

## Chapter 8

# PRIMARY IDENTIFICATION OF REMAINS

## OBJECTIVE

8-1. This chapter will provide the mortuary affairs Soldier with the basic knowledge of the three primary methods of identifying human remains. In most cases, these methods are the only scientific means of a positive identification. These methods are dental identification, fingerprints, and DNA profiling (analysis). Footprints are not typically used in the civilian sector as a means of identification. They are, however, used by the U.S. Air Force as means of positive identification. Thus, footprinting will also be covered.

## DENTAL IDENTIFICATION

8-2. Forensic odontology is the study of dentistry as it pertains to the law. It is the branch of forensic medicine that applies dental knowledge to civil and criminal matters. The military expands this definition to include the unique needs of the military services. Dental identification is a definitive means of positive identification of unknown remains. Because teeth are the hardest and most mineralized part of the human body, they tend to survive postmortem events and intervals relatively intact. Whereas soft tissue will not survive immersion in water, decomposition, skeletonization, or mummification, the teeth will. Teeth are relatively resistant to fire. It takes temperatures of over 1,000 degrees Fahrenheit to destroy the teeth. Even in these cases the roots, enclosed in dense alveolar bone, tend to be protected and can be used for identification. In addition, gold alloys, porcelain prostheses, and silver amalgams will withstand temperatures up to 1,600 degrees Fahrenheit.

8-3. Dental remains are typically processed/charted on a dental chart before viewing any antemortem dental records. This practice prevents any bias, in looking for certain features, on the behalf of the recorder. Completing a dental chart is relatively straightforward—but tedious. Attention to detail is a must as the form depicts an exact record of the decedent's dentition. The universal tooth numbering system as described in chapter 5 is typically used on dental charts. A dental chart should illustrate, as graphically as possible, the following:

- Location (tooth and tooth surface), shape, and size of restorations.
- Materials used in the restorations.
- Prostheses, implants, and pins present.
- Teeth present (including supernumerary teeth) or absent (antemortem versus postmortem tooth loss).
- Unerupted/impacted teeth.
- Anomalies.
- Caries, fractures, pathologies, attrition, and abrasions.
- Tooth position (occlusal relationships, misaligned teeth, rotations, diastemas and other occlusal discrepancies).

8-4. Each individual has a potential of having 32 teeth. Each tooth has five different tooth surfaces (incisal/occlusal, distal, mesial, facial, and lingual). Thus, there is a potential of 160 surfaces to chart on a dental chart. When the numerous combinations of teeth (absent, present, restored or not restored), tooth surfaces, and types of restorative dental materials are taken into account, the probability of establishing a dental identification is extremely high. When additional factors—such as pathologies, anomalies, extractions, root form, and dental prostheses—are taken into account, then a unique dental identification can typically be established.

**Chapter 8**

---

8-5. A dental identification may be made solely on the number of teeth present. It is important, therefore, to determine if any missing teeth were lost postmortem or antemortem.

8-6. The distinguishing characteristic used to determine the difference between antemortem and postmortem tooth loss is related to the appearance of the tooth sockets. If a tooth has been lost postmortem, the socket will show sharp edges or borders. Keep in mind, however, that a tooth displaying these characteristics may have been lost a few days antemortem. If a tooth has been lost antemortem, the socket will show signs of healing. Typically the socket will display rounded borders (healing/bone growth) and varying degrees of bone growth in the socket. Bone growth can be observed in as little as 14 days. Within 6 months, the socket will fill in. Within a year there can be complete obliteration of the socket.

8-7. The teeth most frequently lost postmortem are the anterior teeth, the incisors and canines. These are typically single-rooted teeth, which are less firmly secured in the sockets than are the premolars and molars.

8-8. After the dental remains are charted, they are compared to antemortem records to make a dental identification. A high percentage of the general population visited a dentist at some time in their life. The dental charts that dentists create are often maintained for long periods of time. In the military, the SF 603 is a permanent part of the individual's health records.

8-9. Radiographs (X-rays) are indispensable in identifying dental remains. Antemortem radiographs are, perhaps, the single most valuable antemortem dental record for purposes of comparison in dental identifications. Radiographs provide hard evidence of dental records. They are not subjected to human error to the same extent as are written dental records. They present an objective, accurate, and unique record of an individual's dentition. Radiographs show many conditions that are only detectable by this method. As such they are the most desirable antemortem record for dental identification. The U.S. military has mandatory requirements for dental examinations that, in most standards, include radiographs. The records are normally maintained for extended periods of time and are usually available for comparison.

8-10. Radiographs provide additional multiple points of comparison for establishing identification. Comparison of antemortem radiographs to postmortem radiographs allows the forensic odontologist the greatest certainty for establishing an identification or exclusion. Radiographs will depict not only the shape and size of restorations but also additional unique features that are invaluable for a dental identification. Some of these features include root and bone morphology, root and bone pathology, impacted/unerupted teeth, root canals, the shape and size of pulp chambers, anatomical landmarks, and surgical intervention.

8-11. A postmortem radiographic examination should include periapical and bitewing radiographs for comparison to antemortem radiographs. If the equipment is available, postmortem panoramic radiographs should be taken, as these are standard radiographs for military personnel.

8-12. Periapical radiographs (figure 8-1) include the crown and root of the tooth and the surrounding supporting bone and anatomical structures. They are taken separately of the maxillary and mandibular teeth. Typically, two to four teeth will show fairly completely on one of these X-rays. Periapical radiographs can be used for loose teeth, tooth fragments, the sockets of teeth that were lost postmortem, edentulous areas, and areas which may be impacted or extracted.

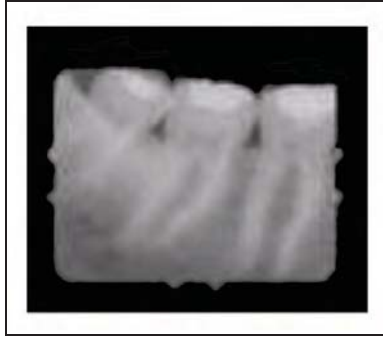

Figure 8-1. Periapical Radiograph<sup>9</sup>

8-13. Bitewing radiographs (figure 8-2) are the most common type of dental radiographs. Frequently, they are the only type of antemortem radiograph available. Bitewing radiographs are taken of the maxillary and mandibular teeth biting together (in occlusion) and show the teeth in close approximation. They show the full crowns of the teeth with the surrounding supporting bone and anatomical structures. They do not, however, show the areas around the end of the roots. If the maxilla and mandible are extremely fragmented, radiographs of this type may be difficult to take. They should, however, be attempted. If it is not possible, then periapical radiographs can be used for separate views of the maxillary and mandibular teeth.

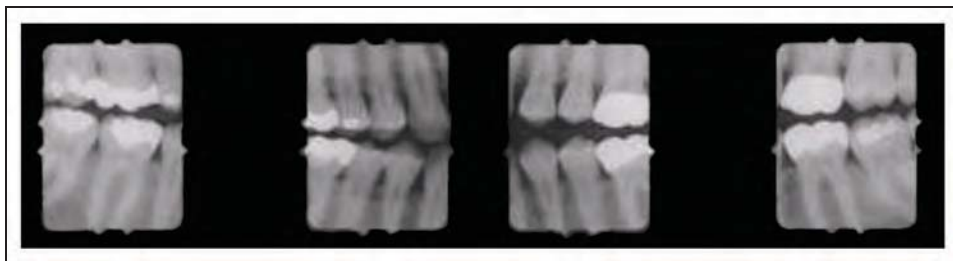


Figure 8-2. Bitewing Radiographs<sup>10</sup>

8-14. A panoramic radiograph (figure 8-3) is one large film that shows the entire status of the mouth. It shows all the maxillary and mandibular teeth and bony supporting structures in a comprehensive view. The temporomandibular joints (where the mandible articulates with the skull at the temporal bone) and the nasal and orbital regions of the skull are also shown.

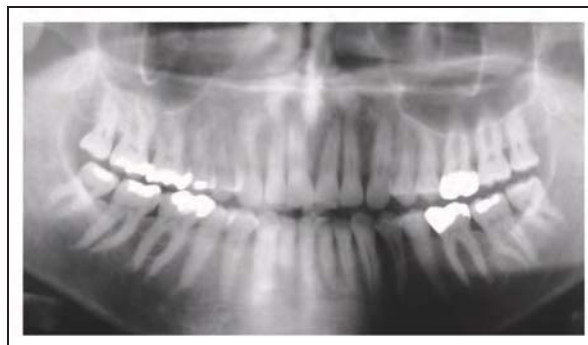

Figure 8-3. Panoramic Radiograph<sup>11</sup>

<sup>9</sup> Dr. Andrew M. Sklar.

<sup>10</sup> Dr. Andrew M. Sklar.

**Chapter 8**

---

8-15. Computer support now plays a major role in forensic dental identification. Antemortem and postmortem information is entered into a database. Screening the dental records from a pool of known individuals involved in a fatality creates an antemortem database. Thousands of comparisons can be made and a list of possible candidates will be generated. This list is ranked to produce a 'most likely' identities list. The forensic odontologist uses the list to assist in the final identification. The list does not make an identification but reduces the number of records that the odontologist has to manually compare. The odontologist will then confirm or reject the 'most likely' list by visual comparison of antemortem and postmortem dental charts and radiographs. The first computer program to gain wide distribution was CAPMI. This DOS program was developed in the 1980s at the U.S. Army Institute of Dental Research to facilitate the rapid identification of remains. WinID has replaced CAPMI. This program was developed by Dr. James McGivney and was initially released as an upgraded version of CAPMI4. WinID codes are an extension of CAPMI codes. WinID has proven useful in mass disaster situations and in creating and maintaining missing person databases.

8-16. The final stage of the forensic dental identification involves comparing antemortem and postmortem dental records and radiographs. With antemortem records and radiographs, postmortem records and radiographs, and the computer-generated results, the comparison process can begin. A comparison table/chart can be made for visual comparison and should contain information on all 32 teeth. The records are compared for similarities and discrepancies. Discrepancies should be examined first as one discrepancy can negate numerous similarities.

8-17. The records are reviewed for significant points of comparison, concordance. It is preferable to have as many points of concordance as possible. However, there is no agreement within the field of forensic odontology on how many points of concordance are sufficient for a positive identification. Each case is assessed individually. The critical factor is to remove subjective judgment calls from dental comparisons.

8-18. After identification has been established, photographs should be taken of the antemortem and postmortem dental radiographs that provided the conclusive evidence of the positive identification.

8-19. Although not conclusive, dental work may provide information on the region of origin and time of the work as well as individualizing characteristics. This information is general and should be treated as such. In a case of a mass disaster the information may be used to narrow the list of possible victims.

8-20. In general, people under 30 will have far less dental restorations than people over 30. People over 40 will be expected to have more prosthetic dental care, (crowns, dental implants, and fixed bridges). People over 60 will be more likely to have removable prostheses (full or partial denture).

8-21. In general, women will have fewer broken and decayed teeth than men. By comparison, the mandible and maxilla are smaller in women than in men.

8-22. Certain types of restorations are more likely to be found in a dental school or performed in the military than in private practice. These restorations include gold foil, cast gold inlays and onlays, full gold crowns, and amalgam restorations that are highly polished and have detailed anatomical carvings.

8-23. Dental fluorosis is much more common in individuals who live in a community with a high concentration of fluoride in their water. Certain parts of the country have higher natural concentrations of fluoride than others. (Colorado is known to have high concentrations of fluoride in the water supply.)

**POSSIBLE CONCLUSIONS**

8-24. There are four possible conclusions that the forensic odontologist may reach based on his interpretation of the observed dental characteristics of the remains.

**Positive Identification**

8-25. The antemortem and postmortem data match in sufficient detail to establish that the records are from the same individual. No irreconcilable discrepancies are present which would exclude the individual.

---

<sup>11</sup> Dr. Andrew M. Sklar.

**Possible Identification**

8-26. The antemortem and postmortem data exhibit some similar characteristics (restorative and/or anatomical). There are no entries present to exclude the individual in question. But, due to the quality of the remains and/or the antemortem evidence, it is not possible to positively establish dental identification.

**Insufficient Evidence**

8-27. The available information is insufficient to form the basis for a conclusion.

**Exclusion**

8-28. The antemortem and postmortem data are clearly inconsistent. Restorative and/or anatomical characteristics are different and unexplainable. There is no reasonable explanation for the differences. The remains are not those of the individual in question. It should be noted, however, that identification by exclusion is a valid technique in certain circumstances.

**FINGERPRINTS**

8-29. The science of fingerprinting, technically known as dactyloscopy, provides an infallible scientific means of personal identification. Fingerprinting consists of making ink recordings of the friction ridges on the palmer sides of the fingertips to be compared to known fingerprints for identification purposes. Fingerprints establish a positive and conclusive identification based on two scientific premises.

**UNIQUENESS**

8-30. No two fingerprints are alike, not even in identical twins, and not even on the hands of the same person.

**PERMANENCE**

8-31. Fingerprints develop about the third to fourth month of the gestation period (pregnancy). They do not change throughout the life of an individual (with the exception of size) barring serious injury to the papillary layer of the skin or some sort of serious skin disease or until total decomposition of the body.

8-32. Occupations requiring the handling of abrasive materials or corrosive chemicals, those which keep the hands wet continually or constantly require the handling of paper products may impair the ridges on the fingers. Temporary disfigurement may result from warts, cuts, infections, burns, and blisters; however, the ridges assume their original characteristics after healing, as long as the papillary layer of the skin is not damaged. Friction ridges can be purposely mutilated in an attempt to disguise the fingerprints to prevent recognition. The scars created by this intentional tissue damage in and of themselves are unique and serve as a means of identification.

8-33. Friction ridge detail is generated from the papillary region of the skin. The finger bulb is usually defined as the area of friction ridge skin from nail edge to nail edge and from the tip of the finger to the crease of the first joint. Figure 8-4 illustrates a cross section of friction skin showing its two basic layers—the epidermis and the dermis. The epidermis consists of friction ridges on its surface, which provides for friction allowing us to grip items. The dermis contains sweat glands which discharge a substance consisting of approximately 98.5 percent water and 1.5 percent fats and waxes and other waste materials. It is this watery substance, along with other contaminants contracted from other parts of the body, which aides in fingerprint deposition.

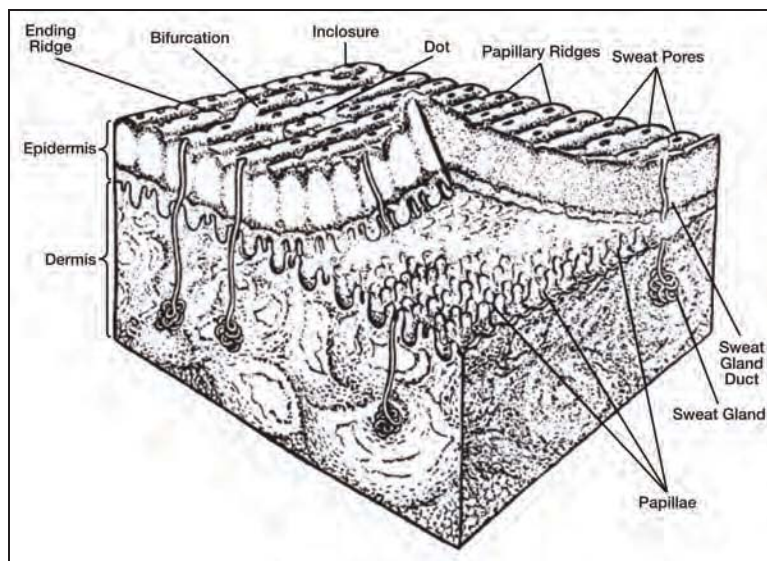
**Chapter 8**

Figure 8-4. Cross Section of Friction Ridge Skin

**CLASSIFICATION**

8-34. In 1896, Sir Edward Richard Henry introduced a comprehensive method for classifying fingerprints. Classification provides a means for filing and searching large files of fingerprint records. It is still used today in nearly all English-speaking countries. According to the modified Henry system used in the United States, all inked finger impressions are divided into three large general groups of patterns, each with subdivisions. They are arch (plain and tented); loop (radial and ulnar); and whorl (plain, central pocket loop, double loop, and accidental).

8-35. The following descriptions highlight the distinctions between the three patterns.

**Arch Pattern**

8-36. The arch pattern is the simplest of all the fingerprint patterns and the easiest to identify. Only 5 percent of all fingerprints are arch patterns.

***Plain Arch***

8-37. In the plain arch pattern (figure 8-5), the ridges enter from one side of the pattern area, rise noticeably in the center of the pattern area, drop back down, and exit the opposite side of the pattern area.



Figure 8-5. Plain Arch Pattern



**Tented Arch**

8-38. The tented arch pattern is characterized by ridges entering from one side of the pattern area, thrusting upward in the center, dropping down, and then exiting the other side. The thrust ridges appear as though they are arranged around a spine or axis. Tented arch patterns are divided into three distinct types.

- The type in which ridges at the center form a definite angle of 90 degrees or less (figure 8-6).
- The type in which one or more ridges at the center form an upthrust (figure 8-7). An upthrust is an ending ridge of any length rising at a sufficient degree from the horizontal plane, that is, 45 degrees or more.
- The type which resembles the loop pattern, and has two of the basic or essential characteristics of the loop but lacks the third (figure 8-8).



Figure 8-6. Tented Arch Patterns, Type With an Angle



Figure 8-7. Tented Arch Patterns, Type With an Upthrust



Figure 8-8. Tented Arch Patterns, Type Resembling the Loop

**Loop Pattern**

8-39. The loop pattern (figure 8-9) is the most prevalent of all; about 65 percent of all fingerprints are loop patterns. In the loop pattern, one or more of the ridges enter from either side of the pattern area, re-curve, and exit or tend to exit the same side of the pattern area which it entered. The two subdivisions of the loop pattern are ulnar and radial loops. The terms are derived from the radius and ulna bones of the forearm. A loop that flows in the direction of the ulnar bone (toward the little finger) in anatomical position is called an ulnar loop. A loop, which flows in the direction of the radius bone in anatomical position, is called a radial loop. The direction of the loop is judged by the way it flows on the hand.



Figure 8-9. Loop Pattern

**Chapter 8****Whorl Pattern**

8-40. About 30 percent of all fingerprints are the whorl pattern. In the whorl pattern the ridges are making circles. The circuit may be spiral, oval, circular, or any variant of a circle. Variations of the plain whorl pattern (figure 8-10) include the central pocket loop whorl pattern (figure 8-11), the double loop whorl pattern (figure 8-12), and the accidental whorl pattern (figure 8-13).



Figure 8-10. Plain Whorl



Figure 8-11. Central Pocket Loop Whorl



Figure 8-12. Double Loop Whorl



Figure 8-13. Accidental Whorl

**FINGERPRINTING PROCEDURES****GENERAL**

8-41. Necrodactylography, the scientific study of identifying remains through fingerprints, includes the restoration of the fingers of remains by using physical or chemical techniques to obtain identifiable fingerprints. Fingerprints taken soon after death provide the best results. If they cannot be taken within a reasonable time after death or before the remains arrive at the final processing point, each finger should be injected with embalming fluid to retard decomposition so that impressions may be taken later. Fingerprints of all digits of each hand must be taken regardless of other identifying media, including any previously recorded fingerprints.

**POWDER AND LABEL METHOD**

8-42. The USACIL Latent Print Division recommends the powder and label method taught by New Scotland Yard, Metropolitan Police Department, London, England. This is one of the simplest methods for obtaining postmortem record fingerprints. The background of the white labels and the contrasting fingerprint powder in this method creates extremely good quality record postmortem fingerprints.

8-43. Required materials are black fingerprint powder, fingerprint brush, white administrative case file labels (cut to 1½ inches x 1½ inches), blank transparencies or document protectors, and a marker pen. The method is as follows:

- Step 1. To begin, premake transparencies of a fingerprint chart and have them on hand. (Simply run the transparencies through a copier machine or use document protectors if a copy machine is not available.)
- Step 2. Brush fingerprint powder onto the bulb of the finger of the right thumb of the deceased. (Starting with the right hand and maintaining the order of thumb, index, middle, ring, and little finger for both hands will help to stay organized and avoid mistakes.) Powder the entire finger bulb from tip just below the crease of the first joint and from nail edge to nail edge.
- Place a precut label over the powdered finger and gently smooth out the label, molding it to the finger.
- Step 4. Gently and steadily peel the label from the finger and attach it to the backside of the transparency. This will allow the fingerprint to be viewed from the front side of the form and in its proper perspective. If using blank transparencies, immediately label the print on the front of the transparency, just below the labels—right thumb, right index finger, and so forth.

*Note.* The powder and label method is a much quicker and easier method for fingerprinting the deceased. Some of the other methods, however, may still have to be employed in cases wherein fingers are too damaged to allow for powdering of the skin.

## FINGERPRINT IDENTIFICATION KIT

8-44. The Fingerprint Identification Kit (figure 8 -14), or a similar kit, is used, and the prints are recorded on a fingerprint chart when fingerprinting deceased persons. The fingerprint kit contains a carrying case, black printer's ink, a spoon- or shovel-type cardholder, a tabletop cardholder, an inking slab or plate, and an inking roller. Also included is a dental examining mirror used to examine teeth for charting.




Figure 8-14. Fingerprint Identification Kit

## FINGERPRINTING THE NEWLY DEAD

8-45. When the fingers are flexible, it is often possible to obtain record fingerprints of a newly deceased person by using the regular fingerprinting process. Successful prints can be obtained with the decedent lying on his or her back with hands turned palm down by his or her sides. Procedures to be used are as follows:

- Check the decedent's hands to make sure they are clean and free of contaminants and to make note of scars and other marks.
- Check the fingerprinting equipment to make sure that it is serviceable and clean.
- Prepare a fingerprint chart. Fold and place fingerprint chart in the tabletop cardholder (figure 8-15a) as described in steps 1 and 2.
  - Step 1. Fold the fingerprint chart horizontally below the heading block and above the FBI block. All that should be showing are the print panels and the information block in the center (figure 8-15b).
  - Step 2. Lift the bar on the cardholder and slide the folded form forward under the bar until blocks 1 through 5 are positioned at the front of the cardholder (figure 8-15c). Press down on the bar until the form is secured in the holder. After the fingerprints have been made in blocks 1 through 5, remove the folded form and reverse the position of the card so that fingerprints can be recorded in blocks 6 through 10. Note that in the cardholder, the order of the blocks from left to right is 10 through 6.
- Prepare inking plate as follows:

**Chapter 8**

---

- Apply a dab of ink to the inking plate and spread thoroughly with the roller until a thin, even layer covers the entire surface.

---

*Note:* Never fingerprint or clean the fingers of a human remains unless under the direct supervision of the AFMES pathologist.

*Note.* If there is too much ink on the plate, the prints will likely be smudged or blurred. Use the roller to remove excess ink by rolling it off onto clean bond paper to prevent over inking of records.

*Note.* If there is too little ink or the ink is irregularly distributed, light spots will appear on the prints and areas will be missing. Under inking can cause prints to lack sufficient contrast for effective comparison.

---

8-46. Apply ink to the fingers (figure 8-16a), one at a time, from the inking plate or pad. Grasp the hand firmly and extend only one finger at a time. The hand is rotated so that the side of the finger can be placed on the ink plate or pad. While one hand is grasping the hand of the subject, the other hand is holding the end of the finger being printed to keep it from slipping and to apply light pressure. The finger is then rotated on the ink plate or pad until the other side of the finger is on the plate/pad. It is recommended that the direction of the roll of the digit be toward the body for the thumbs and away from the body for the fingers. Make sure the bulb of the finger is inked evenly from the tip to approximately  $\frac{1}{8}$  inch below the first joint. Press the finger lightly on the card and roll in exactly the same manner in which it was inked (figure 8-16b).

8-47. If it is difficult to get fingerprints by the tabletop cardholder method described above, then the 10 squares numbered for rolled fingerprints may be cut from a fingerprint chart for easier use. After the finger is inked, the square is rolled around the finger without letting it slip. Extreme caution should be exercised to be sure that each square bears the correct fingerprint. After all fingers are recorded, the 10 squares bearing the impressions are pasted or stapled to the fingerprint chart in their proper positions. In some cases, a broad-bladed putty knife or a spatula may be used as an inking instrument. The ink is rolled evenly and thinly on the tool and applied to the finger by passing the tool around it. The tool replaces the inking slab or plate, which may be extremely difficult or awkward to use when printing a deceased person.

**RECORD OF IDENTIFICATION PROCESSING**  
FUNCTIONAL LIMIT

LEFT HAND      RIGHT HAND

**IMPORTANT**  
 ATTENTION: FORM 2A, (Available on Card) TO THIS FORM IS AVAILABLE

DATE: \_\_\_\_\_

DATE OF BURIAL: \_\_\_\_\_ CONTAINER NUMBER: \_\_\_\_\_ IDENTIFICATION RECORD NUMBER: \_\_\_\_\_

PLAT: \_\_\_\_\_ BOX: \_\_\_\_\_ TUNNEL: \_\_\_\_\_

DD FORM 894 1 FEB 56

Figure 8-15a. Folding and Placing DD Form 894 in Tabletop Cardholder

## Chapter 8




Figure 8-15b. Information Block



Figure 8-15c. Positioning in Cardholder

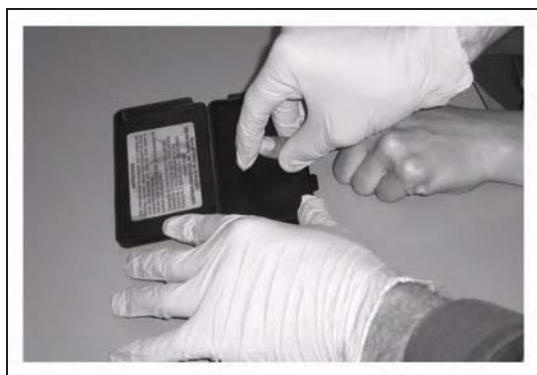

Figure 8-16a. Inking Finger




Figure 8-16b. Printing Rolled Impression

8-48. At time a spoon- or shovel-type cardholder is used to make fingerprints (figure 8-17). The operator places in the cardholder a folded fingerprint chart or an individual square cut from the form. Use of the shovel eliminates having to roll the deceased's finger. The hollow in the cardholder and the gentle pressure applied to the inked finger when brought in contact with the square results in rolled fingerprint without actually rolling the finger. The fingerprint chart is folded and placed in the shovel-type cardholder, as shown in figure 8-17 and figures 8-18a through -18c, and described in the steps below.

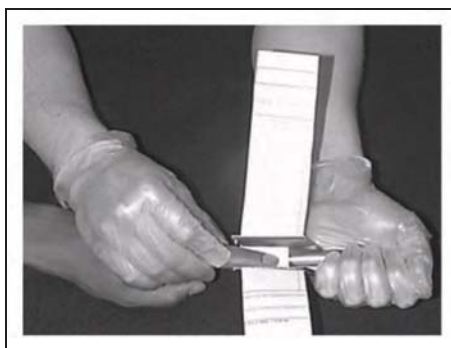


Figure 8-17. Using the Shovel-type Cardholder

- Step 1. Fold fingerprint chart lengthwise in the center (figure 8-18).

**Primary Identification of Remains**

- Step 2. Fold the print panels back so that the fingerprint chart is shaped like the letter M (figure 8-19).
- Step 3. Flatten the form (figure 8-19) so that only the print panels show.
- Step 4. Slide the form into the slots on the shovel and adjust the form so that the finger block to be used is positioned in the hollow of the shovel with the printing at the top of the print panels toward the operator as he holds the handle of the cardholder (figure 8-20).

Figure 8-18. Folding and Placing DD Form 894 in Shovel-type Cardholder, Step 1



Figure 8-19. Folding and Placing DD Form 894 in Shovel-type Cardholder, Steps 2 and 3




Figure 8-20. Folding and Placing DD Form 894 in Shovel-type Cardholder, Step 4

**Chapter 8****FINGERPRINTING REMAINS**

8-49. It may be necessary to fingerprint remains with clenched hands, wrinkled fingertips, or decomposition. Any combination of these conditions may also be present.

**Clenched Hands**

8-50. When rigor mortis has set in and the fingers are tightly clenched, the fingers may be forcibly straightened by “breaking the rigor.” The operator firmly holds the hand of the deceased, grasps the stiffened finger to be straightened, places his thumb to serve as a lever on the knuckle of the stiffened finger, and forces it straight.

---

*Note.* Rigor should only be broken when directed by the medical examiner. Breaking rigor has the potential to introduce postmortem damage that, if not documented, may be misinterpreted as perimortem damage.

---

**Wrinkled Fingertips**

8-51. The presence of wrinkles can hamper recording fingerprints. This condition is mostly caused by maceration (long immersion of the fingers in water). It can be corrected by injecting a tissue builder (glycerin) or even water into the finger bulb with a hypodermic syringe. The needle is inserted just below the crease of the first joint of the finger and up into the finger bulb area (figure 8-21). Care must be taken to keep the needle below the skin surface. The fluid is injected until the finger bulb is rounded out. The finger is then inked and printed as in a normal situation. Occasionally, the fluid may not completely fill the finger bulb and in such cases, injections can be made at the extreme tip or sides of the finger until suitable results are obtained. The tissue builder hardens shortly after injection, whereas glycerin and water can seep out when pressure is applied to the finger bulb during printing. Seepage can be prevented by tying a piece of string around the finger just above the injection point.

---

*Note.* When tissue builder is used, care should be exercised to clean the syringe and needle thoroughly because the tissue builder will harden in the instruments.

---

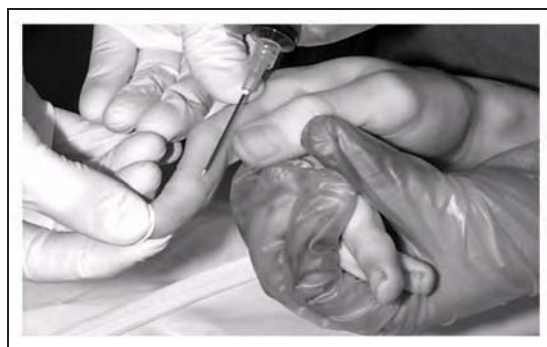

Figure 8-21. Injecting Finger With Tissue Builder

**Early Decomposition**

8-52. Decomposition in its early stages causes the outer layer of skin to peel from the fingers. If the skin is still in one piece, prints should be made as though the skin were attached to the finger. It may be better, however, in some cases to peel the skin off the finger in one piece, place it over the gloved finger of the operator, and ink and print it as though it were his own finger. If the first layer of skin is missing, a print of the second layer should be made, using the same techniques described above. Since the ridge detail on the second layer is not as distinct, more attention and care is needed to get good fingerprints.



## ADVANCED DECOMPOSITION

8-53. Fingerprinting badly decomposed remains presents difficulties not encountered in fingerprinting remains where the flesh is fairly firm and the ridge detail intact. The technique for treating fingers in various stages of decay depends upon the condition of the fingers. When remains are badly decomposed, the hands should be examined to determine if all the fingers are present. If some are missing, it should be determined whether they were amputated during the person's lifetime, amputated postmortem, or whether they were destroyed by animal, marine life, or combat. The results of the examination should be noted on the fingerprint chart. Dirt, silt, grease, and other foreign matter on the fingers should be removed during this initial examination. Soap and water or xylene can be used as a cleaning agent. Xylene readily cleans grease and fatty matter from the fingers. A soft-bristled brush may be used on fairly firm skin. A cotton swab should be used on less firm skin.

8-54. After the fingers are cleaned, a further examination is made to determine their condition. There are three general types of conditions: decomposition or putrefaction, prevalent in bodies found in brush or buried in earth; desiccation or mummification (dried out) noted in bodies found in the open or bodies subjected to severe heat or burning; and maceration (water soaking), resulting ordinarily from bodies being immersed in water. The degree of decomposition, desiccation, or maceration can vary from an early to an advanced stage. Each remains must be considered individually. The technique used to fingerprint one badly desiccated remains may not be the right technique for another. The techniques described here have been used successfully.

8-55. When a body is found, the hands may be clenched. The first problem is to straighten the fingers to determine if there is any ridge detail. If desiccation of the hands precludes straightening of the fingers, the difficulty can be overcome by using a scalpel to make a cut at the second joint on the inner side of each of the four fingers (figure 8-22). The fingers can then be straightened by applying force. The thumb, if it is bent, can generally be straightened by making a deep cut between the thumb and the index finger.



Figure 8-22. Making Deep Cut at Second Joint to Straighten Finger

### Advanced Decomposition

8-56. When the remains are in an advanced state of decomposition, the flesh is typically soft or flabby and very fragile. Procedures vary according to whether the outer skin is present and intact or whether better prints can be obtained from the underside of the skin or from the second layer of skin. At times, photographing the skin may give better results than fingerprinting.

#### *Fingerprinting Outer Skin*

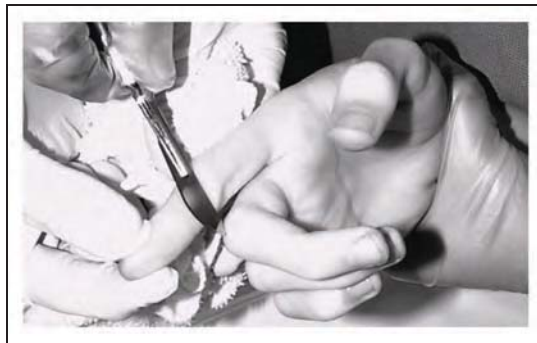8-57. When the outer skin is present and intact and the ridge detail is evident, the standard method of inking and printing may be possible. However, the skin may be too soft and fragile to ink and roll in the usual way. When this occurs, either the skin is removed from the finger or the finger is cut off at the second joint. The finger or the skin, whichever is used, is hardened in a 10 to 15 percent solution of formaldehyde for approximately 1 hour. Skin placed in this solution usually turns a grayish white and becomes firm and pliable. The skin may become brittle, however, and split if not handled carefully. The

**Chapter 8**

skin is kept in the solution until it hardens sufficiently for handling. When it is removed from the solution, it is carefully wiped dry with a piece of cloth. Then the skin, placed over the gloved thumb or index finger of the operator and held in place by his other hand, is inked and rolled as though he were printing his own finger.

8-58. While the finger is soaking in the formaldehyde, the skin may swell and come loose from the finger. Should this occur, the skin must be removed carefully and the procedure outlined above must be followed. If, however, the skin still adheres to the finger and is not too wrinkled, ink may be applied and prints made. Should the skin be intact but too wrinkled to obtain a satisfactory impression, tissue builder can be injected under the skin to fill out the pattern area. The finger is then inked and printed as usual.

8-59. When part of the skin has been destroyed to the extent that tissue builder cannot be injected effectively and the pattern area is present but wrinkled, the entire pattern area should be removed by cutting off the first joint of the finger (figure 8-23). Care must be exercised to ensure that the complete fingerprint pattern is removed, with the cut made deep enough to allow the skin to be removed without causing damage to the area of interest. Carefully remove any excess flesh from the underside of the removed skin by scraping, cutting, and trimming until only the outer layer of skin remains, or until the specimen is so thin that it can be flattened out to remove most of the wrinkles. If the skin is fairly pliable, the operator should attempt to place it over one of his own fingers and try to record several prints. If the prints obtained are not suitable, the piece of skin should be flattened out between two pieces of glass and photographed. If a satisfactory print is not obtained, the underside of the skin should then be examined.



**Figure 8-23. Removing Pattern Area From First Joint**

### ***Fingerprinting Underside of Skin***

8-60. In many instances when the ridge detail on the outer surface has been destroyed or cannot be seen, the ridge detail is clearly visible on the underside. If so, the skin is carefully turned inside out to prevent splitting or breaking and is then inked and printed in the usual manner. It must be remembered, however, that when the underside of the skin is printed, the impression is in reverse position; that is, the ink is actually adhering to what would be the furrows of the pattern. If it is thought that turning the skin inside out will damage it, a photograph of the inner ridge detail is made and the negative is printed in reverse for comparison purposes. A good photograph of the ridge detail might be obtained by trimming the skin and flattening it between two pieces of glass.

### ***Fingerprinting Lower or Dermal Layer of Skin***

8-61. The dermal layer of skin has the same ridge detail, though finer and less pronounced, as the outer layer. The lower layer is just as effective for identification purposes. These facts are particularly helpful to know when decomposition has destroyed the outer layer of skin, or it is in such a condition as to be of no value. If the outer layer of skin is missing and the second layer is intact, the finger should be cleansed, dried, inked, and printed in the usual manner. If some of the outer skin remains attached, carefully pick and pry it off with a scalpel being careful not to destroy or damage the lower layers. The second or dermal layer of skin is composed of what are called dermal papillae, which have the appearance of minute blunt pegs or nipples. The dermal papillae are arranged in double rows. Each double row lies deep in a ridge of the

surface or epidermal layer and presents the same variations of ridge characteristics as are on the outer layer of skin except that they are double. Accordingly, when the second layer of skin is printed or photographed, the ridge detail will appear in double. This can confuse the examiner in that what may be a loop having 10 ridge counts may appear to be a loop with 20 ridge counts.

### **Desiccation**

8-62. The main problem in treating desiccated or dried and shriveled fingers is how to stretch out and soften the skin. The desiccated skin is usually intact and the ridge detail fairly clear. However, numerous wrinkles are present and as the drying process continues, the skin and flesh harden until the fingers become almost as hard as stone. The skin can be stretched and softened by soaking it in a hydroxide solution. If the results are unsuccessful, the pattern area can be removed and printed or photographed. Satisfactory prints can also be obtained by using silicone casting materials or liquid latex.

### ***Soaking in Hydroxide***

8-63. Soaking the fingers in a 1 to 3 percent solution of sodium hydroxide or potassium hydroxide (caustic potash), will swell the flesh. It is best to try one finger at a time because even as the flesh is absorbing the solution and is swelling, it is being destroyed by the hydroxide. The finger to be soaked in the hydroxide is cut from the hand at the second joint. When it reaches its normal size by absorbing the hydroxide, it is inked and printed. There is no set time for this process. It may take from a few hours to as much as 10 days. A close watch is maintained—beginning 30 minutes after the finger is put in to soak. If the skin peels, the loose skin is scraped off and the finger is rinsed in water and returned to the solution. If the finger has not reached full size after several hours, it is placed in water for an hour or so to hasten the swelling.

8-64. When removed from the water, the finger is coated with a film. Then it is scraped and replaced in the hydroxide for an hour or so more. If the flesh becomes too soft, the finger is placed in a 1 to 3 percent solution of formaldehyde or alcohol for several minutes to harden. This process of alternating from the sodium hydroxide solution to water, scraping, and replacing in solution is continued until the desired result is obtained. Subsequently the finger can be inked and printed. However, if the finger becomes over saturated and will not print properly, it should be dipped in acetone for a few seconds, removed, and permitted to dry after which it is inked and printed. If satisfactory results are obtained with one finger, the rest of the fingers are given the same treatment.

### ***Removing the Pattern Area***

8-65. If the reaction of the hydroxide solution on the first finger treated is not satisfactory, and it is doubtful that further soaking would give satisfactory results, the treatment is discontinued. The finger is removed from the solution, washed carefully in water, and placed in formaldehyde to harden sufficiently for handling without damaging the ridges. Then the pattern area is cut off in such a way that sufficient surrounding surface permits the skin to be trimmed. Carefully scrape and cut to remove the excess flesh. During the cutting and scraping process, the skin is soaked in xylene from time to time and massaged to soften it and to remove wrinkles. When the skin is thin enough and sufficiently pliable, the operator places the skin on his or her own gloved finger, inks, and prints it. If the results are satisfactory, the same procedure is followed with the remaining fingers. If the prints are not suitable, the skin is scraped until it can be flattened between two pieces of glass and photographed. If there is poor contrast between the ridges and the furrows when direct light is used, transmitted light should be used instead.

### ***Using Modeling Clay***

8-66. Modeling clay can be used to make satisfactory impressions of macerated, desiccated, and charred fingers according to the following steps:

- Step 1. Shape one end of a stick of ordinary modeling clay to resemble the head of a small mushroom. It should be large enough to cover the pattern area of the bulb of the finger.
- Step 2. Apply the mushroomed end of the clay to the inking plate.

**Chapter 8**

---

- Step 3. Firmly press the inked clay against the pattern area several times to ensure an even inking of the finger bulb.
- Step 4. Press a ¼-inch layer of modeling clay into the concave section of the shovel-type cardholder. Then cover the clay with a thin piece of plastic or paper on which to record the print.
- Step 5. Press the inked finger against the paper or plastic, which adapts itself to the contours of the finger as the clay base yields. Rolling the finger is unnecessary. If the finger seeps an excessive amount of fluid, white plastic lifting tape may be substituted for the plastic or paper to prevent slippage and blurring.

***Using Plastic Casting Material***

8-67. Before plastic casting material is applied, the fingers must be thoroughly cleaned and dried. The plastic material is applied in small drops, which are spread out to form a thin even layer to cover the whole papillary pattern of the finger bulb. When all the fingers have been treated in this way, they should remain at room temperature for about 30 to 60 minutes or until the casting material has dried. The casts are then carefully removed and each cast is placed between glass slides along with the number of the finger.

8-68. Liquid latex may be used to make a cast according to the following steps:

- Step 1. Dip each finger into the latex and let it dry. Repeat this step several times until a cast approximately 1/32-inch thick is built-up to prevent its tearing.
- Step 2. When the last coat is dry and the cast changes to flesh color, remove it by rolling it from the finger.
- Step 3. Roll the cast onto the operator's finger, ink, and record it on the fingerprint chart. Note that the flow and color of the ridges in latex impressions are the reverse of prints made by the fingers themselves.

8-69. Bodies which have been burned or subjected to severe heat are included in the desiccation cases, but the techniques for fingerprinting them differ from other desiccated cases. Often there are instances when the skin has become loose but is hard and crisp, or when the finger has been severely burned and is reduced almost to carbon, yet is firm. In such cases, the ridge detail usually has not been destroyed.

8-70. When a severely burned body is located, the problems of identification should be anticipated. Before the body is removed, the fingers should be carefully examined to determine if transporting the remains would in any way cause damage to the fingers or ridge detail. If damage could be incurred, consideration should be given to securing fingerprints at the scene.

8-71. An examination of the fingers may show that the outer skin is hardened and is partially loosened from the flesh. It is sometimes possible to remove this outer skin intact by twisting it back and forth. If this is done, the operator may place the skin on his own gloved finger, ink it, and print it in the usual manner. If the skin is intact and is un wrinkled, recordings are made in the usual manner.

8-72. Should wrinkles be present and the skin pliable, tissue builder is injected into the bulbs, which are inked and printed. If the wrinkles cannot be removed, then the pattern area is cut off and the procedure given on page 8-14 is followed.

8-73. In some instances, the fingers of burned bodies are charred. Such cases require careful handling as the ridge detail can be destroyed or disturbed through mishandling. In these cases, the procedure is determined by the degree of charring. In extreme cases, the only method of recording is by photography using side lighting to obtain the proper contrast of ridges and depressions. Obviously, no attempt should be made to ink and roll the prints, as the pressure necessary to secure the prints would cause the skin to crumble. When extreme charring has not occurred, the procedures previously given for treating the skin by cleaning, softening, inking, and printing or photographing should be followed.

**Maceration**

8-74. Maceration, or the long immersion of the fingers in water, presents a problem in obtaining legible impressions. One important rule in making legible prints is that the fingers must be dry. In addition to

drying the fingers, other difficulties must be overcome. When the skin on the fingers absorbs water it swells, and loosens from the flesh within a few hours after immersion. If the skin is water soaked, wrinkled, and pliable, but intact, the skin is carefully cleaned as described earlier. Then the fingertip is wiped with alcohol, benzene, or acetone and given a few seconds to dry. After the skin is dry, it is pulled or drawn tight across the pattern area so that a large wrinkle forms on the back of the finger. The bulb is then inked and printed.

8-75. If the skin is broken and hanging loose but the pattern area is intact, the skin is removed from the finger and cleaned by placing it in alcohol or benzene (not acetone) for about a minute. Then it is stretched carefully over the operator's gloved finger to remove any wrinkles before it is printed.

8-76. Sometimes the skin is intact on a finger, but it is so wrinkled and hard that it is not possible to draw it tight for inking. If so, tissue builder may be injected to round out the bulb for inking and printing. Should this procedure fail, the ridge detail is photographed on the finger or the skin is cut off and flattened between two pieces of glass and photographed.

8-77. When the ridge detail does not show on the surface of the outer skin, the underside should be examined to determine if the detail could be seen more clearly. If so, the underside of the skin is photographed.

8-78. When the outer skin is gone and the finger is not saturated with water, it is possible to dry the surface sufficiently for inking and printing by rolling the finger on a blotter. If this fails, the finger is wiped off with a piece of cloth saturated with alcohol, benzene, or acetone and then inked and printed.

8-79. When the outer skin is gone and the fingers are saturated with water, they must be dried out quickly by placing them in full strength acetone for approximately 30 minutes. The fingers are then placed in xylene for about an hour or until the xylene has overcome the reaction of the acetone. After the fingers are removed from the xylene, they are placed on a blotter to dry. When finger surfaces appear to be dry, they are ready to be inked and printed. When the fingers are removed from the acetone, they dry and harden in a matter of seconds. Xylene can be used to resoften the fingers.

### **Photographic Print Impressions**

8-80. When a comparison of fine structured detail is needed, prints may be made with a photographic developer—using glossy photographic print paper. The developer is applied lightly to the fingertip and rolled lightly on the paper. Then it is placed in an acid-fixing bath for approximately 30 minutes and washed in the same way as the ordinary photograph. This process yields a highly detailed print.

## **FOOTPRINTING**

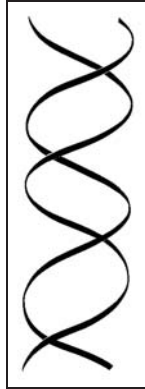
8-81. Footprints are obtained in the same manner as fingerprints. Briefly, use an ink roller to coat the bottom of the foot. Secure a footprint chart to something flat and stable, like a clipboard. Take a straight-on, flat impression of the left and right foot. Alternately, secure a footprint chart to a cylinder and roll the entire foot, heel to toes. The feet must be clean and dry.

## **DEOXYRIBONUCLEIC ACID (DNA)**

8-82. DNA is a double-stranded molecule that is hydrogen-bonded together and twisted to form a double helix (figure 8-24). It resembles a long, twisted ladder or zipper. DNA is often described as the body's blueprints as these molecules carry the genetic codes that govern individual traits and the structure and function of every component of the body. For example, DNA is the material that governs inheritance of eye color, hair color, skin color, and stature.

**Chapter 8**

---



**Figure 8-24. The Double Helix**

8-83. Each individual's DNA is different from that of every other individual in the world, except for identical twins. Like fingerprints each person has a unique DNA fingerprint. The DNA fingerprint is the same for every cell, tissue, and organ that makes up an individual's body.

8-84. DNA must be recovered from the cells or tissues of the body. Only a small amount of biological evidence—such as blood, skin, hair, or semen—is needed.

**DNA USES**

8-85. Forensic science uses techniques developed in DNA research to identify individuals who have committed a crime and to identify unknown individuals. DNA is also used in paternity cases. DNA is particularly useful in the identification process when the remains have been damaged by fire, severely fragmented, commingled in a mass disaster, or decomposed. The U.S. Armed Forces collects DNA bloodstain cards from all military personnel. Department of Defense Directive 5154.24, Subject: Armed Forces Institute of Pathology (AFIP), requires all active component personnel in the U.S. military to submit a reference DNA sample (blood). The sample is retained by the Armed Forces Institute of Pathology in the event that a comparison to a specific individual is needed in the future.

**DNA PROFILING**

8-86. DNA fingerprinting, more appropriately called DNA profiling, makes it possible to compare samples of DNA from various sources (such as comparison of a sample from a BTB remains to a sample obtained antemortem) in a manner comparable to the comparison of fingerprints. Very basically, the DNA in a sample is isolated and then specific sections of DNA are targeted for analysis using a technique called PCR. This is like a biochemical "Xerox" of the target section of DNA and millions of copies can be made. Those target sections are then analyzed on the basis of their unique sizes or sometimes unique sequence (letter-by-letter code). The more sections of DNA that are analyzed, the more of a distinctive DNA profile can be established.

8-87. There are two types of DNA that are used in DNA profiling.

**Nuclear DNA**

8-88. The preferred method in the forensic community is based on nuclear DNA. There are only two copies of nuclear DNA per human cell. Half an individual's nuclear DNA comes from the biological mother and the other half comes from the biological father. Thus, a child is a biological "copy" of the mother and father because of the inherited nuclear DNA. To obtain an identification, the DNA profile from the unidentified individual is compared to the profile from a sample known to have come from the individual BTB deceased or sometimes, can be reconstructed if DNA samples are taken from the parents.

8-89. Over time, as the biological sample ages, DNA breaks down. In some cases—such as skeletal or badly decomposed remains—it is not possible to extract nuclear DNA. In these cases, mtDNA is used.

While there are only two copies of nuclear DNA per cell, there are approximately 1,000 copies of mtDNA per cell. Thus in cases where nuclear DNA cannot be analyzed, mtDNA may be present in sufficient quantities for analysis.

### Mitochondrial DNA

8-90. Mitochondrial DNA is maternally inherited; it is passed from mother to child. Mitochondrial DNA is not inherited from the father. A mtDNA sample from the remains can be compared to a sample from the mother or any brothers and sisters in the same maternal line (figure 8-23). Even samples from nieces and nephews and cousins can be used as references, but only if they share the same maternal ancestry as the deceased.

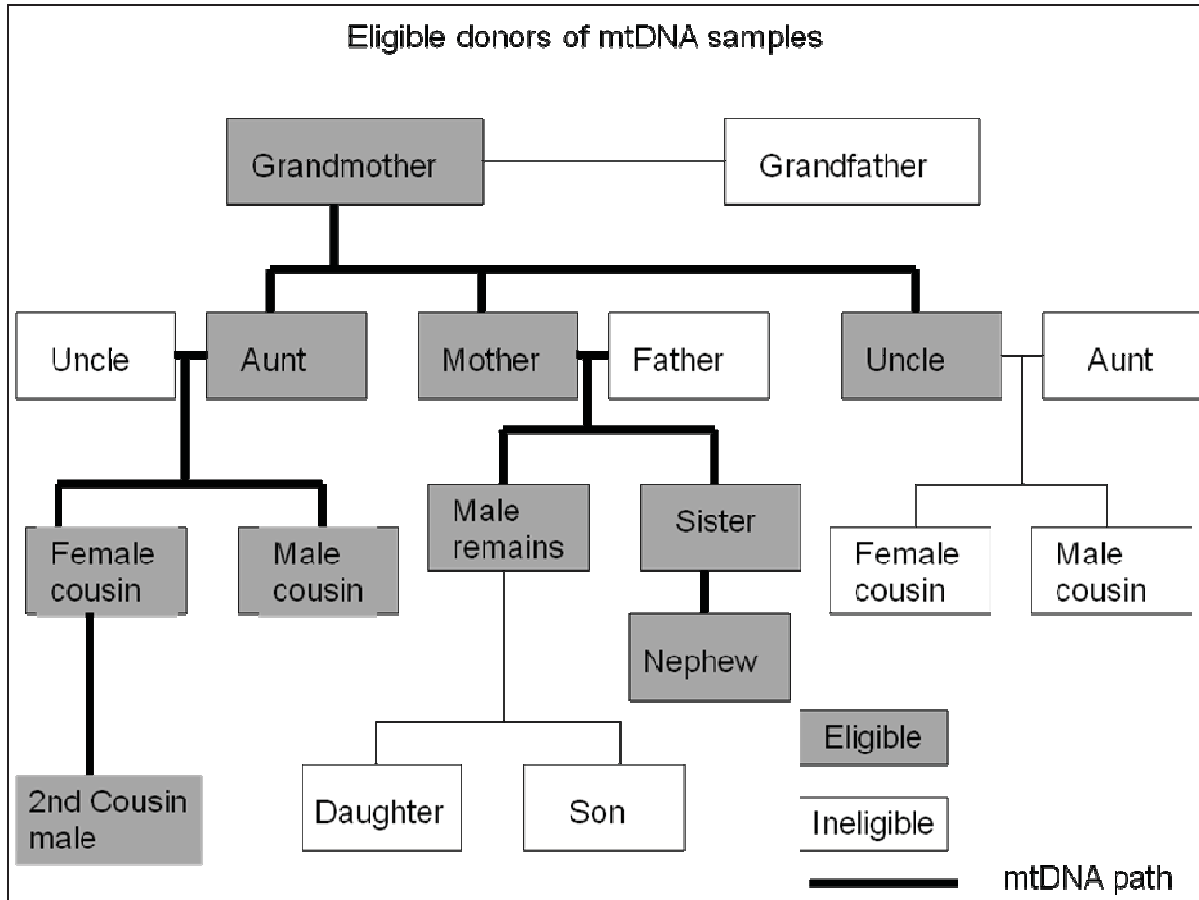


Figure 8-25. Eligible Donors of mtDNA Samples

8-91. The nature of mtDNA allows comparison of the sample from the deceased to reference samples from family members separated by generations. It is important in the identification of individuals for which there is no antemortem comparison sample. However, mtDNA is not unique to a specific individual. It cannot, therefore, be used by itself for a positive identification and must be used in corroboration with additional circumstantial information.

**This page intentionally left blank.**



## Chapter 9

# EXAMINATION OF SKELETAL REMAINS

### OBJECTIVE

9-1. To provide the mortuary affairs Soldier with a basic knowledge of forensic anthropology to assist forensic experts with processing skeletonized human remains.

### FORENSIC ANTHROPOLOGY

9-2. The American Board of Forensic Anthropology defines forensic anthropology as the application of the science of physical anthropology to the legal process. Forensic anthropologists apply standard scientific techniques to identify human remains and assist in detecting crime. Forensic anthropologists are typically called upon when conventional means of identification—such as visual identification, dental identification, or fingerprints—fail to make a positive identification.

9-3. The basis of all forensic anthropological analysis is human osteology (the science of the anatomy and structure of bones). Forensic anthropologists assist medical and legal specialists in the identification of human remains. They reconstruct the biological profile of the living individual from the skeleton, estimate the time since death, and determine the cause of death (gunshot wound to the head, stab wound, and so forth).

9-4. Unlike the forensic pathologist, who examines fleshed remains, the forensic anthropologist examines skeletal, semiskeletal, fragmented, badly decomposed, burned, mummified, or otherwise unidentifiable human remains. The objectives of a forensic anthropological examination are the same as those of a medicolegal examination of a recently deceased individual. However, the skeletonized nature of the remains dictates that the forensic anthropologist addresses different questions than those posed in a typical medicolegal autopsy. The forensic anthropologist focuses on—

- Are the remains human?
- Do the remains represent a single individual?
- What is the age, sex, race, and stature of the individual represented by the remains (biological profile)?
- How long has the individual been dead?
- Are there any skeletal traits or anomalies that are specific to the individual that could aid in a positive identification?

9-5. In some circumstances, such as partially decomposed remains or mass disasters, the forensic anthropologist, forensic pathologist, and forensic odontologist will work together to retrieve the maximum amount of information possible from the remains.

9-6. Forensic anthropologists are frequently instrumental in the investigation and management of death scenes. They apply modified standardized archeological techniques to legal investigations—such as a buried body or a mass grave—to assist in recovering victims. Forensic anthropologists may also reconstruct remains to identify trauma to the body such as a skull severely fragmented by a gunshot wound.

## BASIC LABORATORY TECHNIQUES

9-7. This model protocol may be used in a variety of situations. Variation in protocol is inevitable or may even be preferable in some circumstances. Instructions for many of these protocols are in sections that follow.

9-8. Radiograph skeletal elements before conducting any analysis. Radiographs will detect conditions not visible to the naked eye, such as healed fractures or the presence of gunshot residue.

9-9. If possible, have a specialist (X-ray technician) obtain bitewing, apical, and/or panoramic dental X-rays.

9-10. If possible, have a specialist (X-ray technician) X-ray the entire skeleton. Any observed or potential fractures, developmental anomalies, surgical procedures, or individualizing characteristics should be X-rayed separately. Frontal sinus (page 9-16) films should be included for identification purposes.

9-11. Prior to analysis, “lay out” the skeletal remains on a table in standard anatomical position to conduct an inventory. Do not clean the bones.

9-12. Inventory skeletal elements and record on a skeletal form/chart. Record the condition of the remains (refer to chapter 4).

9-13. Conduct a preliminary identification of the remains. Determine age, sex, race and stature. Record the reasons for each conclusion. Photograph all evidence supporting each conclusion. (Refer to following sections.)

9-14. Examine remains for individualizing characteristics. (Refer to section 9-8.) Record the conditions observed and the reasons for each conclusion. Photograph all evidence supporting each conclusion.

9-15. Examine the remains for evidence of antemortem and perimortem injuries and postmortem alterations. If possible, assign each area of trauma to one of these three categories. (Refer to chapter 3.) Record the reasons for each conclusion. Photograph all evidence supporting each conclusion.

9-16. Photograph the entire skeleton in one frame. Photograph any observed or potential fractures, developmental anomalies, individualizing characteristics, and prior surgical procedures. Photographs should contain an identification number and a scale.

## ESTIMATION OF SKELETAL AGE

9-17. Assessment of age at death, based on skeletal elements, is an essential part of developing a biological profile of the individual represented by the remains. Growth-related (developmental) age changes in the human skeleton occur until the individual reaches approximately 25 years of age. During the developmental phase of human growth, age assessment from skeletal remains is more accurate and straight forward and the assigned age range is typically narrow. After growth and development ceases, age determination becomes more difficult and the assigned age range is typically broad. After adulthood, age-related changes to the skeletal system continue in the form of degenerative changes. Thus, the estimation of age at death in skeletal remains depends on different biological changes occurring in different periods of life. Entire books have been written on age estimations from the human skeleton. The following sections on skeletal aging are not meant to be exhaustive, rather they are intended to acquaint the reader with the methods used to determine the age of an individual at death. They are meant to serve as a basic reference to allow the mortuary affairs specialist to understand how age estimations of skeletal remains are determined in the field or mortuary.

## ESTIMATION OF FETAL AGE

9-18. There are circumstances, such as abortion or circumvent or suspicious burials, when the gestational age and/or viability of a fetus can be an important legal issue. The fetal/gestational age of skeletal remains can be estimated from diaphyseal lengths of the long bones, appearance of ossification centers, and/or dental development.

9-19. During the fetal period, the stage of development is usually expressed in terms of CRL and/or CHL. CRL (measured from the top of the head to the rump) is used on fetuses up to approximately 20 weeks of age. After that CHL (measured from the top of the head to the heel) is used. These measurements are taken using sonograms of the fetus during the mother's pregnancy. Numerous studies have produced accepted correlations of CRL and CHL to fetal age. Since CRL and CHL cannot be measured in skeletal remains, regression equations have been developed for calculating age at death directly from the diaphyseal lengths of the femur, tibia, fibula, humerus, radius, and ulna. The diaphyseal lengths of fetal long bones are used as an indicator of how far along the growth/developmental continuum (of CRL and/or CHL) the fetus has progressed. The diaphyseal lengths of the long bones are measured with calipers, and the measurements are compared to the results produced by the studies on the correlation of CRL and CHL to estimate gestational age.

9-20. Centers of ossification form throughout the entire period of skeletal development. The fetal ossification centers include the skull, vertebral column, ribs, sternum, primary centers of the long bones (diaphyses), shoulder and pelvic girdles, and the hand and foot phalanges. At birth, the human skeleton consists of approximately 450 centers of bone growth but only 6 epiphyseal centers are present. These are the head of humerus; condyles of the femur (distal) and tibia (proximal); and the talus, calcaneus, and cuboid (bones of the foot). The presence of these epiphyses in the skeletal remains indicates that the fetus was viable. The epiphyses are very small, comparable to small pebbles, and do not resemble their adult form. They may not be recognized as human bone by an untrained observer.

9-21. During the fetal period, the crowns of the deciduous teeth grow and calcify within the maxillae and mandible. At approximately 4 to 5 prenatal months, the central incisors begin to form and calcify. Growth and formation of the deciduous canines and molars continue in a fairly regular sequence around the jaws. The second deciduous molar begins formation at about 6 prenatal months. These are tooth germs, small buds, which do not resemble their deciduous form.

## ESTIMATION OF IMMATURE AGE

9-22. In general, immature skeletal remains are those of individuals from birth through 20 years of age. This developmental phase of human growth is characterized skeletally by predictive sequences of dental calcification and eruption, appearance of ossification centers, length of long bone diaphyses, and epiphyseal union. Age at death of immature remains can be estimated within a narrow range by using a combination of those methods.

---

*Note.* A brief review of bone growth will help to understand the mechanics of aging immature skeletal remains. During the fetal period, the long bones are initially formed as a cartilaginous model. Between the second and third fetal month, the cartilaginous model begins to be replaced by bone (ossification). Ossification occurs first in the central part of the shaft, the primary center. Ossification continues outward until the shaft, diaphysis, is completely ossified. Before puberty, the secondary centers, the epiphyses, develop at the proximal and distal ends of the long bones. They are separated for years from the diaphysis by a zone of cartilage. The plate of cartilage allows for growth. As the diaphysis grows, it eventually unites with the epiphysis/epiphyses eliminating the cartilaginous plate (epiphyseal union).

---

## Dental Calcification and Eruption

9-23. Dental calcification and eruption are an accurate and reliable method for estimating age in young individuals. As a general rule, the dentition of females erupts ahead of the dentition of males. Typically, the mandibular teeth will erupt before the maxillary teeth (both deciduous and permanent). The general eruption sequences reported below are for male maxillary dentition.

**Chapter 9**

---

- At birth, the deciduous teeth have not erupted and root formation has not started. Within the maxillae and mandible, the crowns of the incisors are virtually complete, the canines are about half complete, the cusps of the first molars are completed and united, and the cusps of the second molars are half formed but have not yet united.
- The majority of the deciduous teeth erupt between 6 months and 1 year. The deciduous central incisors usually erupt between 6 and 12 months. The lateral incisors erupt between 9 and 16 months. The deciduous canines erupt between 16 and 23 months. The first deciduous molars usually erupt between 14 and 18 months. The second deciduous molars erupt between 23 and 31 months.
- Between the ages of 2 and 6 years, there will be a gradual resorption of the roots of the deciduous teeth. This resorption is prompted by the continued growth and calcification of the crowns and roots of the permanent teeth.
- Between the ages of 6 and 12 years, the deciduous teeth will shed and the majority of the permanent dentition will erupt. The first permanent molar erupts around the sixth year of age. The central incisors erupt between 6 and 7 years and the lateral incisors erupt between 7 and 8 years of age. The canines erupt between 9 and 10 years. The first premolars erupt between 10 and 12 years of age. The second premolars erupt between 11 and 12 years. The permanent second molar erupts around 12 years. Eruption of the third molars is variable, with eruption occurring between 17 and 21 years of age.

**Appearance of Ossification Centers**

9-24. The appearance of ossification centers occurs from birth through approximately 15 years, with ossification beginning earlier in females. Most centers of ossification appear between birth and 5 years. The ages of ossification are reported as central tendencies, as there is much variation between individuals. For example—

- At 2 months, ossification centers for some hand bones appear.
- At 3 months, the distal tibia appears.
- At 7 months, the distal radius appears.
- Between 11 and 26 months, various ossification centers for the hands and feet appear.
- At 3 years, the patella appears.
- At 4 years, the proximal radius appears.
- At 5 years, the distal ulna appears.

9-25. Some ossification centers that appear after 5 years of age include—

- The medial clavicle between 14 and 15 years.
- The proximal ulna between 8 and 10 years.
- The iliac crest between 11 and 14 years.
- The ischial tuberosity between 11 and 15 years.
- The lesser trochanter of the femur between 13 and 16 years.

**Epiphyseal Union**

9-26. Epiphyseal union of skeletal elements occurs at predictable rates. Females are, on average, 2 years in advance of males in epiphyseal union. Epiphyseal union is viewed as a process; it does not occur all at once. In fact, a range of 4 years can be seen between the onset of fusion in early-maturing individuals and completion of fusion in late-maturing individuals. Table 9-1 is provided for basic guidance only. It incorporates findings from a variety of age-related studies and age ranges were ‘crunched’ to provide a general overview. The table should be used only as a preliminary indicator of age.

Table 9-1. Estimation of Immature Remains From Epiphyseal Union

<i>Skeletal Element</i>	<i>0-2 yrs</i>	<i>1-3 yrs</i>	<i>2-4 yrs</i>	<i>3-7 yrs</i>	<i>4-6 yrs</i>	<i>5-8 yrs</i>	<i>12- 17 yrs</i>	<i>14- 18 yrs</i>	<i>15- 21 yrs</i>	<i>20- 25 yrs</i>
Mandibular symphysis	X									
Anterior and occipital fontanelles (closed)	X									
Squamous and lateral parts of the occipital bone		X								
Vertebral arches		X								
Metopic suture			X							
Dens and centra of axis				X						
Cervical, thoracic, lumbar, and sacral vertebral arches to centra				X						
Lateral and basilar parts of the occipital						X				
Atlas						X				
Ischiopubic rami						X				
Female: proximal and distal tibia and fibula; head of femur; acetabulum; medial epicondyle of humerus; proximal humerus; greater trochanter of femur; distal femur							X			
Capitulum, trochlea, and lateral condyle of humerus to each other							X			
Male: medial epicondyle of humerus; head of femur; acetabulum; distal tibia and fibula								X		
Coracoid process of scapula, proximal and distal radius and ulna								X		
Male: distal femur; proximal humerus; proximal tibia and fibula; greater trochanter of femur									X	
Heads of ribs, thoracic and lumbar epiphyseal rings to body, iliac crest									X	
Medial epiphyses of clavicle, medial border of scapula, ischial epiphysis										X

**Chapter 9****Lengths of Long Bone Diaphyses**

9-27. As in fetal remains, the lengths of long bone diaphyses are used to estimate immature age. The diaphyses of the long bones are measured and the measurements are compared to growth rate charts derived from a series of known age individuals to arrive at an age range.

**ESTIMATION OF ADULT AGE**

9-28. Estimation of adult age at death is more difficult than estimations of age at death for fetal and immature remains. Forensic anthropologists can no longer rely on the relatively regular skeletal and dental changes associated with growth and development. The techniques used in aging adults are based on observed gross morphological (and, to a lesser extent, microscopic) changes in bone. These are basically degenerative changes that are more variable and less precise than those associated with immature remains. Because age-related changes in the adult skeleton are less obvious than those of the developmental years, careful attention to bone morphology is a must. When possible, it is best to use as many skeletal age indicators as available to estimate adult age. An age estimation derived from a variety of indicators will provide a more accurate age estimation than one derived from a single indicator. The reader must be aware that age indicators vary between the sexes and populations.

**Pubic Symphysis**

9-29. The age-related changes in the pubic symphysis have been recognized for years as one of the best areas from which to determine adult age. Several researchers have conducted studies on determining adult age from morphological changes in the pubic symphysis—Todd (1920, 1921), McKern and Stewart (1957), Gilbert and McKern (1973), and several works by Suchey and coworkers. This manual advocates using the Suchey-Brooks age determination system (Katz and Suchey 1986, Brooks and Suchey 1990, and Suchey and Katz 1998) as it was developed on a large autopsy sample of modern individuals with well documented age data. This method uses a single set of descriptions that are applied to both sexes. Although there are morphological differences between the sexes, the Suchey-Brooks system focuses on key age changes that were observed in both male and female pubic bones. (See table 9-2.)

9-30. The following descriptions stress the key features distinguishing the phases in both males and females. Separate male and female models are necessary so researchers can correctly classify the pubic bones in the applicable phase. The key to recognizing each phase is in italics.

- Phase I. The symphyseal face has a billowing surface (ridges and furrows) which usually extends to include the pubic tubercle. The horizontal ridges are well marked and ventral beveling may be commencing. Although ossific nodules may occur on the upper extremity, *a key to the recognition of this phase is the lack of delimitation of either extremity (upper or lower).*
- Phase II. The symphyseal face may still show ridge development. *The face has commencing delimitation of lower and/or upper extremities occurring with or without ossific nodules.* The ventral rampart may be in beginning phases as an extension of the bony activity at either or both extremities.
- Phase III. The symphyseal face shows lower extremity and *ventral rampart in process of completion.* There can be a continuation of fusing ossific nodules forming the upper extremity and along the ventral border. Symphyseal face is smooth or can continue to show distinct ridges. Dorsal plateau is complete. Absence of lipping of symphyseal dorsal margin; no bony ligamentous outgrowths.
- Phase IV. Symphyseal face is generally fine grained although remnants of the old ridge and furrow system may still remain. *Usually the oval outline is complete at this stage, but a hiatus can occur in upper ventral rim.* Pubic tubercle is fully separated from the symphyseal face by definition of upper extremity. The symphyseal face may have a distinct rim. Ventrally, bony ligamentous outgrowths may occur on inferior portion of pubic bone adjacent to symphyseal face. If any lipping occurs, it will be slight and located on the dorsal border.

- Phase V. *Symphyseal face is completely rimmed with some slight depression of the face itself, relative to the rim.* Moderate lipping is usually found on the dorsal border with more prominent ligamentous outgrowths on the ventral border. There is little or no rim erosion. Breakdown may occur on superior ventral border.
- Phase VI. *Symphyseal face may show ongoing depression as rim erodes.* Ventral ligamentous attachments are marked. In many individuals, the pubic tubercle appears as a separate bony knob. The face may be pitted or porous, giving an appearance of disfigurement with the ongoing process of erratic ossification. Crenulations may occur. The shape of the face is often irregular at this stage.

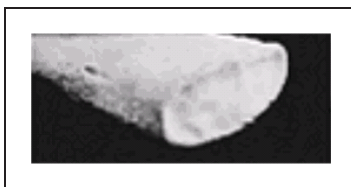
**Table 9-2. Aging Rules Related to the Suchey-Brooks Pubic Age Determination System**

	Females	Males
Phase	Age (years)	Age (years)
I	24 or under	23 or under
II	19-24	19-34
III	21-53	21-46
IV	26-70	23-57
V	25-83	27-66
VI	42-87	34-86

### Sternal Rib Ends

9-31. Age at death criteria from the sternal rib ends (where the rib end meets the costal cartilage that articulates with the sternum) are based on the progression of morphological age-related changes to the fourth rib (Iscan and Loth, 1986). If the fourth rib is not available, the third or fifth rib may be used. Essentially, the sternal end of the rib in young adults appears billowy. The walls of the margins are thick and the bone is dense. As age increases, the surface begins to degrade and becomes hollowed out with a cup-like shape. There is a tendency for the costal cartilage to ossify and for the bone to get thinner. This technique is sex and population specific, and there are differences between the male and female and black and white standards. The descriptions here have been modified for unisex and unirace age determination. They are, therefore, for use as a preliminary, general identification tool only.

9-32. Phase 0 (16 years and younger). The articular surface is flat or billowy with a regular rim and rounded edges. The bone is smooth, firm, and very solid (figure 9-1).

**Figure 9-1. Phase 0****Figure 9-2. Phase 1**


9-33. Phase 1 (17–19 years). There is a beginning of an amorphous indentation in the articular surface, but billowing may also still be present. The rim is rounded and regular. In some cases, scallops may start to appear at the edges. The bone is still firm, smooth, and solid (figure 9-2).

**Chapter 9**


9-34. Phase 2 (20–23 years). The pit is now deeper and has assumed a V-shaped appearance formed by the anterior and posterior walls. The walls are thick and smooth with a scalloped or slightly wavy rim with rounded edges. The bone is firm and solid.

9-35. Phase 3 (24–28 years). The deepening pit has taken on a narrow to moderate U-shape. Walls are still fairly thick with rounded edges. Some scalloping may still be present, but the rim is becoming more irregular. The bone is still quite firm and solid.

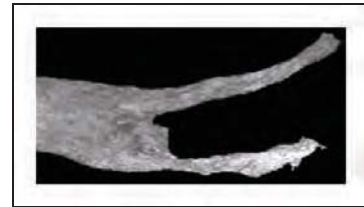
9-36. Phase 4 (26–32 years). Pit depth is increasing, but the shape is still a narrow to moderately wide U. The walls are thinner; however, the edges remain rounded. The rim is more irregular with no uniform scalloping pattern remaining. There is some decrease in the weight and firmness of the bone; however, the overall quality of the bone is still good (figure 9-3).



**Figure 9-3. Phase 4**



**Figure 9-4. Phase 6**



**Figure 9-5. Phase 8**

9-37. Phase 5 (33–42 years). There is little change in pit depth, but the shape in this phase is predominately a moderately wide U. Walls show further thinning and the edges are becoming sharp. Irregularity is increasing in the rim. Scalloping is completely gone and has been replaced with irregular bony projections. The condition of the bone is fairly good; however, there are some signs of deterioration with evidence of porosity and loss of density.

9-38. Phase 6 (43–55 years). The pit is noticeably deep with a wide U-shape. The walls are thin with sharp edges. The rim is irregular and exhibits some rather long bony projections that are frequently more pronounced at the superior and inferior borders. The bone is noticeably lighter in weight, thinner, and more porous, especially inside the pit (figure 9-4).

9-39. Phase 7 (54–64 years). The pit is deep with a wide to very wide U-shape. The walls are thin and fragile with sharp, irregular edges and bony projections. The bone is light in weight and brittle with significant deterioration in quality and obvious porosity.

9-40. Phase 8 (65 years and older). In this phase, the pit is very deep and widely U-shaped. In some cases, the floor of the pit is absent or filled with bony projections. The walls are extremely thin, fragile, and brittle with sharp, highly irregular edges and bony projections. The bone is very lightweight, thin, brittle, friable, and porous (figure 9-5).

9-41. Other degenerative changes (such as osteoarthritis, ossification of costal and thyroid cartilage, and the ossification of tendon and ligament insertions) are associated with advanced aging. These degenerative changes may be used as an indicator of general age in the absence of any other indicators. These degenerative changes could be used to suggest that the individual was more likely at one end of an age range than the other (for example, more likely at the older end than the younger end of the range). Physical activity, trauma, and some diseases can mimic the appearance of degenerative changes.

9-42. Two microscopic techniques that are used to determine age at death of skeletonized remains. Microscopic techniques typically provide reliable ages for adults. Tissue samples are taken and thin sections are prepared for viewing through a microscope on the cellular level. The normal remodeling of bone during adult life is the basis for one of the microscopic techniques used to determine adult age. Microscopic examinations of thin sections of cortical bone (bone in the long bone shafts) are used. As the



bone must be cut in half at the midshaft in order to obtain the appropriate cross section, the other microscopic aging technique requires thin sections of a tooth. Both techniques, however, require considerable training and expertise to prepare and interpret the required thin-section specimens. Both procedures are destructive to bone.

9-43. The normal remodeling of bone during adult life is the basis for one of the microscopic techniques used to determine adult age. Microscopic examinations of thin sections of cortical bone (bone in the long bone shafts) are used. As the bone must be cut in half at the midshaft in order to obtain the appropriate cross section. The other microscopic aging technique requires thin sections of a tooth. As with bone, this process is destructive to the tooth.

9-44. Throughout the life of an individual, degenerative age-related changes occur in the cancellous bone of the epiphyses. These changes have been documented in the proximal humerus and femur. The basic premise is that there is a significant correlation between increased age and decreased bone density. Radiographs are taken of the epiphyses and the observed changes are compared to published standards.

### Determination of Adult Sex

9-45. Determination of sex can be made for adult skeletal remains only. It is not possible to assign sex to the remains of children and adolescents as the characteristics do not manifest themselves until puberty. Determining sex from skeletal remains can be made through analysis of the skull and the postcranial skeleton. There are numerous postcranial elements that are analyzed to determine sex, but only the major ones will be considered here. Of all the elements, the pelvic bones (figure 9-6, figure 9-7, and figure 9-8) are considered the best elements to determine the sex of adult skeletal remains. They are preferred over the skull, which is a close second. Using the pelvic bones and the skull together, the forensic anthropologist can accurately assign sex to skeletal remains with 99 percent accuracy.

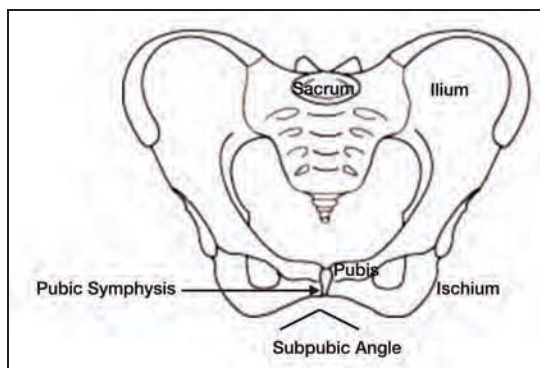


Figure 9-6. Pelvic Elements

## Chapter 9

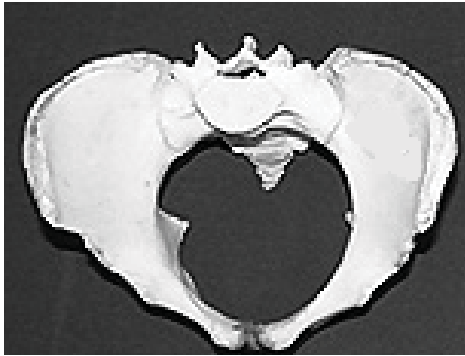

Figure 9-7. Female Pelvis

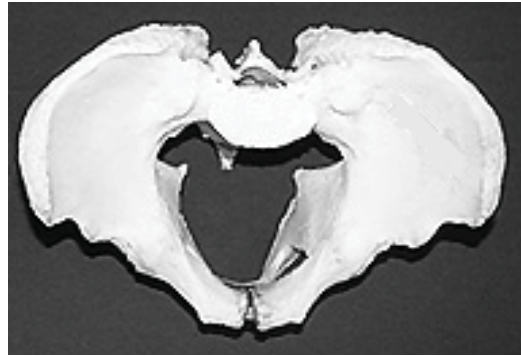


Figure 9-8. Male Pelvis

9-46. Variations in the general shape between the male and female pelvis are the result of the role of the female pelvis related to gestation and childbirth. In general, the male pelvis (figure 9-8) is rugged with marked muscle attachment sites. The female pelvis (figure 9-7) is gracile and smooth. Table 9-3 is an exhaustive list of traits; it highlights the more obvious sexual differences in the human pelvis. The first three traits are the most accurate, especially when used together (figure 9-9).

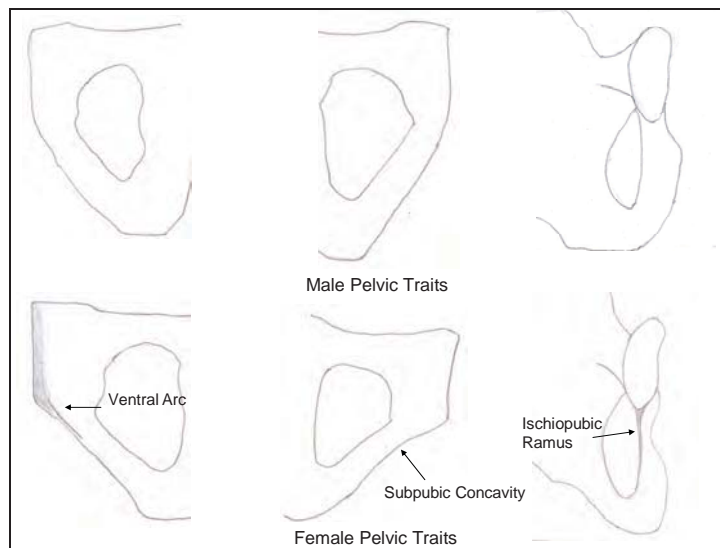


Figure 9-9. Male Pelvic Traits, Female Pelvic Traits

Table 9-3. Male and Female Pelvic Traits

<i>Trait</i>	<i>Female</i>	<i>Male</i>
Ventral arc—a slightly elevated ridge of bone across ventral surface of the pubic bone	Present	Absent
Subpubic concavity—observed slightly inferior to the pubic symphysis	Present	Absent
Ischiopubic ramus—the region immediately inferior to the pubic symphysis	Narrow	Broad
Subpubic angle	U-shaped, rounded	V-shaped, sharp angle

Table 9-3. Male and Female Pelvic Traits (continued)

<i>Trait</i>	<i>Female</i>	<i>Male</i>
Greater sciatic notch	Larger, wider, approaches 90 degrees	Small, acute angle
Pelvic Inlet	Circular, elliptical	Heart-shaped

9-47. Male cranial features are typically more pronounced than female features (figure 9-10). The male skull (figure 9-11) is generally larger than the female skull (figure 9-12), and the areas of muscle attachment are more robust (pronounced) and rugged. In addition to the general size and shape of the skull, there are some individual traits that the observer should focus on in the sex determination of the skull. Table 9-4 is not an exhaustive list of the traits; it highlights the more obvious sexual differences in the human skull.

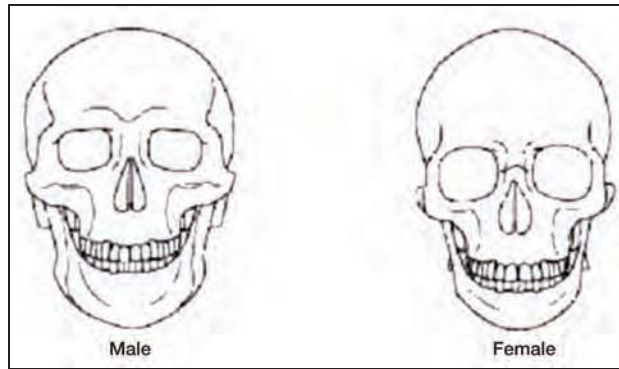


Figure 9-10. Basic Male and Female Cranial Morphology

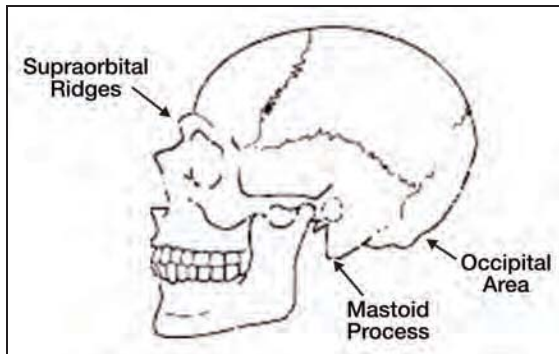


Figure 9-11. Male Cranial Morphology

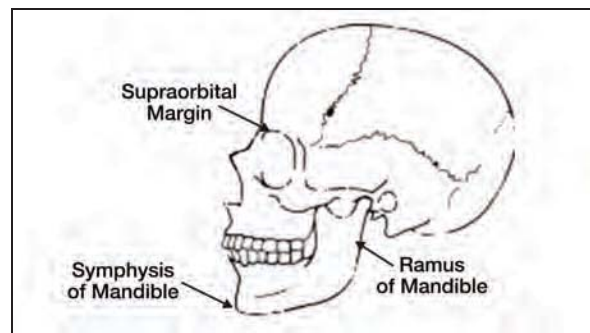


Figure 9-12. Female Cranial Morphology

Table 9-4. Basic Male and Female Cranial Morphology

<i>Trait</i>	<i>Male</i>	<i>Female</i>
Superorbital ridges	Prominent, medium to large	Small to medium
Mastoid process	Medium to large	Small to medium
Occipital area	Marked muscle lines and protuberances	Muscle lines not marked, no protuberance
Superorbital margin	Rounded	Sharp

## Chapter 9

Table 9-4. Basic Male and Female Cranial Morphology (continued)

<i>Trait</i>	<i>Male</i>	<i>Female</i>
Symphysis of mandible	Square, U-shaped	Rounded, V-shaped
Ramus of mandible	Broad, straight	Narrower, slanting
Forehead	Sloping, less rounded	Vertical, full (more rounded)

9-48. In addition to the pelvis, numerous postcranial elements are used to determine sex of skeletal remains. The clavicle, sternum, scapula, sacrum, calcaneus, humerus, and femur are examples of some postcranial bones that have been analyzed for sex-specific traits. In general, male skeletal elements are characterized by larger size and heavier construction. Frequently, the forensic anthropologist will use the maximum diameter of the head of the humerus and/or femur for determining sex. The maximum diameter of the head of the humerus and/or the femur (figure 9-13) is measured with sliding calipers and the results applied to known standards to determine sex (table 9-5).

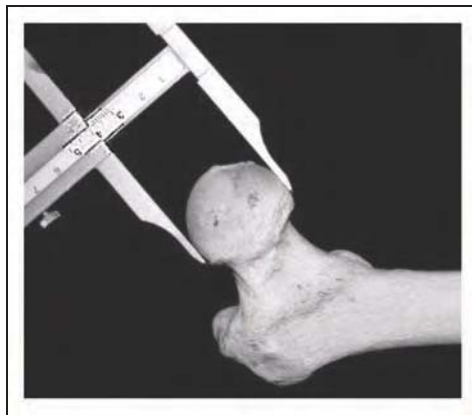


Figure 9-13. Measuring the Maximum Diameter of the Femur Head

Table 9-5. Sex Estimation Using the Humerus and Femur

<i>Maximum diameter in mm</i>	<i>Females</i>	<i>Possible Female</i>	<i>Sex indeterminate</i>	<i>Possible Male</i>	<i>Males</i>
Head of humerus	< 43	--	44 – 46	--	>47
Head of femur	< 42.5	42.5 – 43.5	43.5 – 46.5	46.5 – 47.5	>47.5

## DETERMINATION OF RACE

9-49. Determination of race (ancestry) is an important step in identifying individuals in forensic cases. There are no “pure races,” and thus racial classification imposes somewhat artificial boundaries. However, racial classification is a viable category for law enforcement agencies.

9-50. Forensic anthropologists are usually obligated to provide legal authorities with a determination of race for unidentified skeletal remains. To do so, they must accurately assign the skeletal remains to an ethnic/racial group to which they would most likely have been associated during life—the individual’s social identity. Racial assessment—in addition to age, sex, and stature assessments—narrows the field of potential missing persons who fit the biological profile of the skeletal remains.

9-51. Determining race from the skeleton is often difficult and usually depends upon a great deal of experience in examining skeletal remains. Racial assessment is complicated by several factors. It is a fact that the people of the world have more in common than they have differences. Racial traits are not very

marked; there is a broad overlap between human races. There are many individuals whose heritage derives from two or more geographic areas. Thus, for the forensic anthropologist, assessing racial identity from skeletal remains depends on the identification of degrees of traits that occur with higher frequencies in certain populations.

9-52. The skull (figure 9-14) is used almost exclusively to assess race. Postcranial elements are also used, but they are less reliable and will not be addressed here. Racial assessment from the skull can be made morphologically (observation) and/or metrically (measurement). Traditionally a three-race model has been used to describe broad cranial characteristics. The races defined are Mongoloid (Asiatics, Native Americans), Negroid (Africans, African-Americans), and Caucasoid (Europeans, west Asians, Mediterraneans, and Americans of similar ancestry). Table 9-6 provides an overview of general cranial morphological differences.

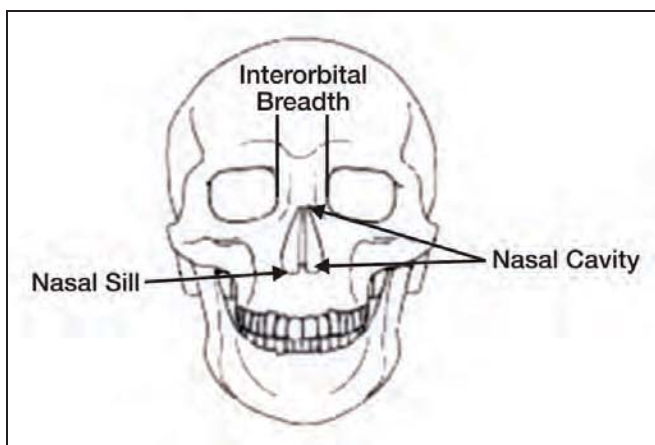


Figure 9-14. Cranial Landmarks

Table 9-6. Race Characteristics of the Skull

<i>Trait</i>	<i>Asian Ancestry</i>	<i>African Ancestry</i>	<i>European Ancestry</i>
Cranial length	Short	Long	Long
Cranial breadth	Broad	Narrow	Narrow
Cranial height	Medium to high	Low	Medium to high
Facial height	High	Low	Short to high
Facial breadth	Very wide	Narrow	Narrow to wide
Facial profile	Flat, rounded	Prognathic (projecting jaws)	Long, narrow
Orbits	Rounded	Rectangular	Angular/sloping
Interorbital breadth	Narrow	Wide	Intermediate
Nasal cavity	Narrow to medium	Wide	Narrow to medium
Nasal sill	Blurred	Guttered	Sharp ridge
Nasal bones	Narrow, low-bridged, short	Broad, flat, short	Narrow, high-bridged, long

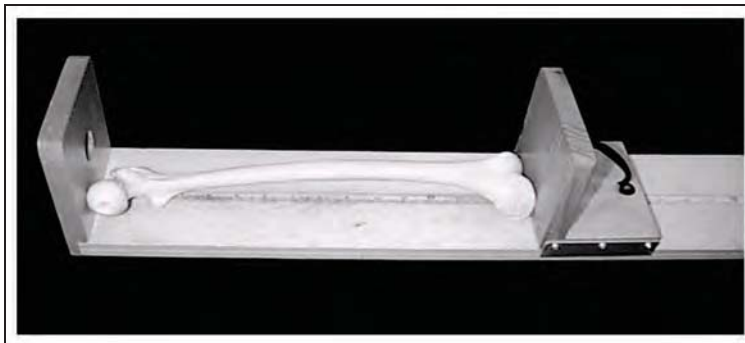
## ESTIMATION OF STATURE

9-53. The height of the human body correlates with long bone length. The techniques for estimating stature from skeletal remains are based on the fact that there is a constant relationship between the size of a given long bone and the stature of the individual to whom it belonged.

**Chapter 9**

9-54. The length of the leg bones are more highly correlated with stature than are the lengths of the arm bones. The femur is considered the most accurate single bone for stature estimation. As a general rule, the lengths of the arm bones should never be used to estimate stature when leg bones are available. When all the leg bones are missing or badly fractured, then arm bone measurements are used. The humerus is considered the most accurate of the arm bones.

9-55. The length of the long bone is measured on an osteometric board that assures an accurate measurement of overall length (maximum length) in centimeters (see figure 9-15). The measurement is “plugged” into the correct formulae to calculate an estimation of stature for the individual represented by the skeletal remains. Formulae are shown in table 9-7.



**Figure 9-15 Measuring the Femur on the Osteometric Board**

9-56. The formulae are race and sex specific. Thus, before measuring a bone to estimate stature, the race and sex of the skeletal remains must first be determined. Numerous studies for establishing living stature from skeletal remains have been conducted. Because the studies of Trotter and Gleser (1952, 1958) are considered the most reliable, their formulae and tables are reproduced here.

9-57. Recent research has found a discrepancy with the original Trotter and Gleser methods. This discrepancy can be avoided by using the femur over the tibia whenever possible. If it is necessary to use the tibia, then it should be measured without the malleolus.

**Table 9-7. Equations to Estimate Living Stature (cm) for Individuals Between 18 and 30 Years With Standard Errors From the Long Bones**

<b>White Males</b>	<b>Black Males</b>
2.89 Hum + 78.10 +/- 4.57	2.88 Hum + 75.48 +/- 4.23
3.79 Rad + 79.42 +/- 4.66	3.32 Rad + 85.43 +/- 4.57
3.76 Ulna + 75.55 +/- 4.72	3.20 Ulna + 82.77 +/- 4.74
2.32 Fem + 65.53 +/- 3.94	2.10 Fem + 72.22 +/- 3.91
2.42 Tib + 81.83 +/- 4.00	2.19 Tib + 85.36 +/- 3.96
2.60 Fib + 75.50 +/- 3.86	2.34 Fib + 80.07 +/- 4.02
<b>Mongoloid Males</b>	<b>Mexican Males</b>
2.68 Hum + 83.19 +/- 4.25	2.92 Hum + 73.94 +/- 4.24
3.54 Rad + 82.00 +/- 4.60	3.55 Rad + 80.71 +/- 4.04
3.48 Ulna + 77.45 +/- 4.66	3.56 Ulna + 74.56 +/- 4.05
2.15 Fem + 72.57 +/- 3.80	2.44 Fem + 58.67 +/- 2.99
2.39 Tib + 81.45 +/- 3.27	2.36 Tib + 80.62 +/- 3.73
2.40 Fib + 80.56 +/- 3.24	2.50 Fib + 75.44 +/- 3.52
<b>White Females</b>	<b>Black Females</b>
3.36 Hum + 57.97 +/- 4.45	3.08 Hum + 64.67 +/- 4.25

**Table 9-7. Equations to Estimate Living Stature (cm) for Individuals Between 18 and 30 Years With Standard Errors From the Long Bones (continued)**

<i>White Males</i>	<i>Black Males</i>
4.74 Rad + 54.93 +/- 4.24	2.75 Rad + 94.51 +/- 5.05
4.27 Ulna + 57.76 +/- 4.30	3.31 Ulna + 75.38 +/- 4.83
2.47 Fem + 54.10 +/- 3.72	2.28 Fem + 59.76 +/- 3.41
2.90 Tib + 61.53 +/- 3.66	2.45 Tib + 72.65 +/- 3.70
2.93 Fib + 59.61 +/- 3.57	2.49 Fib + 70.90 +/- 3.80

*Note.* To estimate stature of older individuals, subtract 0.06 centimeter (age in years -30)

9-58. For example, estimate the living stature from the femur of a white 20-year-old female, following these steps:

- Place the femur on the osteometric board. Measure the maximum length by placing one end against the immovable upright. Slide the moveable upright until it touches the other end. Read the maximum length. For this example, the maximum length measured 39.50 centimeters.
- Select the appropriate equation. The equation for the femur of white females is 2.47 Fem + 54.10 +/- 3.72.
- “Plug in” the maximum length of the femur, (39.5 centimeters) into the equation:  $2.47 \times 39.50 + 54.10 \pm 3.72$ .
- Perform the math.  $97.56 \text{ cm} + 54.10 = 151.66 \text{ cm}$  (59.71 inches).
  - $151.66 \text{ cm} \pm 3.72$
  - $151.66 + 3.72 = 155.38 \text{ cm}$  (61.17 inches)
  - $151.66 - 3.72 = 147.94 \text{ cm}$  (58.24 inches)

Therefore, the estimated living stature of the individual represented by the femur is between 147.94 centimeters and 155.38 centimeters, where 151.66 centimeters is the mean, 147.94 centimeters represents the low range, and 155.38 centimeters represents the high range of the estimate.

*Note.* To convert centimeters into inches, divide the number in centimeters by 2.54 (2.54 inches = 1 centimeter). Thus, 147.94 centimeters equal 58.24 inches, 151.66 centimeters equal 59.71 inches, and 155.38 centimeters equal 61.17 inches.

## INDIVIDUALIZATION

9-59. After age, sex, race, and stature have been determined from the remains, attention is directed to any individualizing characteristics that may exist. The forensic anthropologist will look for a variety of distinguishing features that will provide a personal identification and confirm a positive identification. Comparing postmortem radiographs to antemortem radiographs and/or the visual observation of distinct anomalies, pathologies, and surgical interventions can document individualizing characteristics.

*Note.* Comparing postmortem radiographs to antemortem radiographs is an excellent means of providing a positive identification for skeletal remains. If the postmortem radiographs of the skeletal remains are identical to radiographs of a possible victim taken during life, a positive identification can be established.

---

*Note.* If there is evidence on the skeletal remains for antemortem trauma, injury, or pathology, the element displaying these characteristics will be X-rayed. All of these conditions will confer unique markers upon the skeleton. If medical intervention was sought, then antemortem X-rays should exist for comparison to postmortem X-rays.

---

9-60. Many parts of the human skeleton demonstrate anatomical developmental variability that is applicable to the identification process. Foremost of these is the frontal sinuses, which are different in every person (even identical twins). The frontal sinuses develop (increase in size) until about 20 years of age when they become “fixed.” Radiographs of the skull are commonly taken for the diagnosis of head injuries, orthodontic purposes, and sinus problems. Frontal sinus patterns may also be observable on some dental radiographs. Military personnel frequently have skull radiographs on record for identification purposes. These films show the unique features of the sinuses, which can be compared to the same features on postmortem radiographs.

9-61. General patterns in bone outline, bone density, cancellous bone, and bony projections or nodules are internal bone structures that are unique to an individual. Radiographs will reveal the details of these structures and patterns. Virtually any bone, for which an antemortem radiograph exists, can be X-rayed postmortem for comparison of such individualizing characteristics.

9-62. Frequently surgical implant devices, such as pins, screws, plates, bolts, nails, pacemakers, and artificial joints are recovered with human remains. Visual observation of these devices may serve to provide a positive identification. Medical implant devices will usually have a distinctive appearance on X-rays. But many are also visually distinctive and traceable. Many surgical implant devices are stamped with a manufacturer’s trademark, serial number, and/or lot number. The manufacturer traces the device by these identifying markings to their distributor, physicians involved, and finally the patient. Thus, the identification labels on the devices provide a tracking system that may allow for the identification of the remains.

## **VIDEO SUPERIMPOSITION AND FACIAL RECONSTRUCTION**

9-63. Video superimposition and facial reconstruction are used as an aid in identifying skeletal remains. These methods may be employed when skeletal analysis—coupled with other evidence—suggests that remains are likely to be a certain individual but dental and medical records are not available. They are generally not considered positive methods of identification. Rather they are typically used to support a presumptive identification. While there have been some instances when these methods have been accepted in court as legal identification, they have traditionally been used as corroborating evidence.

9-64. Video superimposition is used in situations in which an investigation has suggested that a set of remains is likely to relate to a particular missing person. Video superimposition works by superimposing an antemortem photograph of a BTB individual over the skull of the remains in question. It is an attempt to supply a face to a skull.

9-65. Typical video superimposition employs two television cameras, an electronic mixing device, and a viewing screen to overlay an image of a photographed human face over an image of the skull. The skull is placed under one television camera and the photograph under the other. This allows the skull and the photograph to be compared on the viewing screen. The mixing device allows for a variety of views (fade in, fade out, swipe right, swipe left, swipe up, and swipe down) of the skull and photograph for direct bone to photograph comparison.

9-66. Computer-assisted video superimposition uses digitization and storage in the computer of images of the photograph and the skull. The skull is aligned using important anatomical landmarks found in the photograph. The digitized images are superimposed and the software allows for any mixing of bony and photographic images, including removal of soft tissue to view the skull structure below.

9-67. Successful superimposition depends on the quality of the submitted photographs, proper articulation of the cranium and mandible, and proper orientation of the cranium and mandible. Even a slight



misalignment of the bones prevents a successful match. A comparison is most successful when the antemortem photograph shows teeth.

9-68. A three-dimensional reconstruction of the facial features from the skull is frequently used when all other means of identification have failed. The three-dimensional facial reconstruction technique produces a clay image directly onto an unidentified skull in an attempt to reproduce the likeness of the living individual.

9-69. Numerous studies have provided data on average soft tissue thickness over 21 anatomical sites of the skull and jaws. These studies have determined proper tissue depth based on race, sex, and age. The skull is positioned on a workable stand. Wooden dowels, cut and marked with the appropriate tissue depths, are glued onto the skull. Modeling clay is then systematically applied to the skull following the skull's contours with attention to the applied tissue markers. The reconstruction process is a balance between scientific data and artistic skills to create a likeness of the face as it may have looked in life. Various measurements are made to determine the shape of the eyes, nose, and mouth. However, the exact shape of these features cannot be accurately predicted and some artistic license is taken.

9-70. Advances in graphical computing have lead to the development of computer systems for three-dimensional facial reconstruction. They use the traditional tissue depth data for coordinates and high-resolution images to transform laser-scanned, three-dimensional skull images into faces. Having the images available in a computer facilitates the final comparison of the reproduction with the underlying skull to make the reproduction as accurate as possible.

**This page intentionally left blank.**

## Appendix A

# Preparation of DD Form 890


A-1. DD Form 890 (Figure A-1) is used to record identifying media in the field or mortuary. Exactness of entries during processing operations is essential to the final positive identification of remains. All blocks must be completed. When the information cannot be provided, enter none, none found, or NA (not applicable).

A-2. Start in the top, right block and complete DD Form 890 as follows:

- **DATE** Block—Enter the date the form is completed.
- **NAME** Block—Enter the name of the decedent as BTB in the order indicated, Last Name, First Name, Middle Initial. If not known, enter unidentified.
- **GRADE and SERVICE NUMBER/SOCIAL SECURITY NUMBER** Block—Make entries as directed. If unknown, enter Unknown or Unk.
- **CIL CASE NUMBER** Block—Enter CIL case number, if applicable. If not applicable, enter NA.
- **NAME OF CEMETERY, EVACUATION NUMBER OR SEARCH AND RECOVERY NUMBER** Block—Make entries as directed.
- **PLOT, ROW, GRAVE** Blocks—Unless it is a cemetery, enter NA.
- **RECEIVED FROM** Block—Indicate if decedent was obtained through evacuation or search and recovery. If decedent was received from a cemetery, enter NA.
- **IMPRINT OF IDENTIFICATION TAG** Block—Enter imprint of the ID tag. If the ID tag is missing, enter missing. If the tag is too mutilated to imprint, enter mutilated followed by any legible information on the tag.
- **OFFICIAL IDENTIFICATION FOUND WITH REMAINS** Block—Enter all information qualifying as official identifying media. Some examples are as follows:
  - ID tags. (If found, indicate where they were found on the remains.)
  - Official identification card (DD Form 2—Armed Forces Identification Card or its replacement the CAC)
  - DD Form 1380 (U.S. Field Medical Card).
  - Motor vehicle operator's permit, marriage certificate,
  - Objects bearing name and/or service number or social security number.
- **ITEMS OF CLOTHING AND EQUIPMENT FOUND WITH REMAINS** Block—Enter the following to the extent available:
  - Size and type of clothing, distinctive insignia, and laundry markings.
  - Any visible markings discovered in footgear, headgear, web belt, and helmet liner, as detailed in AR 700-84. Do not remove clothing/equipment or turn clothing/equipment inside out. Record only that information that is readily visible.
  - Full description of insignia, decorations, medals, and campaign badges.
  - Complete description of military equipment, including identification numbers. Do not remove clothing/equipment or turn clothing/equipment inside out. Record only that information that is readily visible.
  - Data from decedent's military records, including name, grade, and service or social security number, along with other pertinent data.
- **YES–NO** Blocks—Mark an X in the appropriate block to indicate that a procedure was performed. Attach any relevant pictures or statements resulting from the procedure.

## Appendix A

- **PHYSICAL DESCRIPTION** Blocks—Enter information using data taken from skeletal or anatomical charts or obtained from direct observation.
- **NAME, GRADE, ORGANIZATION, and SIGNATURE** Blocks—Enter name, grade, and unit of the preparer of the form. The preparer signs the form in the signature block.

RECORD OF IDENTIFICATION PROCESSING <i>(Effects and Physical Data)</i>			DATE Today's Date		
LAST NAME - FIRST NAME - MIDDLE INITIAL <i>(Or unit known number)</i> BTB: SNUFFY, JOSEPH Q.		GRADE E3	SERVICE NO. SSAN 000-00-0000	CIL CASE NUMBER <i>(If applicable)</i> NA	
NAME OF CEMETERY, EVACUATION NUMBER, OR SEARCH AND RECOVERY NUMBER 35 08/AR 54QM/CP3 MSLI/SL#B258963			PLOT NA	ROW NA	GRAVE NA
RECEIVED FROM SFC PENDLETON, JEFFREY, B CO., 1-187TH INF.			IMPRINT OF IDENTIFICATION TAG		
OFFICIAL IDENTIFICATION FOUND WITH REMAINS <i>(Include personal effects aiding identification)</i> Military Driver's License, B Co., 187th INF, SFC Pendleton, Jeffrey Q. Pennsylvania Driver's License, Pendleton, Jeffrey Q., DL # 123456, expiration date 10/12/2011					
ITEMS OF CLOTHING AND EQUIPMENT FOUND WITH REMAINS <i>(Indicate type, color, size, markings, service, etc. If laundry marks are indistinct, follow procedures outlined in TM10-286)</i> 1 each, ACU Top (Blouse), size Medium Regular with name tape inscribed "Pendleton" 1 each, ACU Trousers size Medium Regular with name "Pendleton" on waist band 1 each, Cotton T shirt, tan in color, stencil with stencil "Pendleton" on front One pair, military issue-style socks One pair, Tan military-style desert-issue boots size 8R 1 each, White boxer undergarment, size 34 1 each, Belt, military-issue style, tan in color					
FINGERPRINTS TAKEN <input type="checkbox"/> YES <input checked="" type="checkbox"/> NO		X RAYS MADE <input type="checkbox"/> YES <input checked="" type="checkbox"/> NO		FLUOROSCOPE STATEMENT ATTACHED <input type="checkbox"/> YES <input checked="" type="checkbox"/> NO	
PHOTOGRAPHS TAKEN <input type="checkbox"/> YES <input checked="" type="checkbox"/> NO		ANTHROPOLOGICAL STATEMENT MADE <input type="checkbox"/> YES <input checked="" type="checkbox"/> NO		CHEMICAL STATEMENT ATTACHED <input type="checkbox"/> YES <input checked="" type="checkbox"/> NO	
PHYSICAL DESCRIPTION					
ESTIMATED HEIGHT 68"	MUSCULARITY MEDIUM	COLOR OF HAIR BLOND	RACE OR NATIVITY CAUCASOID		
TATTOOS, SCARS OR MARKS ON BODY Tattoo of phoenix on left forearm. Phoenix is predominately red in color, with yellow on the wing tips. Scar on right dorsal hand. Scar is approximately 3 inches in length and runs in a medial-lateral direction.					
EVIDENCE OF HEALED FRACTURES AND BONE MALFORMATIONS None observed.					
WOUNDS OR INJURIES Large abrasion affecting the entire right side of face. Multiple puncture wounds to left side of face.					
I HAVE PERSONALLY VIEWED THE REMAINS OF THIS DECEASED AND ALL RESULTING INFORMATION HAS BEEN RECORDED TO THE BEST OF MY KNOWLEDGE.					
NAME, GRADE, AND ORGANIZATION Glassman, Steven J., E7, 54th QM CO.				SIGNATURE	

DD FORM 890, JAN 58

PREVIOUS EDITION OF THIS FORM IS OBSOLETE.

Figure A-1. DD Form 890

## Appendix B

### Preparation of DA Form 4137

B-1. DA Form 4137 (Figure B-1 and Figure B-2) is initiated when evidence is collected/acquired. This form is a multipurpose form.

- It is a receipt for acquiring evidence.
- It is a record of the chain of custody of evidence and authority for final disposition.
- It cites the final disposition and/or witnessing of destruction of the evidence.

B-2. Each item of evidence that is acquired must be recorded on a DA Form 4137. Entries should be typed or printed legibly in ink. When evidence is received from a person, give the last copy to him as a receipt. When evidence is found, rather than received from a person, give the last copy to the responsible authority at the scene. The original and the first two copies go to the evidence custodian. This individual keeps the original and first copy for his records. The second copy is returned to the originator for inclusion in the case file.

B-3. Start in the top, right block and complete DD Form 4137 as follows:

- **ADMINISTRATIVE SECTION** Blocks—Enter administrative data as requested. Clearly state the location, reason, and time/date the evidence was obtained.
- **DESCRIPTION OF ARTICLES** Block—Do the following:
  - Describe each item of evidence, accurately and in detail.
  - Cite the model, serial number, condition, and any unusual marks or scratches.
  - Enter the quantity of an item that is hard to measure or subject to change, like glass fragments or crushed tablets, using terms like "Approximately 50," or "Undetermined," or "Unknown."
- **CHAIN OF CUSTODY** Blocks—This section provides information about the release and receipt of evidence. From initial acquisition of evidence to its final disposition, **every change** in custody must be recorded in this section.
  - **RELEASED BY** Column. The first entry under this column contains the signature, name, and grade or title of the person from whom the property was taken.

---

*Note.* If the person refuses or is unable to sign, enter his name on the form and write "Refused" or "Unable to sign" in the signature block.

*Note.* If the evidence was found at the scene or if the owner cannot be determined, write NA in the signature block.

---

- **RECEIVED BY** Column. This column contains the signature, name, grade or title of the person receiving the evidence.
- **PURPOSE OF CHAIN OF CUSTODY** Column. Under this column, the action that is transpiring in regard to the evidence is entered. For example, the evidence collector could write "transfer from scene to laboratory." The individual receiving the evidence at the laboratory could write "received at laboratory for analysis" or "received by evidence custodian."





**This page intentionally left blank.**



## Appendix C

# Evidence Collection and Packaging Guide

### GENERAL

C-1. Package all items of evidence separately. All packaging material must be clean and unused. Most evidence will be packaged in a primary (inner) and secondary (outer) container. When choosing the proper container, consider the common sense nature of the evidence, such as size, weight, and composition of the item. Generally, paper bags are the most useful. Minimize the interior movement of the evidence within the packaging. Seal the package with evidence tape. The evidence tape should cover the opening of the container completely. The collector will initial across the seal with a permanent marker. (See figure C-1). Mark the package with a description of the item of evidence; identification of the collector; and date, time, and location where collected. Practice safety precautions when collecting evidence. Wear rubber gloves, shoe covers, gowns, masks, and goggles as appropriate.



Figure C-1. Seal the Package With Evidence Tape

### PACKAGING MATERIALS

C-2. Basic packaging materials include the following:

- Paper bags.
- Plastic zip lock bags.
- Cardboard boxes.
- Firearm boxes.
- Knife boxes.
- Pill boxes.
- Envelopes of various sizes.
- Clean paper/note pad.
- Glass jars.
- Lined, metal paint cans.

**Appendix C**

---

- Evidence tape.
- Labels and markers.
- Sterile swabs and boxes.
- Large butcher paper.

C-3. Specialized materials may include—

- Blood collection kits.
- Gunshot residue kits.
- Rape kits.
- Postmortem fingerprint kits.

**BODY FLUIDS ON ITEMS**

C-4. If possible, body fluids should be allowed to air-dry. When collecting, air-drying, or packaging wet evidence, do not allow fluids or stains to touch another stained or unstained area. Place paper between layers of the item to avoid transfer or alteration of the fluid. When air-drying items stained with body fluids, place them on or over a piece of clean paper. The paper will collect any debris/evidence that falls from the material during drying. The paper will be collected and submitted with the item. Plastic bags should be used for packaging only when there are excessive fluids and the contamination of other items is a concern. Wet or moist body fluids should never be packaged in plastic for long periods of time as it promotes bacterial growth and thus evidence contamination. Paper packaging is preferred if saturation is not a problem.

**LIQUID BLOOD**

C-5. If the amount of wet blood is small, then it is collected with sterilized cotton swabs, allowed to air-dry, and the swab is inserted into a swab box. Do not use double-tipped swabs or Q-Tips. If the amount of wet blood is large, use a sterile pipette or syringe and transfer the blood to a vacutainer test tube.

**DRIED BLOOD**

C-6. Dampen a sterile cotton swab with one or two drops of distilled water. Carefully swab the bloodstain. Allow the entire swab to air-dry and then place in a swab box. If the dried blood is on a small movable object, then collect the entire object.

**DRUG EVIDENCE**

C-7. Pills and capsules should be packaged in rigid containers to prevent crushing or damaging evidence. Prescription bottles with intact labels should be submitted in the original container to preserve evidence with available information. Biological substances, such as marijuana, should be packaged in paper bags or wrapped in paper.

**FIREARMS**

C-8. Firearms should never be collected or packaged loaded. Unload firearms after proper documentation. If the firearm is a revolver, document the cylinder position. If the firearm is a semiautomatic pistol, document the condition of the slide mechanism, the number of live rounds in the magazine, and the presence of any chambered rounds. When collecting and packaging a firearm, consider the possibility of latent fingerprints and trace evidence. Do not stick anything into the barrel. The firearm may be picked up by textured grips without damaging latent fingerprints. If fingerprints are not a concern, then package the firearm in a paper bag. If fingerprints are a concern, package in a manner that the firearm does not come into contact with any surface of the packaging material. A cardboard box manufactured specifically for firearms should be used. Do not package firearms in plastic. Package live rounds removed from the firearm in separate containers.

## PROJECTILES AND SPENT CASINGS

C-9. Collect projectiles and spent casings with either rubber-tipped forceps or gloves. Place the projectile or casing in a pill box cushioned with tissue or a zip lock bag. Package each projectile and casing separately. Do not clean, mark, or score the projectile or casing. If fingerprints are not a concern, they may be packaged in plastic bags. If fingerprints are a concern, immobilize the casing and/or reduce contact with the packaging material.

## TOOLS

C-10. To preserve possible fingerprints, package the tool in a manner that immobilizes the item or reduces contact with the packaging material. Wrap the working end of the tool to protect microscopic characteristics and trace evidence.

## QUESTIONED DOCUMENTS

C-11. Questioned documents are any documents that bear questioned writing or impressions including, but not limited to, checks, demand notes, suicide notes, letters, credit cards, and bank withdrawal forms. Never mark, fold, staple, pin, or deface the questioned document in any manner. Handle the document carefully and minimally. Use rubber-tipped tweezers or gloves. A questioned document can be packaged in almost any kind of envelope or plastic bag as long as it fits without folding. Always label the evidence package before the questioned document is placed inside. If the document is packaged and the package is marked afterward, then indented writings may be imparted on the questioned document. If the questioned document is wet, allow it to air-dry. If the document is crumpled, do not straighten the document. Package it in a rigid container. If a document is torn, do not attempt to piece the document back together.

## HAIR AND FIBERS

C-12. Collect hairs and fibers with a tweezers and place in a clean piece of paper using the druggist's fold (figure C-2).

- Step 1. Start with a clean sheet of paper.
- Step 2. Crease the paper four times.
- Step 3. Fold the paper lengthwise into thirds—using the two crease lines formed from step 2.
- Step 4. Fold the bottom up.
- Step 5. Place the evidence inside the opening.
- Step 6. Fold the top over and tuck inside the bottom opening.

C-13. Place the paper into a secondary container, such as an envelope or zip lock bag.

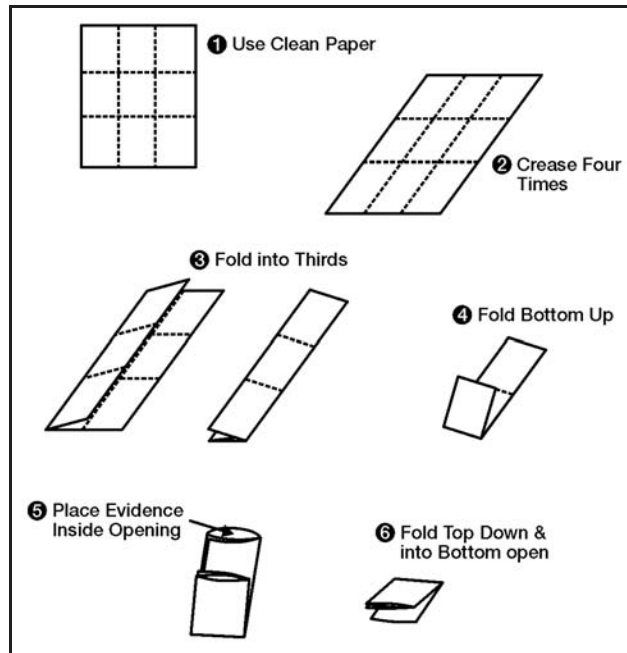
**Appendix C**

Figure C-2. Druggist's Fold

**GLASS**

C-14. Collect glass with consideration to fingerprints when appropriate. Protect each piece from chipping or breaking in transit. Wrap pieces of glass in paper or tissue paper and place in a rigid container.

**PAINT**

C-15. Because layers of paint are examined for sequence and number and relative layer thickness, collect intact paint chips. Do not just scrape the surface, crosscut down to the substrate. Collect an area about the size of a nickel. Place in a clean vial or pill box or druggist's fold of clean paper and place the paper in a paper or plastic envelope or pill box.

**SOIL**

C-16. Place in a druggist's fold of clean paper and place the paper into nonairtight containers to allow any moisture to evaporate.

**ACCELERANTS AND FLAMMABLE FLUIDS**

C-17. Both liquid and absorbed samples—such as clothing, bedding, or carpet—should be placed in an airtight container. Lined, unused metal paint cans are preferred. Glass jars can be used as a last resort. Do not fill cans more than  $\frac{3}{4}$  full.

**ENTOMOLOGICAL EVIDENCE**

C-18. Adult flying insects can be collected with a standard insect net. Crawling insects are collected from on, in, or under remains with a gloved hand. Both flying and crawling insects should be placed in a solution of 70 percent ethanol or isopropyl alcohol diluted 1:1 with water. Insects in soil should be scooped up with some soil and placed into zip lock plastic bags.

## Glossary

### SECTION I – ACRONYMS AND ABBREVIATIONS

<b>ABMDI</b>	American Board of Medicolegal Death Investigators
<b>AFDIL</b>	Armed Forces DNA Identification Laboratory
<b>AFIP</b>	Armed Forces Institute of Pathology
<b>AFMES</b>	Armed Forces Medical Examiner System
<b>AIDS</b>	acquired immune deficiency syndrome
<b>BIS-GMA</b>	bisphenol-A-glycidyl methacrylate
<b>BTB</b>	believed-to-be
<b>CAC</b>	common access card
<b>CAPMI</b>	computer assisted postmortem identification
<b>CAPMI4</b>	computer assisted postmortem identification version 4
<b>CHL</b>	crown-heel length
<b>CID</b>	Criminal Investigation Division
<b>CIL</b>	Criminal Identification Laboratory
<b>cm</b>	centimeter
<b>CMAOC</b>	United States Army Casualty and Memorial Affairs Operations Center
<b>CO</b>	carbon monoxide
<b>CONUS</b>	continental United States
<b>CRL</b>	crown-rump length
<b>DNA</b>	deoxyribonucleic acid
<b>DOS</b>	direct operating system
<b>FBI</b>	Federal Bureau of Investigation
<b>Fem</b>	femur
<b>Fib</b>	Fibula
<b>FM</b>	field manual
<b>Hum</b>	humerus
<b>IDPF</b>	individual deceased personnel file
<b>MDI</b>	medicolegal death investigation
<b>ml</b>	milliliter
<b>mm</b>	millimeter
<b>MOPP</b>	mission oriented protective posture
<b>MOS</b>	military occupational specialty
<b>mtDNA</b>	mitochondrial DNA
<b>NA</b>	not applicable

**Glossary**

---

<b>PCR</b>	polymerase chain reaction
<b>PH</b>	potential (of) hydrogen
<b>PMI</b>	postmortem interval
<b>Rad</b>	radius
<b>S</b>	symphysis
<b>STP</b>	Saf-T-Pak
<b>Tib</b>	tibia
<b>U.S.</b>	United States
<b>unk</b>	unknown

**SECTION II – TERMS****alveolar process**

The ridge of bone in the maxilla and mandible that contains the alveoli.

**alveolus (singular), alveoli (plural)**

A single tooth socket, the cavity in which the root of a tooth is held in the alveolar process.

**anatomical position**

All descriptions of the human body are based on the assumption that the person is standing erect with the hands at the sides and the face, feet, and palms directed forward. The long bones are not crossed. The various parts of the body are then described in relation to imaginary planes. Understanding these planes will facilitate learning terms related to the position of structures relative to each other.

**anatomist**

An individual who specializes or is skilled in anatomy.

**anatomy**

The study of the structure of the body and the relationship of its parts to each other. The term “anatomy” has a Greek origin that means "to cut up" or "to dissect."

**anterior (or ventral)**

Toward the front of the body. Reference point is the coronal plane.

**apex**

The terminal or pointed end of the tooth root.

**appendicular skeleton**

Includes the bones of the arms, legs, shoulder girdle, and pelvic girdle.

**articulate (verb)**

To unite by one or more joints.

**articulation (noun)**

The area where two or more bones or skeletal parts come in contact with one another, such as joints and sutures.

**axial skeleton**

Includes the bones of the head, vertebrae, ribs, and sternum.

**bifid**

Divided into two parts, such as a bifid spinous process or a bifid tooth root.

**boss**

A rounded eminence, usually used in reference to the shape of the frontal or parietal bones of the skull.

**calvarium**

The cranium without the face.

**cementum**

The bony tissue that covers the root of a tooth.

**condyle**

A rounded projection for articulation with another bone.

**coronal (or frontal)**

Anatomical plane that divides the body into anterior (front) and posterior (back) halves. The coronal plane is placed perpendicular to the sagittal plane.

**cranium**

The skull minus the mandible.

**crest**

A narrow, usually prominent ridge of bone.

**crown**

That part of the tooth covered by enamel (anatomical). It is the portion of the tooth that is visible in the mouth (clinical).

**cusp**

A conical or cone-shaped elevation on the occlusal surface of the premolars and molars and on the incisal edge of the canines.

**deciduous dentition**

The primary (baby) teeth. They are the first to form, erupt, and function. There are 20 deciduous teeth. They are shed and replaced by the permanent dentition.

**degenerative changes**

Changes which occur in the human skeleton after the skeleton has finished growth and development. These changes are basically ones of erosion and general deterioration and ossification of otherwise soft tissue.

**dentin (or dentine)**

The hard tissue that forms the main body of the tooth. It surrounds the pulp cavity and is covered by enamel in the anatomical crown. Wear of the occlusal surface of a tooth may expose dentin.

**dentition** All the teeth considered collectively in place in the maxilla and mandible.

**diaphysis**

The long straight section (shaft) of a long bone.

**distal**

Farthest from the axial skeleton or further away from the origin of a structure. A term usually used for the limb bones. For example, the distal humerus articulates with the (proximal) ulna and radius. The distal tooth surface is the surface farthest from the midline.

**dorsal**

The back side of the body, also known as posterior. The term “dorsal” also refers to the top of the foot and the back of the hand.

**Glossary**

---

**ectocranial**

The outer surface of the cranial vault.

**edentulous**

Without teeth. It may refer to the loss of all the maxillary and/or mandibular teeth. The alveolar process shows no sockets for the teeth as bone growth has totally “filled in” the sockets.

**eminence**

A bony projection that is usually not as prominent as a process.

**enamel**

The white mineralized tissue that covers the dentin of the anatomical crown of the tooth.

**endocranial**

The inner surface of the cranial vault.

**epiphyseal closure**

The fusion of the epiphysis with the diaphysis that occurs during adolescence.

**epiphysis (singular); epiphyses (plural)**

The end of a long bone that is originally separated from the diaphysis by a layer of cartilage but that later becomes united to the diaphysis through ossification.

**facial (or labial)**

The surface toward the lips (outside) in the anterior dentition and toward the cheeks in the posterior dentition. The terms “facial” and “labial” are used interchangeably. However, the term “facial” is used in this manual for consistency in charting dental remains.

**fontanelle**

A membranous space between the cranial bones (the “soft spot”) in fetal life and infancy. There are numerous fontanelles, including the anterior, posterior, mastoid, and sagittal fontanelle.

**foramen**

A round or oval hole, an opening. The foramen magnum is the large hole in the base of the skull through which the spinal cord passes.

**forensic anthropologist**

A specialist in the human skeletal system. He has advanced training in human anatomy and all aspects of the human skeleton. He combines his knowledge of human anatomy and the human skeleton to evaluate skeletonized or partially skeletonized remains in a legal context.

**fuse/fusion (or union)**

When the epiphyses of the bones unite (ossify) to their respective elements. This term is used interchangeably with the term epiphyseal closure.

**gross anatomy**

Deals with the naked-eye appearance of tissues and organs.

**head**

The large, rounded articular end of a long bone, such as in the head of the humerus and the head of the femur.

**horizontal (or transverse)**

Anatomical plane that divides the body into superior (upper) and inferior (lower) parts. Unlike the coronal and sagittal planes, this plane can pass through the body at any height.

**incisal**

The biting edge of the anterior teeth.

**inferior.**

Closer to the feet. Reference point is the horizontal plane.



**lateral**

Away from the midline. Reference point is the sagittal plane.

**lingual**

The surface of the tooth toward the tongue (inside).

**medial**

Toward the midline. Reference point is the sagittal plane.

**mesial**

The surface of the tooth nearest the midline of the dental arch.

**morphology**

The branch of biology which deals with structure and form. In osteology it refers to the shape and size of a bone or its general appearance.

**neck**

The constricted portion of bone between the head of a long bone and the shaft or the constricted part of the tooth at the junction of the crown and root.

**occlusal surface**

The biting edge/chewing surface of the posterior teeth.

**odontologist**

A dentist with a specialized interest in identification.

**odontology**

The study of the development, formation, and abnormalities of the teeth.

**ossification**

The formation of bone, the conversion of cartilage into bone (mineralization).

**osteology**

The detailed study and analysis of bones and the skeletal system.

**palmar**

The palm side of the hand, also known as volar.

**permanent dentition**

The adult teeth, which are 32 in number.

**plantar**

The sole of the foot.

**posterior (or dorsal)**

Toward the back of the body. Reference point is the coronal plane.

**process**

A bony projection or prominence.

**prone**

Lying on anterior surface of the body (stomach) with the face down.

**proximal**

Nearest the axial skeleton or closer to the origin of a structure, near the trunk or head. A term usually used for the limb bones. For example, the head of the humerus is the proximal end.

**pulp**

The soft tissue that constitutes the central cavity of the tooth. It includes nerves and blood vessels.

**Glossary**

---

**pulp cavity**

The entire central cavity of a tooth, which contains the pulp.

**root**

The part of the tooth that anchors the tooth in the alveolus. It is covered by cementum. The root is not visible in the mouth.

**sagittal (or median)**

Anatomical plane that separates the body into symmetrical right and left halves.

**sinus**

A cavity within a cranial bone.

**skull**

The entire bony framework of the head and mandible.

**spine**

A long, thin, sharp projection.

**stature**

The height of any animal while standing.

**superior**

Closer to the head. Reference point is the horizontal plane.

**supine**

Lying on the back with the face up.

**suture**

A specially serrated and interlocking joint where the adjacent bones of the skull meet.

**symphysis (singular); symphyses (plural)**

The line or junction formed by a cartilaginous articulation, the most common being between the two bones of the pelvis and the two halves of the mandible.

**trochanter**

A large roughened prominence for the attachment of muscles, specifically one of two processes (greater trochanter and lesser trochanter) found on the femur for the attachment of rotator muscles.

**tubercle**

A small, roughened, rounded eminence.

**tuberosity**

A roughened, rounded protuberance, such the deltoid tuberosity of the humerus.

## References

### SOURCES USED

These are the sources quoted or paraphrased in this publication.

#### ARMY REGULATIONS

AR 638-2, *Care and Disposition of Remains and Disposition of Personal Effects*, 22 December 2000.

AR 700-84, *Issue and Sale of Personal Clothing*, 18 November 2004.

#### DEPARTMENT OF THE ARMY FORMS AND PAMPHLETS

DA Form 2028, *Recommended Changes to Publications and Blank Forms*.

DA Form 2773, *Statement of Identification*.

DA Form 4137, *Evidence/Property Custody Document*.

DA Pam 638-2, *Procedures for the Care and Disposition of Remains and Disposition of Personal Effects*, 22 December 2000.

#### DEPARTMENT OF DEFENSE PUBLICATIONS AND FORMS

DD Form 1380, *U.S. Field Medical Card*.

DD Form 2, *Armed Forces of the United States Identification Card*.

DD Form 565, *Statement of Recognition of Deceased*.

DD Form 890, *Record of Identification Processing – Effects and Personal Data*.

DD Form 894, *Record of Identification Processing – Fingerprint Chart*.

DODD 5154.24, *Armed Forces Institute of Pathology (AFIP)*, 3 October 2001.

#### OTHER

SF 600, *Medical Record – Chronological Record of Medical Care*.

SF 603, *Health Record – Dental*.

Section 1471, Title 10-Armed Forces, United States Code (10 USC 1471), Subtitle A, Part II, Chapter 75, Subchapter 1.

*Crime Scene Investigation: A Guide for Law Enforcement*, National Institute of Justice (NIJ) Guide, U.S. Department of Justice, January 2000.

*Death Investigation: A Guide for the Scene Investigator*, NIJ Guide, U.S. Department of Justice, November 1999.

Brooks, S. and Suchey, J.M. *Skeletal Age Determination Based on the Os Pubis: A Comparison of the Acsadi-Nemeskeri and Suchey-Brooks Methods*. *Human Evolution*, Vol. 5, No. 3, pp. 227-238, 1990.

Di Maio, D.J., and Di Maio, V. *Forensic Pathology*, Second Edition, Boca Raton, Florida: CRC Press LLC, June 2001.

Di Maio, V., *Gunshot Wounds Practical Aspects of Firearms, Ballistics, and Forensic Techniques*, Second Edition; Boca Raton, Florida: CRC Press LLC, December 1998.

Dix, J., and Ernst, M.F. *Handbook for Death Scene Investigators*, Boca Raton, Florida: CRC Press LLC, March 1999.

## References

---

- Fisher, B.A., *Techniques of Crime Scene Investigation*, Sixth Edition, Boca Raton, Florida: CRC Press LLC, 2002.
- Fuller, J.L., and Denehy, G.E., et al. *Concise Dental Anatomy and Morphology*, Iowa City, IA, University of Iowa College of Dentistry, 2001.
- Gray, H., T.P. Pick, et al. *Anatomy, Descriptive and Surgical*, New York, Bounty Books: Distributed by Crown, 1987.
- Krogman, W.M., and Iscan, M.Y. *The Human Skeleton in Forensic Medicine*, Second Edition, Charles C. Thomas Publishers, Springfield, Illinois, 1986.
- Lee, L.C., Palmbach, T., and Miller, M.T., *Henry Lee's Crime Scene Handbook*, Academic Press, New York, July 2001.
- Snell, R. S., *Clinical Anatomy for Medical Students*, Little, Brown, and Company; Boston, Massachusetts, 1986.
- Trotter, M. and Gleser, G.C., *Estimation of Stature from Long Bones of American Whites and Negroes*, American Journal of Physical Anthropology, 19: pp. 213-227, 1952.
- Trotter, M. and Gleser, G.C., *A Re-Evaluation of Estimation Based on Measurements of Stature Taken During Life and of Long Bones After Death*, American Journal of Physical Anthropology, 16: pp. 79-123, 1958.

## DOCUMENTS NEEDED

These documents must be available to the intended users of this publication.

### JOINT PUBLICATION

- JP 4-06, *Joint Tactics, Techniques and Procedures for Mortuary Affairs in Joint Operations*, 28 August 1996.

### FIELD MANUALS

- FM 4-20.64, *Mortuary Affairs Operations*, 9 January 2007.
- FM 3-19.13 (FM 19-20), *Law Enforcement Investigations*, 10 January 2005.

## READINGS RECOMMENDED

These readings contain relevant supplemental information.

### NONMILITARY PUBLICATIONS

- Bass, W.M. *Human Osteology: A Laboratory and Field Manual*, Fourth Edition (Special Publication No. 2 of the Missouri Archaeological Society), Columbia, MO, November 1995.
- Clark, S.C., Ernst, M.F., Haglund, W.D., and Jentzen, J.M., *Medicolegal Death Investigation, A Systematic Training Program for the Professional Death Investigator*, Occupational Research and Assessment Inc., Big Rapids, Michigan, 1996.
- Friedman, R.B., Cornwell, K.A., and Lorton, L., *Dental Characteristics of a Large Military Population Useful for Identification*, American Journal of Forensic Sciences, 34(6): pp.1357-1364, 1989. (ISSN 0022-1198, published by ASTM International.)
- Gilbert, B.M., and McKern T.W., *A Method of Aging the Female Os Pubis*, American Journal of Physical Anthropology, 38: pp. 31-38, 1973.
- Katz, D., and Suchey, J.M., *Age Determination of the Male Os Pubis*, American Journal of Physical Anthropology, 69: pp. 427-435, 1986.

- Lovejoy, C.O., Meindl, R.S., Pryzbeck, T.R., and Mensforth, R.P. *Chronological Metamorphosis of the Auricular Surface of the Ilium: A New Method for the Determination of Adult Skeletal Age at Death*. American Journal of Physical Anthropology 68: pp. 15-28, 1985.
- McKern T.W., and Stewart T.D. *Skeletal Age Changes in Young American Males*. Headquarters Quartermaster Research and Development Command, Technical Report EP- 45, Quartermaster Research and Development Center, Environmental Protection Research Division, Natick MA, 1957.
- Scheuer, L. and Black, S. *Developmental Juvenile Osteology*, Academic Press, London, 2000.
- Scheuer, L. and Black, S. *Developmental Juvenile Osteology*, Academic Press, London, 2000. (ISBN 0-12-624000-0)
- Suchey, J. M., and Katz, D., *Skeletal Age Standards Derived from an Extensive Multiracial Sample of Modern Americans*. Paper presented at the Annual Meeting of the American Association of Physical Anthropologists, Albuquerque, New Mexico, 1986.
- Suchey, J. M., and Katz, D., *Applications of Pubic Age Determination in a Forensic Setting*. In Forensic Osteology Advances in the Identification of Human Remains, Second Edition, Reichs, K ed., pp. 204-214, 1998.
- Todd, T.W., *Age Changes in the Pubic Bone. I: The male white pubis*. American Journal of Physical Anthropology, 51: pp. 517-540, 1920.
- Todd, T.W., *Age Changes in the Pubic Bone. II: The Pubis of the Male Negro-White Hybrid, III: The Pubis of the White Female. IV: The Pubis of the Female Negro-White Hybrid*. American Journal of Physical Anthropology, 4: pp. 1-70, 1921.
- Wecht, C.H., *Use of Forensic Pathology in Defending Criminal Cases*. In Forensic Sciences Volume 1, Mathew Bender and Co., Inc., Albany, New York, pp. 25-3 through 25-104, 1988. (Library of Congress Catalog #81-69427, Times Mirror Books.)
- Wecht, C.H., *Autopsy Law and Procedures in Forensic Sciences*, Volume 1, Mathew Bender and Co., Inc., Albany, New York, pp. 26-3 through 26-86, 1988. (Library of Congress Catalog #81-69427.)

**This page intentionally left blank.**

## Index

- A**
- adult age
    - estimating, 9-6
    - other techniques, 9-10
    - pubic symphysis, 9-6
    - sternal rib ends, 9-9
  - adult human skeleton, 4-4
    - skull, 4-5
  - adult postcranial skeleton, 4-10
    - cervical vertebrae, 4-11
    - clavicle, 4-17
    - femur, 4-26
    - fibula, **4-29**
    - foot, **4-31**
    - hand, 4-22
    - humerus, 4-18
    - hyoid bone, 4-10
    - lumbar vertebrae, 4-14
    - patella, 4-27
    - pelvic girdle, 4-23
    - radius, 4-19
    - scapula, 4-16
    - sternum, 4-15
    - thoracic vertebrae, 4-13
    - tibia, **4-28**
    - ulna, 4-21
    - vertebral column, 4-11
  - adult sex
    - determination of, 9-11
  - age
    - estimation of adult, 9-6
    - estimation of fetal, 9-2
    - estimation of immature, 9-3
  - alveolar process, 4-1
  - American Board of Forensic Anthropology, 9-1
  - anatomical planes, 2-2
  - anatomical position, 2-1
  - anatomical terminology, 2-1
  - anatomy
    - definition of, 2-1
  - anterior teeth surface
    - distal, 5-3
    - facial, 5-3
    - lingual, 5-3
    - mesial, 5-3
  - appendicular skeleton, 2-3, 4-1
  - AR 638-2
    - disposing of personal effects, 1-3
  - articulation, 4-1
  - asphyxia, 3-21
    - carbon monoxide, 3-22
    - chemical, 3-21
    - cyanide, 3-22
    - strangulation, 3-21
    - suffocation, 3-21
  - axial skeleton, 2-3
- B**
- blunt force
    - categories, 3-6
    - injury, 3-5
    - injury to the skull, 3-11
  - blunt force categories
    - abrasions, 3-6
    - contusion, 3-7
    - fracture, 3-9
    - laceration, 3-8
  - burns, 3-1
    - first degree, 3-2
    - fourth degree, 3-3
    - pugilistic posture, 3-4
    - rules of nines, 3-4
    - second degree, 3-2
    - third degree, 3-3
- C**
- cause and manner of death, 6-1, 6-11, 6-12, 6-14, 7-1, 7-3, 7-8
  - chain of custody, 1-4
    - photographs, 1-4
  - charts
    - anatomical, 1-4
    - dental, 1-4
    - fingerprint, 1-4
    - footprint, 1-5
    - skeletal, 1-4
  - chemical asphyxia
    - carbon monoxide, 3-22
    - cyanide, 3-22
  - coroner system, 6-1
  - cranial features
    - male and female, 9-14
- D**
- DA Form 4137, 1-4, 6-4, B-1
  - DA Pamphlet 638-2
    - disposing of personal effects, 1-3
  - DD Form 890, 1-2, 1-3, 1-4, 1-5, 7-2, A-1
    - chain of custody, 1-4
  - death investigator
    - document and evaluate the death scene, 6-4
    - document the body, 6-10
    - establish and record decedent's profile, 6-14
    - maintain ethical and legal responsibilities, 6-16
  - death scene
    - and forensic anthropologists, 9-1
    - body assessment, 6-10
    - debriefing, 6-13
    - evidence on the body, 6-12
    - local law enforcement at, 6-1
    - medicolegal death investigator at, 6-1
    - photographic documentation, 6-10
    - photographs, 6-4
    - postmortem changes, 6-11
    - security of the remains, 6-13
    - sketches of, 6-5
  - death scene investigator, 6-12
    - documentation of the death scene, 6-5
    - location of injury or illness, 6-7
    - physical evidence and personal property, 6-8
    - proficiency of, 6-8
    - witnesses at the death scene, 6-9
  - death scene sketch
    - exploded view, 6-6
    - floor plan, 6-5
    - triangulation method, 6-6
  - deciduous dentition
    - types, 5-7
  - dental anomalies, 5-16, 5-17
    - abrasions, 5-16
    - dental fluorosis, 5-16
    - diastema, 5-16
    - enamel hypoplasia, 5-16
    - enamel pearls, 5-16
    - erosion, 5-16
    - fusion, 5-16
    - macrodontia, 5-17
    - microdontia, 5-17
    - migration, 5-17
    - rotation, 5-17
    - supernumerary, 5-17
    - tooth fracture, 5-16

**Index**

- dental calcification and eruption, 9-3
- dental cavities, 5-14
- dental chart, 1-3, 8-1, 8-4, 9-2  
contents, 8-1  
radiographs, 8-2
- dental conclusions  
exclusion, 8-5  
insufficient evidence, 8-5  
positive identification, 8-5  
possible identification, 8-5
- dental identification  
possible conclusions, 8-5
- dental restorations, 5-14  
direct restorative dental materials, 5-15  
indirect restorative dental materials, 5-15  
permanent restorative materials, 5-15  
temporary restorative materials, 5-14
- DNA  
definition of, 8-26  
harvesting, 8-28  
profiling, 8-27  
transporting, 8-29  
uses, 8-27
- DNA profiling  
mitochondrial DNA, 8-28  
nuclear DNA, 8-27
- drowning, 3-22  
autopsy, 3-22  
rigor mortis, 3-22
- E**
- epiphyseal union, 9-4
- evidence  
dried blood, C-2  
packaging, 6-9
- evidence packaging, C-1
- examination  
of clothing and equipment, 1-2  
of military equipment, 1-2  
of official identification, 1-2
- F**
- fetal and immature skeleton, **4-32**
- fingerprinting classification  
arch pattern, 8-7  
loop pattern, 8-8  
whorl pattern, 8-9
- fingerprinting procedures, 8-11  
advanced decomposition, 8-20  
desiccation, 8-22
- early decomposition, 8-19
- Fingerprint Identification Kit, 8-12
- hands clenched, 8-16
- maceration, 8-24
- newly dead, 8-12
- photographic techniques, 8-25
- powder and label method, 8-11
- wrinkled fingertips, 8-19
- foot  
metatarsals, **4-32**  
phalanges, **4-32**  
tarsal, **4-32**
- footprinting, 8-26
- footprints  
for pilots, 1-5
- forensic anthropologist, 4-3, 6-15, 9-1, 9-6, 9-10, 9-11, 9-15, 9-19, 4  
focus of, 9-1
- forensic odontologist, 8-4  
possible conclusions of, 8-5
- forensic odontology, 5-2, 8-1, 8-4
- fracture  
angulation, 3-10  
circular, 3-13  
comminuted, 3-12  
compound, 3-9  
compression, 3-11  
crush, 3-9  
definition of, 3-9  
depression, 3-12  
diastatic, 3-13  
direct, 3-9  
greenstick, 3-9  
indirect, 3-10  
linear, 3-13  
penetrating, 3-10  
rotational, 3-11  
simple, 3-9  
stellate, 3-13  
tapping, 3-9  
tension, 3-10
- G**
- gunshot wound  
contact, 3-16  
distant, 3-18  
entrance and exit, 3-19  
intermediate, 3-18  
near contact, 3-17
- H**
- human dentition, 5-1  
alveolar process, 5-1  
apex, 5-1  
cementum, 5-1
- crown, 5-1  
cusp, 5-1  
deciduous dentition, 5-1  
dentin, 5-2  
dentition, 5-2  
edentulous, 5-2  
enamel, 5-2  
forensic odontologist, 5-2  
neck, 5-2  
odontology, 5-2  
permanent dentition, 5-2  
pulp, 5-2  
pulp cavity, 5-2  
root, 5-2  
standardized terminology, 5-1
- human osteology, 9-1
- human skeletal system  
standardized terminology, 4-1
- I**
- identification  
positive, 6-16  
presumptive, 6-15  
unidentified, 6-15
- identifying human remains, 8-1  
dental, 8-1  
DNA, 8-26  
fingerprinting, 8-5
- identifying remains  
policies for, 1-1
- immature age  
dental calcification and eruption, 9-3  
epiphyseal union, 9-4  
estimating, 9-3  
long bone diaphyses, 9-5  
ossification centers, 9-4
- indirect fractures  
angulation, 3-10  
rotational, 3-11  
tension, 3-10
- injury definition, 3-1
- interviews  
avoid technical terms in, 6-10  
data to collect at, 6-9  
with witnesses, 6-9
- J**
- John Doe, 6-15
- L**
- laboratory techniques  
skeletal remains, 9-2
- Locard's Principle of Exchange, 6-8
- long bone diaphyses, 9-5



- M**
- major internal organs, 2-4
    - appendix, 2-16
    - brain, 2-4
    - esophagus, 2-12
    - gallbladder, 2-8
    - heart, 2-7
    - kidneys, 2-11
    - large intestine, 2-15
    - liver, 2-8
    - lungs, 2-6
    - pancreas, 2-10
    - small intestine, 2-14
    - spleen, 2-11
    - stomach, 2-13
    - urinary bladder, 2-12
  - media
    - collective, 1-3
    - inconclusive, 1-3
    - single-item, 1-3
  - medical examiner system, 6-1
  - medicolegal death investigator, 6-1
    - at death scene, 6-2
    - role of, 6-2
- O**
- odontological and anatomical terminology, 5-1
  - ossification, 4-3
  - ossification centers, 9-4
  - osteological terminology, 4-1
- P**
- packaging evidence, 6-9
    - accelerants and flammable fluids, C-4
    - body fluids, C-2
    - drugs, C-2
    - entomological evidence, C-4
    - firearms, C-2
    - glass, C-4
    - hair and fibers, C-3
    - liquid blood, C-2
    - paint, C-4
    - projectiles and spent casings, C-3
    - questioned documents, C-3
    - soil, C-4
    - tools, C-3
  - packaging materials, C-1
    - basic, C-1
    - specialized, C-2
  - pelvic girdle
    - coccyx, 4-23
    - os coxae, 4-23
    - sacrum, 4-23
  - pelvis
    - male and female, 9-12
  - permanent dentition
    - mandibular canines and cuspids, 5-9
    - mandibular molars, 5-12
    - maxillary canines and cuspids, 5-9
    - maxillary incisors, 5-7
    - maxillary molars, 5-12
  - personal effects
    - AR 638-2, 1-3
    - DA Pamphlet 638-2, 1-3
    - disposing of, 1-3
  - physical evidence, 6-3, 6-5, 6-7, 6-8, 6-10, 6-12, 6-13, 7-1, 7-2
  - postdeath investigation
    - decedent's identification, 6-15
    - decedent's medical history, 6-14
    - decedent's mental health history, 6-14
    - decedent's social history, 6-14
    - discovery history, 6-14
    - terminal episode information, 6-14
  - posterior teeth surface
    - distal, 5-4
    - facial, 5-4
    - lingual, 5-4
    - mesial, 5-4
  - prosthetic appliances, 5-15
    - dental bridge, 5-16
    - dental implants, 5-16
    - denture, 5-15
  - pugilistic posture, 3-4
- R**
- race
    - determination of, 9-16
    - using the skull for, 9-16
  - radiograph, 6-15, 6-16, 8-2
    - bitewing, 8-3
    - panoramic, 8-3
    - periapical, 8-2
    - skeletal elements, 9-2
  - records
    - maintaining, 1-2
  - rules of nines, 3-4
- S**
- Saf-T-Pak System, 8-29
  - scene debriefing, 6-13
  - sharp force injury, 3-13
  - skeletal age
    - estimating adult age, 9-6
    - estimating fetal age, 9-2
    - estimating immature age, 9-3
  - skeletal remains
    - basic laboratory techniques, 9-2
    - determining adult sex, 9-11
    - determining race, 9-16
    - estimating skeletal age, 9-2
    - estimating stature, 9-17
    - facial reconstruction, 9-20
    - individualization, 9-19
    - video superimposition, 9-20
  - skeleton. *See* adult human skeleton
  - skull
    - ethmoid bone, 4-9
    - frontal bone, 4-6
    - inferior nasal conchae bone, 4-10
    - lacrima bone, 4-9
    - mandible bone, 4-10
    - maxillae, 4-9
    - nasal bone, 4-9
    - occipital bone, 4-8
    - palatine bone, 4-9
    - parietal bone, 4-8
    - sphenoid bone, 4-10
    - temporal bone, 4-8
    - vomer bone, 4-10
    - zygomatic bone, 4-10
  - stature
    - estimation of, 9-17
    - leg long bone, 9-17
  - sternal rib ends
    - phases of, 9-9
  - supporting documents
    - most frequently used, 1-5
- T**
- teeth classification, 5-4
    - deciduous dentition, 5-4
    - permanent dentition, 5-5
  - terms of direction, 2-3
  - tooth surface, 5-3
    - anterior teeth, 5-3
    - posterior, 5-4
- U**
- U.S. Army Human Resources Command, 1-1
  - universal numbering system, 5-6
- W**
- wound
    - definition of, 3-1
    - formula, 3-6
  - wounds

**Index**

---

chop, 3-15  
gunshot, 3-16  
hesitation marks, 3-15

incised, 3-14  
stab, 3-14

wounds and injuries, 3-1

**ATTP 4-46.1 (FM 4-20.65)**  
**20 September 2011**

By Order of the Secretary of the Army:

**RAYMOND T. ODIERNO**  
*General, United States Army*  
*Chief of Staff*

Official:



**JOYCE E. MORROW**  
*Administrative Assistant to the*  
*Secretary of the Army*  
1107705

**DISTRIBUTION:**

*Active Army, Army National Guard, and United States Army Reserve:* Not to be distributed;  
electronic media only.

